

REFERENCES

- Hurwitz S. Herpes zoster. In: Clinical pediatric dermatology. Philadelphia, PA: WB Saunders 1993: 324–327.
- Baba K, Yabuuchi H, Takahashi M, Ogra PL. Increased incidence of herpes zoster in normal children infected with varicella zoster virus during infancy: Community-based follow-up study. *J Pediatr* 1986; 108: 372–377.
- Smith CG, Glaser DA. Herpes zoster in childhood; case report and review of the literature. *Pediatr Dermatol* 1996; 13: 226–229.
- Terada K, Kawano S, Yoshihiro K, Morita T. Varicella-zoster virus (VZV) reactivation is related to the low response of VZV-specific immunity after chickenpox in infancy. *J Infect Dis* 1994; 169: 650–652.
- Rothe MJ, Feder HM Jr, Grant-Kels JM. Oral acyclovir therapy for varicella and zoster infections in pediatric and pregnant patients. A brief review. *Pediatr Dermatol* 1991; 8: 236–242.
- Kakourou T, Theodoridou M, Mostrou G, Syriopoulou V, Papadogeorgaki H, Constantopoulos A. Herpes zoster in children. *J Am Acad Dermatol* 1998; 39: 207–210.

Accepted March 16, 2001

Claudine Lagarde, Astrid E. Steen, Thomas Bieber and Kay H. Steen*
Klinik und Poliklinik für Dermatologie, University of Bonn, Sigmund-Freud-Str. 25, D-53105 Bonn, Germany

*Address for Correspondence

Subcutaneous Metastasis Following Percutaneous Ethanol Injection Therapy for Hepatocellular Carcinoma

Sir,

Percutaneous ethanol injection therapy (PEIT) was first reported by Sugiura et al. in 1983 (1) and has been widely used for the treatment of hepatocellular carcinomas (HCC) (2, 3). Recently, PEIT has also been performed in the treatment of other tumors (4–6). Histopathologic examinations of tumors after therapy have revealed that PEIT can completely destroy the tumor in most cases (7).

Minor complications of PEIT, such as pain, fever and transient alcohol intoxication, have been reported (2, 3). However, a few reports have described of subcutaneous or pleural needle track seedings of tumor cells after PEIT (8–10). Here we describe two cases of metastatic subcutaneous tumors along the needle track for PEIT.

CASE REPORTS

The characteristics of the two patients are summarized in Table I. Briefly, the first patient, a 72-year-old female, had undergone two sessions of PEIT for three HCCs measuring < 20 mm in diameter, but a subcutaneous nodule was noticed 5 months after performance of PEIT in the epigastric region (Fig. 1a). The tumor, which seemed to develop as a result of needle track seeding, was resected. The pathological findings of the tumor revealed a non-capsuled solid lesion in the lower dermis through fatty tissue, and the lesion consisted of mainly α -fetoprotein (AFP)-positive, moderately differentiated HCC by immunohistochemical examination (Figs. 1b, c).

The second patient, a 69-year-old male, had undergone 10 sessions of PEIT for one HCC measuring 18 × 20 mm in diameter. He noticed a subcutaneous nodule in the epigastric region 2 months after under-

going PEIT. The tumor was resected. The pathological findings revealed a non-capsuled solid lesion in the lower dermis and fatty tissue consisting of moderately differentiated HCC (not shown).

DISCUSSION

The first case of needle track seeding following PEIT for the treatment of HCC was reported by Saito et al. (11) in 1989, in Japan. Since then, there have only been 32 cases, including ours, reported in the literature. In Japan, where PEIT was initially started, 17 cases have been reported. Of note, 28 cases (87.5%) were reported in the past 5 years (1995–1999) after PEIT became a more common procedure.

The clinical features of HCC seeding have been described as solid tumors in the abdominal wall (8, 10), pleural lesion (9), peritoneal lesion (12), intercostal muscle (13), or subcutaneous tissue (10, 11, 13). The incidence of HCC seeding in the subcutaneous tissue after a fine-needle biopsy is below 0.005% (14). Di Stasi et al. (15) reported that tumoral seeding occurred following PEIT in 0.66% of the patients. Saito et al. (11) described the tumor as a black or brown subcutaneous mass protruding from the liver. The interval for the emergence of the tumor following PEIT ranges from 2 months to 4 years (mean 16 months). Our patients developed brown-colored subcutaneous nodules in the epigastric region. The mechanism of needle track seeding is considered to be complex, and several causes have been discussed. The diameter and type of needle, the number of needle passes, extent of tumor aggressiveness, and the immune status of the patient are all considered (10). However, according to the literature, patients developing seeding show no significant clinical differences from the other non-seeding patients. Many reports emphasize the correct therapeutic application and good technique of PEIT. Similarly, in our two patients, PEIT was carried out correctly by doctors experienced in PEIT. Therefore, needle track seeding can occur indiscriminately and accidentally, although the probability seems small.

The prognosis for needle track seeding is usually not bad, which is the same as that for the other non-seeding patients. The systemic condition of the patient is most important. The

Table I. Clinical features of two patients with subcutaneous nodules after performing percutaneous ethanol injection therapy (PEIT)

Age/ gender	HCV	HBs	Child	AFP	PEIT	Interval (months)
72/F	+	–	A	29	Twice	5
69/M	+	–	A	50	10 times	2

HCV = hepatitis C virus; HBs = hepatitis B virus; Child = the stage of liver cirrhosis (A = good, B = moderate, C = poor); AFP: α -fetoprotein.

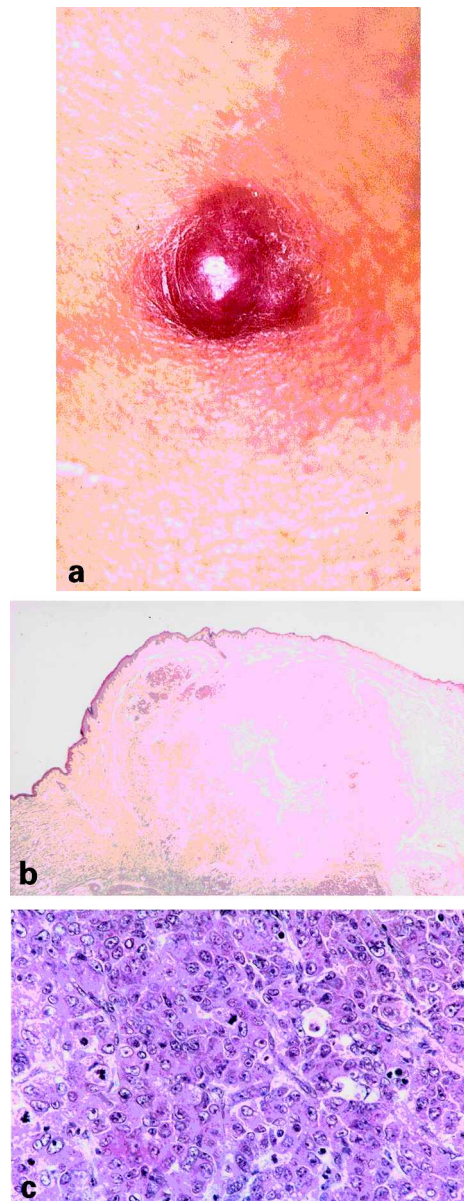


Fig. 1. Clinical and histopathological appearance of the skin tumor in the epigastric region (the first case). (a) A brownish, small and solid nodule in the epigastric area and (b) an excisional biopsy specimen showing a solitary hepatocellular nodule in the subcutaneous tissue (hematoxylin and eosin (HE); original magnification, $\times 10$). (c) α -Fetoprotein staining showing a well-differentiated hepatocellular carcinoma (original magnification, $\times 400$).

implanted tumors are mostly well or moderately differentiated and rarely invade. Thus, resection of the metastatic tumor will be very effective and will also help to distinguish between needle track seeding and a hematoma.

In summary, when subcutaneous tumors adjacent to the place of the PEIT are found, needle track seeding should be taken into consideration, and an excisional biopsy of the tumor is desirable for its diagnosis and therapy.

REFERENCES

1. Sugiura N, Takara K, Ohto M, Okuda K, Hirooka N. Percutaneous intratumoral injection of ethanol under ultrasound imaging for treatment of small hepatocellular carcinoma (Japanese). *Acta Hepatol Jpn* 1983; 24: 920.
2. Livraghi T, Festi D, Monti F, Salmi A, Vettori C. US-guided percutaneous alcohol injection of small hepatic and abdominal tumors. *Radiology* 1986; 161: 309–312.
3. Shiina S, Yasuda H, Muto H, Tagawa K, Unuma T, Ibukuro K, et al. Percutaneous ethanol injection in the treatment of liver neoplasms. *Am J Roentgenol* 1987; 149: 949–952.
4. Fujisawa T, Hongo H, Yamaguchi Y, Shiba M, Kadoyama C, Kawano Y, et al. Intratumoral ethanol injection for malignant tracheobronchial lesions: a new broncho-fiberscopic procedure. *Endoscopy* 1986; 18: 188–191.
5. Livraghi T, Paracchi A, Ferrari C, Reschini E, Macchi RM, Bonifacino A. Treatment of autonomous thyroid nodules with percutaneous ethanol injection: preliminary results. *Radiology* 1990; 175: 827–829.
6. Takenaka H, Kishimoto S, Shibagaki R, Nagata M, Noda Y, Yasuno H. Recurrent malignant proliferating trichilemmal tumour: local management with ethanol injection. *Br J Dermatol* 1998; 139: 726–729.
7. Shiina S, Tagawa K, Unuma T, Takanashi R, Yoshiura K, Komatsu Y, et al. Percutaneous ethanol injection therapy for hepatocellular carcinoma: a histopathologic study. *Cancer* 1991; 68: 1524–1530.
8. Cedrone A, Rapaccini GL, Pompili M, Grattagliano A, Aliotta A, Trombino C. Neoplastic seeding complicating percutaneous ethanol injection for treatment of hepatocellular carcinoma. *Radiology* 1992; 183: 787–788.
9. Zerbey AL, Mueller PR, Dawson SL, Hoover HC Jr. Pleural seeding from hepatocellular carcinoma: a complication of percutaneous alcohol ablation. *Radiology* 1994; 193: 81–82.
10. Shimada M, Maeda T, Saitoh A, Morotomi I, Kano T. Needle track seeding after percutaneous ethanol injection therapy for small hepatocellular carcinoma. *J Surg Oncol* 1995; 58: 278–281.
11. Saito I, Yamamoto S, Ideguchi S, Takatori K, Wada A, Yamamoto R, et al. A case of metastatic liver cell carcinoma in the abdominal wall due to direct skin invasion from protruding liver tumor (Japanese). *Jpn J Cancer Clin* 1989; 35: 1681–1685.
12. Kurl S, Farin P, Rytkonen S, Soimakallio S. Intraperitoneal seeding from hepatocellular carcinoma following percutaneous ethanol ablation therapy. *Abdom Imaging* 1997; 22: 261–263.
13. Sammak B, Yousef B, Abd El Bagi M, Al Karawi M, Mohamed A, Gali M, et al. Needle track seeding following percutaneous ethanol injection for treatment of hepatocellular carcinoma. *Hepatogastroenterology* 1998; 45: 1097–1099.
14. Fornari F, Civardi G, Cavanna L, Di Stasi M, Rossi S, Sbolli G. Complications of ultrasonically guided fine-needle abdominal biopsy: results of a multicenter Italian study and review of the literature. *Scand J Gastroenterol* 1989; 24: 949–955.
15. Di Stasi M, Buscarini L, Livraghi T, Giorgio A, Salmi A, De Sio I, et al. Percutaneous ethanol injection in the treatment of hepatocellular carcinoma. *Scand J Gastroenterol* 1997; 32: 1168–1173.

Accepted March 19, 2001.

Shoichiro Yano, Koichiro Nakamura, Kenichi Yamane, Takashi Kakinuma, Akihiko Asahina and Kunihiko Tamaki
Department of Dermatology, Faculty of Medicine, University of Tokyo, 7-3-1 Hongo, Bunkyo-ku, Tokyo 113-0033, Japan.
E-mail: yano-der@h.u-tokyo.ac.jp