

Subungual Myxoid Neurofibroma on the Thumb*

Sir,

The clinical presentation of neurofibroma of the nail unit is protean prior to destruction of the nail plate. We report on an unusual case with pronounced overcurvature associated with parallel lateral edges.

CASE REPORT

This 60-year-old woman sought advice for an unsightly deformity of the left thumb of more than 6 years' duration. The nail plate adhered tightly to the subungual tissue. There was marked transverse overcurvature, less pronounced longitudinal curvature (Fig. 1) and the lateral edges were parallel. The distal border of the lunula reached almost half of the length of the nail plate and was dusky red in its proximal two-thirds.

The patient did not experience pain and the distal phalanx was insensitive to pressure. The X-ray performed some weeks previously was not available but the patient said that it was "normal". The clinical differential diagnosis of this obvious subungual tumour included lipoma, fibroma, neurofibroma and giant cell tumour.

Under local anaesthesia the nail plate was avulsed, showing a bulge in the proximal portion of the visible subungual tissue. After a careful transverse incision performed in the middle of the length of the lunula, a smooth yellow tumour, rather firm in consistency, was seen (Fig. 2). It was removed by delicate dissection. The use of resorbable sutures completed the operation. The follow-up was uneventful.

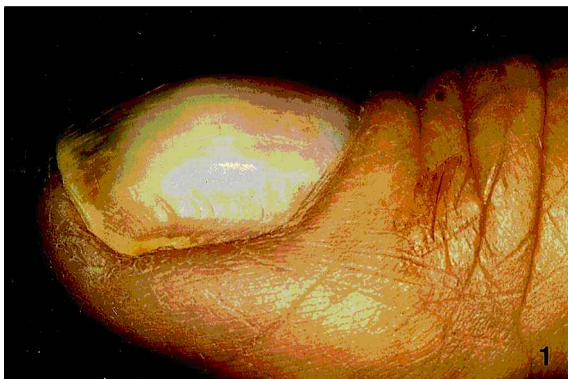

Fig. 1. Lateral view of the thumb nail.

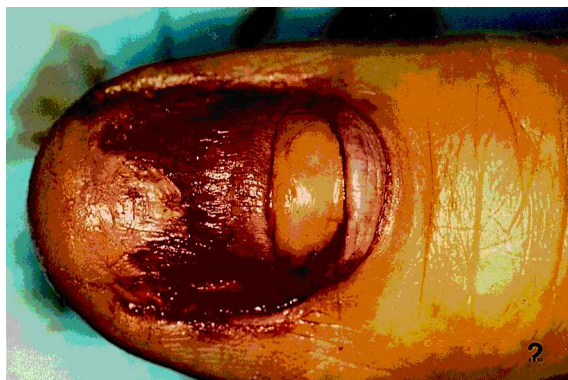

Fig. 2. Lunula transverse incision giving rise to a yellow tumour.

*This case was presented as a poster (263–264) at the American Academy of Dermatology, March 2–7, 2001.

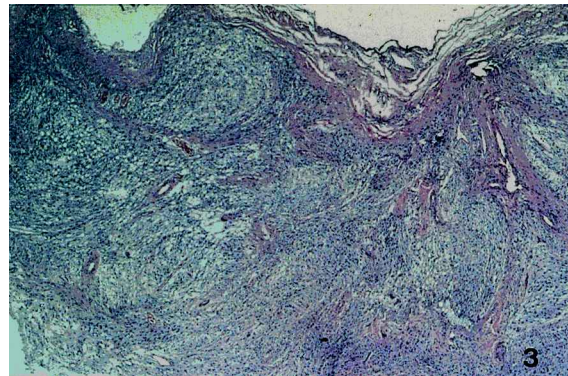


Fig. 3. Myxoid neurofibroma with coalescent nests of tumour cells (H&E \times 50).

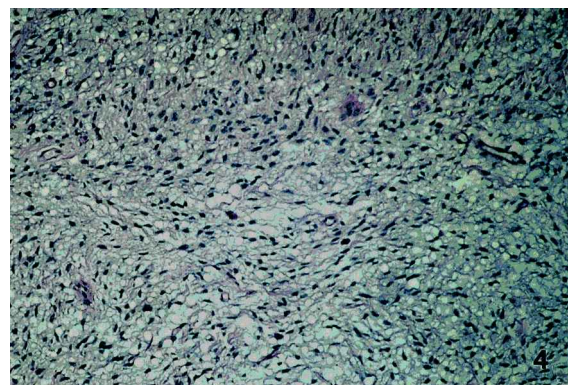


Fig. 4. Uniform cells in a myxoid stroma (H&E \times 200).

Histopathology showed a relatively well-circumscribed cellular tumour with a myxoid stroma (Fig. 3). The cells had uniform, small, oval to slightly bent fusiform, dense nuclei and very sparse cytoplasm (Fig. 4). There were abundant fine collagen fibres. Mast cells were scattered in the ground substance. Protein S-100 stain was positive. A diagnosis of neurofibroma was made.

There was no evidence of generalized von Recklinghausen's disease.

DISCUSSION

This solitary subungual neurofibroma presented differently to the diffuse, digital neurofibroma photographed in Zaias' text (1), the article by Fleegler & Zeinowicz (2) and the subungual fibromatosis reported by Fröhlich (3).

The rare reported cases mainly involve the fingers (1, 2, 4–6). In the proximal nail fold they produce a longitudinal groove (1) or a chronic paronychia (2, 5); subungually, they may result in painful clubbing (6). Tumours of the toes are less frequent in the subungual location (7–9).

REFERENCES

1. Zaias N. The nail in health and disease. 2nd ed. Norwalk, CT: Appleton & Lange, 1990: 213 pp.
2. Fleegler EJ, Zeinowicz RJ. Tumors of the perionychium. *Hand Clin* 1990; 6: 113–133.

3. Fröhlich W. Fibromatosis subungualis. *Derm Wschr* 1939; 109: 1211–1212.
4. Niizuma K, Iijima KN. Solitary neurofibroma: a case of subungual neurofibroma on the right third finger. *Arch Dermatol Res* 1991; 283: 13–15.
5. Bhushan M, Telfer NR, Chalmers RJG. Subungual neurofibroma: an unusual cause of nail dystrophy. *Br J Dermatol* 1999; 140: 777–778.
6. Shelley ED, Shelley WB. Exploratory nail plate removal as a diagnostic aid in painful subungual tumours: glomus tumour, neurofibroma, and squamous cell carcinomas. *Cutis* 1986; 38: 310–312.

7. Runne U, Orfanos CE. The human nail. *Curr Probl Dermatol* 1981; 9: 102–149.
8. Dangoisse C, André J, de Dobbeleer G, Van Geertruyden J. Solitary subungual neurofibroma. *Br J Dermatol* 2000; 143: 1116–1117.
9. Haneke E. Subungual Tumoren. *Z Dermatol* 1998; 184: 155–157.

Accepted March 7, 2001.

R. Baran¹ and E. Haneke²

¹Nail Disease Center, 42, rue des Serbes, FR-06400 Cannes, France and ²Klinikk Buenas, Lokkeasveien 3, NO-1300 Sandvika, Oslo, Norway. E-mail: baran.r@club-internet.fr or BARAN.R@wanadoo.fr

Lichen Sclerosus et Atrophicus Appearing in Old Scars of Burns from Welding Sparks

Sir,

Lichen sclerosus et atrophicus (LSA) is an inflammatory dermatosis of unknown cause. Although it has been reported in a variety of post-traumatic clinical cases (1–6), we believe this to be the first report of its having developed in old scars from welding sparks.

CASE REPORT

A 46-year-old man, otherwise healthy, who was a sheet-metal worker and had often done welding over a period of more than 20 years, was referred to the Dermatological Clinic in Lund with a 7-month history of white, firm plaques developing in many of his old scars left by welding sparks. Clinical examination revealed multiple porcelain-white, shiny, round, indurated lesions 5–10 mm in diameter on the front of his trunk. Some of these were surrounded by an erythematous halo and had a curious appearance (Fig. 1). Similar but less indurated lesions could be seen on his shoulders and the volar aspects of his lower arms. The man was certain that his recent skin lesions had developed on spots where he had been hit over the years by welding sparks, which had burned holes in his shirts and burned the skin below. On his trunk and arms there was also a number of small, slightly hypopigmented maculae, likewise representing old scars from welding sparks, which had not changed, however. General examination revealed a shiny, white discoloration and sclerosis on the glans and the shaft of his penis. He had been circumcised early in life. The genital skin lesions had been present for more than 10 years. The patient had thought that they represented a normal variant.

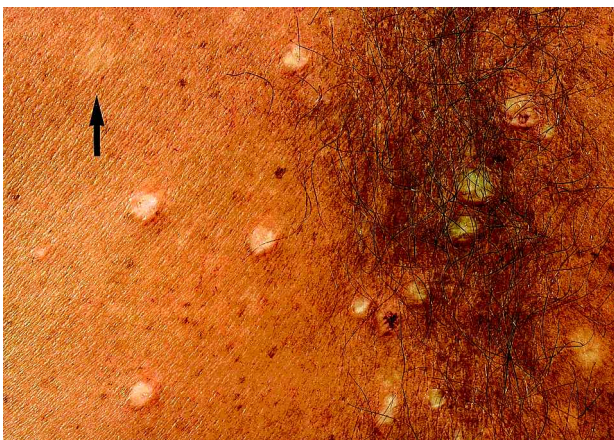


Fig. 1. Lichen sclerosus et atrophicus in old scars of burns from welding sparks. An unchanged scar can be seen at the upper left (arrow).

Borrelia serology was negative. Further laboratory investigation showed thyroid function to be normal and a test for antinuclear antibodies to be negative.

Skin biopsies obtained from three of the changed lesions on his trunk and arms revealed hyperkeratosis, the epidermis to be thin and atrophic, and homogenization of the dermis, with loss of elastic fibres and the presence of small lymphocytic infiltrates. The histological picture was consistent with that of LSA. A skin biopsy from an unchanged scar showed scar tissue only.

DISCUSSION

There have been several reports of LSA occurring following trauma. It has been reported under tight clothing (1), at a vaccination site (2), in a surgical scar (3), on a skin area treated by radiotherapy (4), after severe sunburn (5) and in an old burn scar (6). Often, there has been a long delay between the trauma and appearance of the disease. In the case reported by Meffert & Grimwood (6), for example, the time elapsed between the burn and the appearance of LSA was nearly 50 years.

In our patient, the patches of LSA appeared in areas that had been hit by welding sparks, usually at a much earlier time, and where the “usual” hypopigmented soft burning scars had developed. We are unable to find any previous reports of LSA following this particular form of cutaneous injury, although other reports of LSA indicate that isomorphic phenomena may occur following trauma of other types.

REFERENCES

1. Todd P, Halpern S, Kirby J, Pembroke A. Lichen sclerosus and the Köbner phenomenon. *Clin Exp Dermatol* 1994; 19: 262–263.
2. Anderton RL, Abele DC. Lichen sclerosus et atrophicus in a vaccination site. *Arch Dermatol* 1976; 112: 1787.
3. Pass CJ. An unusual variant of lichen sclerosus et atrophicus: delayed appearance in a surgery scar. *Cutis* 1984; 33: 405–408.
4. Yates VM, King CM, Dave VK. Lichen sclerosus et atrophicus following radiation therapy. *Arch Dermatol* 1985; 121: 1044–1047.
5. Milligan A, Graham-Brown RAC, Burns DA. Lichen sclerosus et atrophicus following sunburn. *Clin Exp Dermatol* 1988; 13: 36–37.
6. Meffert JJ, Grimwood RE. Lichen sclerosus et atrophicus appearing in an old burn scar. *J Am Acad Dermatol* 1994; 31: 671–673.

Accepted March 16, 2001

Eva Tegner¹ and Irena Vrana²

Departments of ¹Dermatology and ²Pathology, University Hospital, SE-221 85 Lund, Sweden. E-mail: eva.tegner@derm.lu.se