

## Darier's Disease Seen with Cutis Verticis Gyrate

Sir,

Darier's disease is a dominantly inherited skin disorder with abnormal keratinization. It is characterized by the symmetrical eruption of keratotic reddish-brown papules in the seborrheic areas of the body (1).

Cutis verticis gyrata (CVG) is an unusual condition that typically occurs on the scalp and is characterized by the formation of ridges and furrows (2). These characteristic scalp changes are caused by primary and secondary conditions (3). In a review of the literature we could not find any previous report of combined CVG and Darier's disease.

### CASE REPORT

A 53-year-old woman presented to the Dermatology Department of the Medical Faculty at Atatürk University with refractory, generally scaly, crusted, pruritic lesions. A localized, persistent papular eruption had developed on the upper part of the patient's back when she was 15 years old. The disease progressively involved her chest, scalp, extensor surfaces of the extremities and face. Dermatologic examination showed numerous greasy, brownish, crusted, keratotic, discrete, coalescent papules. The face, neck, scalp, chest, back and extremities of the patient were diffusely involved. The nails showed longitudinal streaks. The hard palate and pharynx were not involved. A biopsy confirmed the diagnosis of Darier's disease. In addition, the patient's mother, son and daughter had the same disease.

The patient had first noticed the formation of a few small ridges and furrows over the forehead and scalp 3 years previously, which became progressively more pronounced. Examination revealed folds diffusely over her forehead and the frontal and parietal areas of the scalp (Fig. 1) which could not be obliterated by pressure. There were no changes in hair colour or thinning of the hair. On the basis of these findings, the diagnosis of CVG was made clinically.

The patient had no history of seizures, mental retardation, cerebral palsy, psychiatric disorders or eye disorders. She did not reveal a family history of a similar scalp condition. Findings of the physical examination, including complete neurologic and ophthalmologic examinations, were unremarkable. Complete blood cell count and serum chemistries, X-ray examinations of the cranium, arms and legs, thyroid function tests and VDRL test were all normal.

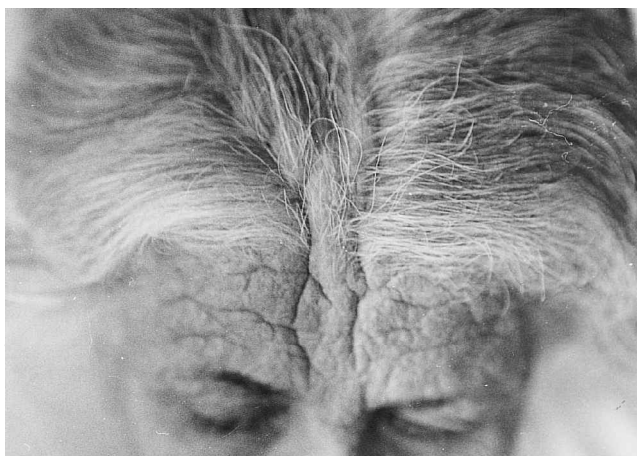


Fig. 1. Features of cutis verticis gyrata.

The patient was treated with 50 mg/day acitretin and the skin lesions improved over a period of 3 months. At this time the CVG lesions had also partially resolved.

### DISCUSSION

Darier's disease is most common in men and usually begins in adolescence. Several authors have noticed a high prevalence of mental disorder or epilepsy associated with Darier's disease, although this was not found in our patient or her family.

CVG is a descriptive term for a condition of the scalp in which deep furrows and folds are seen that resemble the outer surface of the cerebrum (2). The possible etiologies may be categorized as primary essential, primary non-essential and secondary CVG (2, 3). Primary and secondary CVG have been reported in the literature to occur mainly in male patients. In primary CVG, the folds are usually symmetrical, but they are more likely to be asymmetrical in secondary CVG, especially when they are due to a naevus or tumour. The affected area is generally asymptomatic, but when cutaneous secretions accumulate in the grooves an unpleasant odour may result. This accumulation can also cause a burning sensation, pruritus or tenderness (2, 3).

In primary CVG, mental deficiency, epilepsy or idiocy schizophrenia association may occur (2, 3). CVG may be secondary to other disorders of the scalp such as tumours, cerebriform intradermal naevi, neurofibromas and dermatofibromas. Alterations in the scalp may result from acute and chronic inflammatory conditions such as eczema, psoriasis, folliculitis, impetigo, erysipelas and pemphigus (2, 3). In persons of normal intelligence the disease with which CVG most commonly occurs is pachydermoperiostosis (4). Our patient had no associated medical problems and her skeletal X-ray examinations were normal. We would classify our patient as having CVG secondary to chronic skin inflammation associated with Darier's disease. Treatment with acitretin improved her condition and resulted in some involution of scalp furrows.

### REFERENCES

- O'Malley MP, Haake A, Goldsmith LA, Berg D. Localized Darier's disease. Implications for genetic studies. *Arch Dermatol* 1997; 133: 1134–1138.
- Garden JM, Robinson JK. Essential primary cutis verticis gyrata. *Arch Dermatol* 1984; 120: 1480–1483.
- Diven DG, Taunus T, Raimer SS. Cutis verticis gyrata. *Int J Dermatol* 1991; 30: 710–712.
- Åkesson HO. Cutis verticis gyrata and mental deficiency in Sweden. I. Epidemiologic and clinical aspects. *Acta Med Scand* 1964; 175: 115–117.

Accepted 25 October 2000.

Muammer Parlak, Teoman Erdem, Ali Karakuzu, Ali Ihsan Güleç and Necmettin Akdeniz  
Department of Dermatology, Faculty of Medicine, Atatürk University, T-25240 Erzurum, Turkey. E-mail: karakuzuali@hotmail.com.