

Lichen Myxedematosus Associated with Chronic Hepatitis C: A Case Report

Sir,

Lichen myxedematosus (LM) is a rare pathology, described for the first time by Dubreuilh (1) in 1906, characterized by the accumulation of mucinous material in the dermis, with no disorder in the thyroid gland, and usually associated with paraproteinemia. In 1953, Montgomery & Underwood (2) classified LM into 4 clinical types: (1) a generalized lichenoid eruption, later denominated scleromyxedema; (2) a discrete papular form; (3) localized-to-generalized lichenoid plaques; and (4) urticarial plaques and nodular eruptions that usually evolve into the lichenoid form. We describe here a case of discrete papular LM in a patient affected by virus C hepatopathy.

CASE REPORT

A 70-year-old man presented with a 2-year history of papular lesions on the clavicle, neck, face and scalp and, for some months before our examination, on the buttocks and the backs of the hands. The lesions were 2–4 mm in diameter, whitish in colour, covered by normal skin and mostly linear (Fig. 1). On the scalp, some lesions were papulonodular with hyperkeratosis. On the face, lesions were prevalent beneath the eyelids and in the eyebrow area, associated in the latter case with loss of eyebrow hair. The lesions were extremely itchy and the patient also complained of a burning sensation. The case history showed that the patient had been affected by chronic hepatitis C virus (HCV) since 1991 and that for about 25 years he had been taking benzodiazepine drugs for chronic depression.

Histologic examination of several skin lesion biopsies from different sites showed a modest hyperkeratosis of the epidermis and an accumulation of mucinous material in the reticular and middle dermis (Fig. 2), which was positive on Alcian blue staining. There was dissociation of collagen fibers due to abundant mucin deposits. In addition, numerous large activated fibroblasts were revealed.

Laboratory data indicated no abnormalities in peripheral blood count, serum gamma-globulin level, serum electrophoresis, immunoelectrophoresis and cryoglobulin. Triiodothyronine, thyroxine and thyroid-stimulating hormone (TSH) levels were normal. Tests for anti-TSH receptor antibody and anti-TSH antibody were negative. Serum glutamic oxaloacetic transaminase and glutamic pyruvic transaminase levels were elevated (151 and 171 IU/l, respectively). Both anti-HCV antibodies and HCV RNA (reverse transcriptase polymerase chain reaction) tests were positive, and chronic active

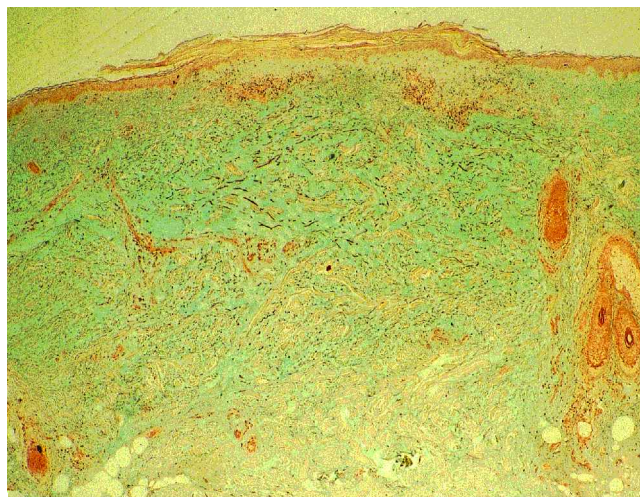


Fig. 2. Skin biopsy showing abundant mucin in superficial and middle dermis with consequent dissociation of collagen fibers.

hepatitis was confirmed by liver biopsy. Urinalysis revealed no abnormalities and Bence–Jones protein was not detected.

DISCUSSION

In total, 130 cases of LM appear in the literature, making it a rare pathology; in addition, these reported cases cover, in the main, only the clinical form denominated scleromyxedema. Both sexes can be affected and there is a prevalence in the age range 30–50 years. The etiology is unknown and although there are some clinical and histologic similarities to the cutaneous features of myxedema, there is no thyroid dysfunction in patients with LM (3). LM is usually associated with paraproteinemia, particularly in scleromyxedema. For this reason, a pathogenetic hypothesis for this pathology would attribute to a lambda chain IgG (4), produced following cellular dyscrasia, a role as a stimulator of dermal fibroblasts which then produce abundant mucin. In contrast, the serum of LM patients deprived of paraprotein retains the capacity to stimulate fibroblast proliferation, and this holds true for all those forms of LM where paraproteinemia is not present. We could therefore hypothesize the presence of another unidentified serum factor or that there is an altered metabolism in dermal fibroblasts.

The case presented is of interest on 2 counts: firstly, because of the rarity of the pathology, discrete LM not associated with paraproteinemia; and secondly, because of its association with a virus C hepatopathy. Such an association has been revealed in a Japanese study (5), in which of the 16 LM cases reported, 8 showed liver dysfunction with anti-HCV antibodies, while only 3 cases showed paraproteinemia. The authors maintained that this association of pathologies had only been seen in Japan, with the exception of a case described by Rongioletti & Rebora (6). Our case, therefore, is only the second non-Japanese report of LM associated with HCV. This infection could be the trigger for the stimulation of some unknown serum factor that determines fibroblast

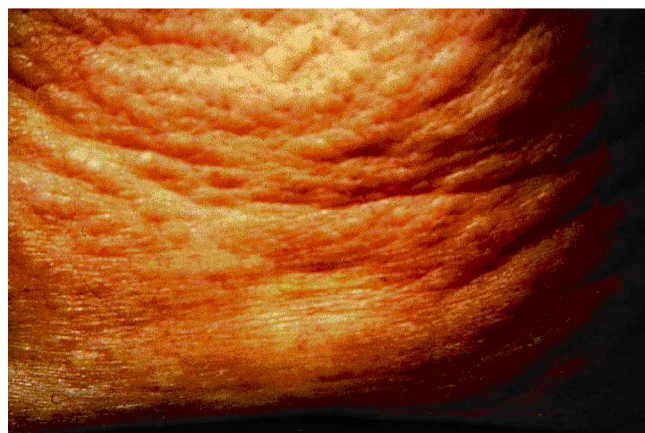

Fig. 1. Multiple, linear, flesh-coloured papules on the back of the neck.

activation and consequent production and deposition of mucinous material in the dermis.

As regards therapy, LM is very difficult to treat. Various agents have been tried, including melphalan, prednisone, cyclophosphamide, clorambucil, radiation, PUVA, plasma exchange, 2-chlorodeoxyadenosine, isotretinoin, photophoresis and interferon- α . None of these agents has been universally effective and many are associated with significant toxicity. Our patient's clinical state dictated an exclusively topical therapy using steroids and emollient creams, which produced a moderate improvement.

REFERENCES

1. Dubreuilh W. Fibromes miliaries folliculaires: Sclerodermie consecutive. *Arch Dermatol Syph* 1906; 7: 569–570.
2. Montgomery H, Underwood LJ. Lichen myxedematosus

- (differentiation from cutaneous myxedemas or mucoid states). *J Invest Dermatol* 1953; 20: 213–233.
3. Perry HO, Montgomery H, Stickney JM. Further observations on lichen myxedematosus. *Ann Intern Med* 1960; 53: 955–969.
4. Harper RA, Rispler J. Lichen myxedematosus serum stimulates human skin fibroblast proliferation. *Science* 1978; 199: 545–547.
5. Hiroyuki B, Hiromichi T, Yukiko N, Toshihiko I, Yoshifumi H. Lichen myxedematosus associated with chronic hepatitis C. *Int J Dermatol* 2000; 39: 212–215.
6. Rongioletti F, Rebora A. Worsening of lichen myxedematosus during interferon alfa-2a therapy for chronic active hepatitis C. *J Am Acad Dermatol* 2000; 38: 760–761.

Accepted October 27, 2000.

M. A. Montesu¹, F. Cottoni¹, R. Sanna² and D. Cerimele¹

¹Department of Dermatology, University of Sassari, Viale San Pietro 43, IT-07100 Sassari, Italy and ²Dermatology Unit, Local Health Board n°1, Sassari, Italy. E-mail: fcottoni@ssmain.uniss.it.

The Asp84Glu Variant of the MC1R Gene in Norwegian Melanoma Patients

Sir,

Pigmentation traits are dependent on the relative amounts of eumelanin and pheomelanin present in the skin. Eumelanin is photoprotective whereas the red pheomelanin may contribute to UV-induced skin damage, caused by free radicals generated after UV exposure. In mammals, the relative proportions of pheomelanin and eumelanin are regulated by melanocyte-stimulating hormone (MSH), which acts via its receptor, MC1R (MIM 155555), on melanocytes (1, 2).

Variants of MC1R were associated with sun sensitivity and red hair in a UK population (2), and were considered a susceptibility gene for melanoma development. The Asp84Glu variant was later found to be associated with sporadic melanoma independent of skin type (3).

In this study we wanted to analyze this specific mutation in Norwegian melanoma patients, given the reported high frequency of Asp84Glu in melanomas.

MATERIAL AND METHODS

Patients

DNA from patients participating in the Norwegian Melanoma Project 1991–93 was extracted from paraffin-embedded lesions (for details, see protocols in QIAamp Blood Kit and QIAamp Tissue Kit Handbook 01/97). Specimens were collected from 2 hospitals in Oslo. The lesions were 69 melanomas, 8 atypical naevi and 20 benign naevi. All patients were Caucasian, and the skin type was reported in 63/69 patients with melanoma. The majority of patients were Fitzpatrick skin types II (22/63) and III (32/63). Eight of 64 melanoma patients were red-haired and 18/63 had freckled skin.

Mutation analysis

The MC1R gene was amplified by nested PCR using primers 5'-ACAGGACTATGGCTGTGC-3' and 5'-GCGTAGAAGATGGAGATG-3' to amplify a 503 bp product. The next PCR used 5'-TGA GCTTGGTGGAGAACGC-3' and 5'-AGGAAGCAGAGGCTGGA CAG-3' to produce a 253 bp product using the 503 bp product as template.

PCR conditions were 95°C for 3 min, followed by 30 cycles at 94°C (30 s), 54°C first reaction/60°C second reaction (30 s), 72°C (30 s). The Asp84Glu allele was identified by digestion with AVA II (37°C, 18 h), and the products were examined after electrophoresis in 2% agarose gel. Wild type (asp/asp) was identified by 153 and 100 bp fragments and homozygotes for the mutant allele (glu/glu) by 253 bp fragments.

Mutants were analyzed by automated sequencing using the BigDye Terminator Cycle Sequencing Ready Reaction Kit (Perkin Elmer). The products were prepared for sequencing using the PCR product pre-sequencing kit (Amersham Life Science, Cleveland, OH) according to the manufacturer's instructions.

RESULTS

One variant allele (1/69) was found in heterozygous form at codon 84 in 1 melanoma (Fig. 1). The finding was confirmed by sequencing (Fig. 2). No naevi (0/28) harbored variant alleles at codon 84.

DISCUSSION

Our study did not support the view that the Asp84Glu variant is associated with melanoma, as reported by the case-control study of Valverde et al. (3).

In a larger case-control study by Ichii-Jones et al. (4), allele frequencies did not differ between melanoma cases and controls. They studied the Asp84Glu variant and 2 other variant alleles thought to be relatively common (2). Recently, Healy et al. (5) reported, based on new investigations, that the Asp84Glu variant is not as frequent as previously suspected in melanoma patients.

To date, more than 20 variants of MC1R are known. Three particular variants, Arg151Cys, Arg160Trp and Asp294Cys, are strongly associated with red hair, with a relative risk of 8–15. These same 3 variants were over-represented in individuals with fair skin (6).

There seems to be an agreement that MC1R variants are associated with red hair and fair skin, phenotypes that render