

Disseminated Superficial Porokeratosis with Mucosal Involvement

Sir,

Porokeratosis is an epidermal disorder with an autosomal dominant mode of inheritance and partial penetrance. Sporadic cases can also occur through somatic mutations (1). We present the case of a man with disseminated porokeratosis of the skin on the extremities (arms, forearms, and dorsum of the hands and legs), face and genital areas, as well as involvement of the oral mucosa.

CASE REPORT

A 40-year-old man presented with a 22-year history of numerous non-pruritic, disseminated, small annular plaques. They started on the scrotum but in the later years other areas were also affected. There was no family history of a similar condition.

Physical examination revealed multiple atrophic annular plaques with an elevated hyperkeratotic border located on the face, extremities (arms, forearms, and dorsum of hands and legs), penis, scrotum and perianal region (Fig. 1). Opalescent rings with hyperemic borders were present on the oral mucosa (Fig. 2). On the tongue mucosa a large, dull, erythematous plaque with enhanced wrinkling was seen (Fig. 3).

The clinical diagnosis was porokeratosis. Biopsy specimens taken from the skin and tongue mucosa showed characteristic cornoid lamellae and confirmed the clinical diagnosis (Fig. 4).

General analytical, immunological and ophthalmological studies did not reveal any relevant pathological findings.

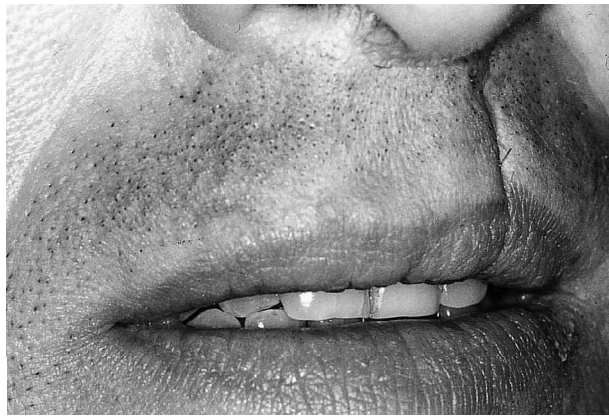


Fig. 1. Multiple porokeratotic lesions on the face.

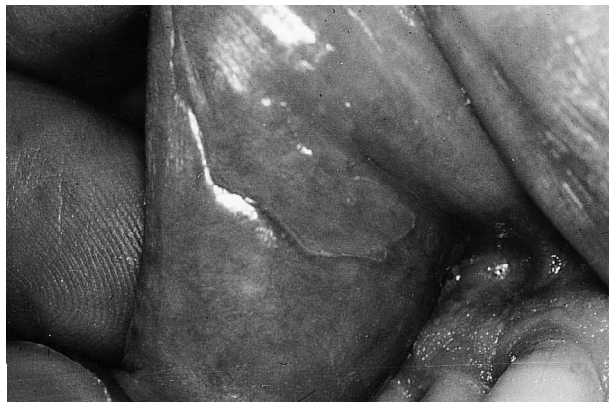

Fig. 2. Porokeratotic lesion on the buccal mucosa.

DISCUSSION

In 1937, Andrews introduced the term disseminated superficial porokeratosis to refer to a disseminated and superficial form of porokeratosis (2). This form has no mucosal involvement (3). A further 2 variants were described, disseminated superficial actinic porokeratosis (4) and porokeratosis plantaris, palmaris et disseminata (5). In porokeratosis plantaris, palmaris et disseminata as well as in classic porokeratosis of Mibelli, the mucosa is rarely affected (3). All of these clinical variants are included in Schamroth and co-workers' classification (3).

The lesions of our patient are disseminated but are not localized exclusively on sun-exposed areas. Moreover, the palms and soles are not affected. Thus, initially he was diagnosed with disseminated superficial porokeratosis. However, this porokeratosis type does not present mucosal involvement as in this case (3).

Mucosal affection in porokeratosis is infrequent and it is exceptional for the tongue to be affected. Cornoid lamellation was initially considered to derive from the acrosyringium. It is now accepted that cornoid lamellae originate not only from eccrine sweat ducts, but also from the epidermis. In this way mucosal involvement can be explained (6).

To be able to classify a disseminated porokeratosis without a distribution suggesting sun exposure, not affecting the

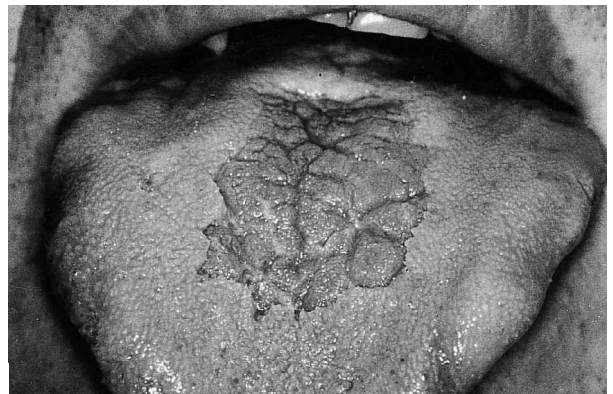

Fig. 3. Large porokeratotic lesion on the dorsal tongue.

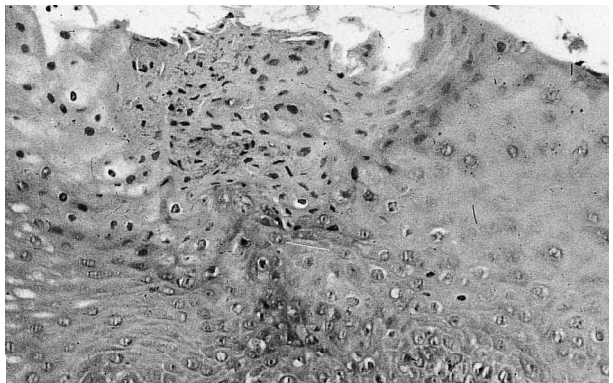


Fig. 4. Histology of the cornoid lamellae, containing parakeratotic nuclei in an indentation in the epidermis (biopsy of the tongue).

palms and soles but involving the mucosa, various possibilities can be considered: (i) Mucosal involvement could be included as a manifestation of disseminated superficial porokeratosis; (ii) A new type of porokeratosis could be established (disseminated superficial porokeratosis with mucosal involvement); (iii) This may be an unusual form of porokeratosis plantaris, palmaris et disseminata without initial involvement of palms and soles (7, 8).

REFERENCES

- Larregue M, Prigent F, Lorette G, Cannel C, Titi M, Champion R, Alcalay D. Porokeratosis de Mibelli chez deux jumeaux monozygotes. *Ann Derm Venereol* 1981; 108: 151–156.
- Andrews GC. Porokeratosis (Mibelli) disseminated and superficial type. *Arch Dermatol Syphilol* 1937; 36: 1111.
- Schamroth JM, Zlotogorski A, Gilead L. Porokeratosis of Mibelli. Overview and review of the literature. *Acta Derm Venereol* 1997; 77: 207–213.
- Chernosky ME. Porokeratosis: report of twelve patients with multiple superficial lesions. *South Med J* 1966; 59: 289–294.
- Gust SB, Osbourn RA, Lutzner MA. Porokeratosis plantaris, palmaris, et disseminata: a third type of porokeratosis. *Arch Dermatol* 1971; 104: 366–373.
- Wade TR, Ackerman AB. Cornoid lamellation. A histologic reaction pattern. *Am J Dermatopathol* 1980; 2: 5–15.
- Neumann RA, Knobler RM, Gebhard W. Unusual presentation of porokeratosis plantaris palmaris et disseminata. *J Am Acad Dermatol* 1989; 2: 1131–1133.
- Patrizi A, Passarini B, Minghetti G, Masina M. Porokeratosis palmaris et plantaris disseminata. An unusual clinical presentation. *J Am Acad Dermatol* 1989; 21: 415–418.

Accepted October 16, 2000.

E. Rosón, I. García-Doval, C. De La Torre, A. Losada, T. Rodríguez, C. Ocampo and M. Cruces
Servicio de Dermatología, Complejo Hospitalario de Pontevedra (Hospital Provincial), C/Loureiro Crespo s/n, Pontevedra, Galicia, Spain.

Mechanic's Hand: A Clinical Diagnostic Aid in Dermatomyositis

Sir,

Dermatomyositis is an autoimmune inflammatory disorder of the skin and muscle, characterized by certain cutaneous features such as Gottron's papules, heliotrope erythema and poikilodermatous rash. We report here a patient with dermatomyositis with a rarely described cutaneous feature, "mechanic's hand", which may serve as a useful diagnostic aid.

CASE REPORT

A 42-year-old male presented with the chief complaints of fever, diffuse erythema with hyperpigmentation on the face and trunk, and oral ulcers for the past 3 months. The lesions on his back showed the characteristic "shawl sign" (Fig. 1). On the dorsal surface of the distal and proximal interphalangeal joints of both hands were scaly, violaceous macules, papules and plaques. He also had scaly, non-pruritic keratotic papules on the ulnar aspect of the thumb, radial aspect of the other fingers and palms of both hands, i.e. mechanic's hands (Fig. 2), and no history of drug intake, photosensitivity, joint pain, muscle weakness or weight loss. There were no neurological, respiratory or gastrointestinal complaints prior to the onset of symptoms.

The systemic examination was within normal limits. A clinical suspicion and the working diagnosis were dermatomyositis. Systemic lupus erythematosus had to be ruled out. Routine investigations, i.e. haemogram, serum bilirubin, renal function tests, blood sugar, urinalysis, examination of stool, chest X-ray and electrocardiogram, were within normal limits. During admission he gradually developed proximal muscle weakness, and his muscle enzymes were creatine phosphokinase (CPK) 1971 IU and lactate dehydrogenase (LDH) 395 IU. Antinuclear antibodies were present in a speckled pattern, serum glutamic-oxaloacetic transaminase (SGOT) 57 IU and serum glutamate pyruvate transaminase (SGPT) 110 IU. The electromyogram was suggestive of myopathy. Muscle biopsy showed non-specific features. Ultrasonography of the abdomen and pelvis was normal. Per rectal examination and examination of the genitalia were normal. Histology of a plaque from the back showed epidermal atrophy, basal

cell degeneration with perivascular mononuclear infiltrate and myxoid change in the upper dermis. Direct immunofluorescence showed immunoglobulin G and C3 at the basement membrane. Histology of a papule from the finger showed hyperkeratosis, parakeratosis, acanthosis, and perivascular chronic inflammation and myxoid change.

Internal malignancy was ruled out by a detailed history, clinical examination and ultrasonogram of the abdomen and pelvis. The above findings confirmed the diagnosis of dermatomyositis and the patient was treated with dexamethasone pulse therapy in the form of intravenous dexamethasone 100 mg on 3 consecutive days every month. He was simultaneously started on a daily dosage of 40 mg prednisolone and azathioprine 150 mg orally. After 2 months of treatment, there was a significant improvement in the myopathy and skin lesions. The keratotic papules and plaques flattened, and the erythema completely subsided. The enzyme levels returned to almost normal levels: CPK 254.4 IU and LDH 24.9 IU.

DISCUSSION

Dermatomyositis is a disorder mainly of skin, muscle and blood vessels characterized by erythematous and oedematous changes in the skin, with associated muscle weakness and inflammation. The pathognomonic cutaneous sign of dermatomyositis is the presence of Gottron's papules, found in 70–80% of patients, and Gottron's sign. The characteristic signs include: (i) heliotrope rash (30–60%); (ii) periungual telangiectasia; (iii) violaceous erythema on the dorsal aspects of the hands and fingers, extensor aspects of the forearms and upper arms, deltoids, posterior shoulders and neck (shawl sign, 22%), and V area of the anterior neck and upper chest (V sign, 36%); and (iv) mechanic's hand: bilateral, symmetric confluent hyperkeratosis with the appearance of that produced by manual labour, distributed along the ulnar aspect of the thumb and radial aspect of the fingers, also prominent on the index and middle fingers, with occasional extension to the plantar surface. It may present as a roughening and cracking