

Intravenous Pyogenic Granuloma of the Hand

Hikomiki Hayashi, Tadamichi Shimizu, Tetsuri Matsumura and Hiroshi Shimizu

Department of Dermatology, Hokkaido University Graduate School of Medicine, Kita-ku, Sapporo 060-8638, Japan.

E-mail: hiromiki@med.hokudai.ac.jp

Accepted May 29, 2001.

Sir,

The so-called intravenous pyogenic granuloma (IVPG) is an intravenous counterpart of the pyogenic granuloma. IVPG, first reported by Cooper et al. (1) in 1979, is a rare benign intravascular tumor that usually occurs in the neck and upper extremities. Here, we report a case of IVPG found in the right thenar of the hand.

CASE REPORT

A 35-year-old woman presented with a 2-year history of a tender, mobile subcutaneous nodule on the thenar of the right hand but with no history of trauma at that site. Physical examination revealed a 3 × 7-mm-sized subcutaneous nodule with a slightly erythematous surface (Fig. 1). The tumor was treated by surgical excision. Histopathologic examination of the tumor revealed an intravenous polyp composed of lobules of capillaries separated by fibrous connective tissue attached to the wall of the vein by a fibrovascular stalk (Fig. 2a). The lesion consisted of a uniform mass of endothelial hyperplasia and capillary proliferation (Fig. 2b). The histopathologic diagnosis of IVPG was made.

DISCUSSION

IVPG is a rare type of pyogenic granuloma confined within the lumen of a vein. IVPG was originally thought to be a reactive process to trauma or pyogenic infections but is now considered to be a lobular capillary hemangioma (2). To our knowledge, only 25 cases of IVPG have been reported in the world literature until now. While IVPG usually occurs on the deep part of the neck and upper extremities, occurrence on the hand is rare and only 2 cases have been reported (3, 4).

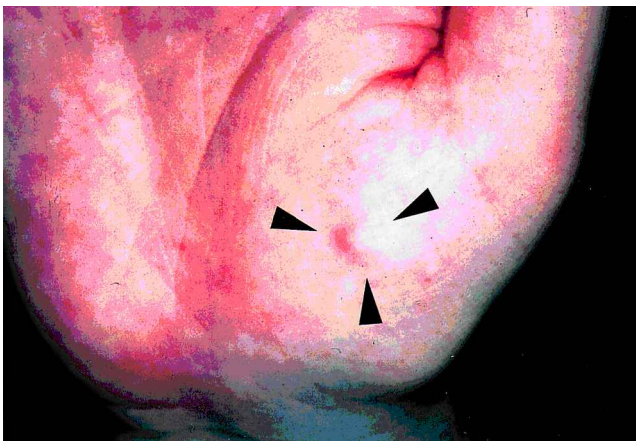


Fig. 1. Clinical appearance of the subcutaneous nodule on the right thenar of the hand.

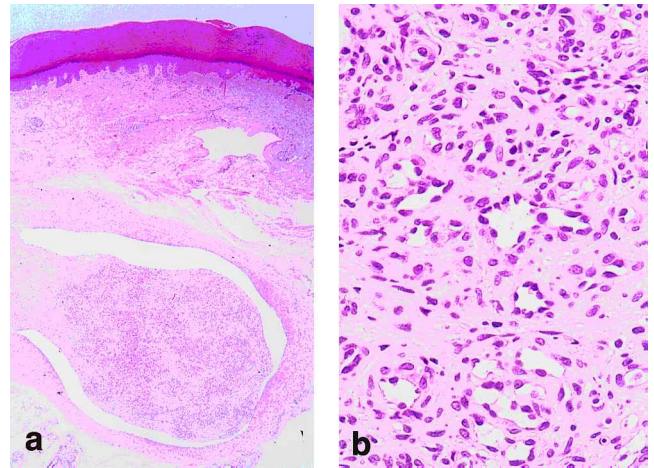


Fig. 2. (a) Photomicrograph of subcutaneous nodule showing an intravenous polyp composed of lobules of capillaries separated by fibrous connective tissue attached to the wall of the vein by a fibrovascular stalk. (b) Higher magnification shows monotonous endothelial hyperplasia and capillary proliferation (hematoxylin and eosin; original magnification: a × 40; b × 200).

Histopathologic investigation identified the typical features of an intraluminal polyp comprising lobules of capillaries lined by flattened or rounded endothelial cells. The capillaries were supported by sparse spindle cells in a fine collagenous myxoid stroma. In contrast to mucocutaneous pyogenic granuloma, IVPG contained a sparse inflammatory infiltrate (5). The histopathological differential diagnosis of IVPG includes intravascular papillary endothelial hyperplasia, angiolymphoid hyperplasia with eosinophilia and angiosarcoma (5). Intravascular papillary endothelial hyperplasia is thought to show an unusual pattern of a thrombus or hematoma that appears to be undergoing tissue organization (6). The characteristic histopathological appearance shows a complex papillary or sponge-like structure with thrombi and hemosiderin deposition (1). Lack of these findings in our case pointed to a diagnosis of IVPG. Angiolymphoid hyperplasia with eosinophilia is differentiated by the lack of nodular lymphoid aggregates with eosinophils, and angiosarcoma by the absence of atypical cells.

Although IVPG has occasionally been reported in the orthopedic and surgical literature (1, 3, 4), few cases of IVPG have been reported by dermatologists. The reason may be that IVPG is frequently located in the deep part of the neck and upper extremities, and clinically diagnosed as an enlarged lymph node, arteriovenous fistula, and bronchial cleft cyst, etc. (1). IVPG is usually asymptomatic and occurs without a history of preceding trauma (5). Therefore, dermatologists should be aware of IVPG as a differential diagnosis when a subcutaneous nodule needs identification.

REFERENCES

1. Cooper PH, McAllister HA, Helwig EB. Intravenous pyogenic granuloma: a study of 18 cases. *Am J Surg Pathol* 1979; 3: 221–228.
2. Mills SE, Cooper PH, Feczner RE. Lobular capillary hemangioma: the underlying lesion of pyogenic granuloma. A study of 73 cases from the oral and the nasal mucous membranes. *Am J Surg Pathol* 1980; 4: 470–479.
3. DiFazio F, Mogan J. Intravenous pyogenic granuloma of the hand. *J Hand Surg* 1989; 14: 310–312.
4. Anderson WJ. Intravenous pyogenic granuloma of the hand. *J Hand Surg* 1985; 10: 728–729.
5. Saad RW, Sau CP, Mulvaney MP, James WD. Intravenous pyogenic granuloma. *Int J Dermatol* 1993; 32: 130–132.
6. Kuo T, Sayers CP, Rosai J. Masson's "vegetant intravascular hemangioendothelioma": a lesion often mistaken for angiosarcoma. *Cancer* 1976; 38: 1227–1236.

Treatment of Lichenified Atopic Eczema with Tacrolimus Ointment

Håkan Granlund, Anita Remitz, Hannele Kyllönen, Antti I. Lauerma and Sakari Reitamo

Department of Dermatology, Helsinki University Central Hospital, Meilahdentie 2, 00250 Helsinki, Finland.

E-mail: hakan.granlund@hus.fi

Accepted June 1, 2001.

Sir,

At present, topical corticosteroids are the mainstay for treatment of atopic dermatitis. In long-term use, however, corticosteroids induce tolerance and some patients may become allergic to these steroids (1). Areas such as lichenified lesions may be resistant to corticosteroid treatment. The atrophogenicity of corticosteroids further limits their use on areas of the skin that are thin, such as the face and neck and flexure regions.

Tacrolimus ointment is the first potential new topical therapy for atopic dermatitis since the introduction of corticosteroids some 40 years ago. Short-term studies in adults and children have shown that tacrolimus ointment is effective and safe in the treatment of atopic dermatitis (2–9). Unlike topical corticosteroids, tacrolimus ointment does not cause skin atrophy (10).

In atopic dermatitis itch, erythema and vesiculation are the first symptoms and signs showing response to treatment, while lichenification takes more time to heal. In the present placebo-controlled, randomized study, we assessed whether 0.1% tacrolimus ointment is also effective on lichenified lesions. We also wanted to measure the effect of tacrolimus on the barrier function in flexure regions, which are vulnerable to thinning and atrophy, when treated with potent topical corticosteroids. Consequently, lichenified elbow flexure regions were selected for treatment.

PATIENTS AND METHOD

Atopic dermatitis patients aged 18 to 60 years were eligible for entry. Patients were required to have a confirmed diagnosis of moderate to severe atopic dermatitis according to Rajka & Langeland (11). Patients had to have a lichenified area on each elbow flexure region of at least 12 cm² and with a lichenification score of at least 2 on a scale from 1 to 3. Patients were allocated 0.1% tacrolimus or a vehicle control (tacrolimus ointment base) based on a 1:1 randomization for a treatment period of 2 weeks. Patients were instructed to apply the ointment to the selected treatment area of the elbow flexure twice daily, with each application separated by about 12 h. The investigator, patient, and study monitor were unaware of the treatment allocation. No concurrent treatment other than emollients or bath oil was allowed during the study.

Assessment was done at baseline and after 3 to 4 days, 7

days and 14 days of treatment and 14 days post-treatment. The investigator graded the treated areas on a scale of 0 to 3 for the severity of erythema, oedema, oozing/crust, excoriation and lichenification of involved skin, and dryness of non-involved skin. The patient graded pruritus of the selected treatment area on a 10-cm visual analogue scale. The primary efficacy endpoint was the change in the combined score for pruritus, erythema, oedema, oozing/crust, excoriation, and lichenification of involved skin, dryness of non-involved skin and pruritus. The pruritus grading was converted to an ordinal scale of 0 to 3 before being added to the combined score. The extent of affected skin at the elbow regions was measured at the same intervals. At the end of the treatment phase, a global assessment of the treated area was made (completely resolved, markedly improved, moderately improved, slightly improved, no change, or worse).

Transepidermal water loss (TEWL) was measured at the treated elbow flexure as described previously (12), and superficial blood flow was measured using a laser Doppler flowmeter (Periflux PF3, Perimed, Sweden). Measurements were taken on days 3, 7, 14 and 28. Skin thickness (the distance between the stratum corneum to lower dermis) of treated lichenified elbow regions was measured with a high-frequency ultrasound device (DUB20-S, taberna pro medium, Lüneburg, Germany) (13). Purified water was used as the transmitting medium for the ultrasound, at a frequency of 30 MHz. The skin thickness was assessed as the average of 4 measurements taken at 1 mm intervals.

Percentage changes between baseline and days 7, 14 and 28 were calculated for each patient. Descriptive statistics are based on these values. Treatment group comparisons were made using the Wilcoxon rank sum test.

RESULTS

Of 16 patients screened, 14 were randomized to receive either 0.1% tacrolimus (6 patients) or vehicle control (8 patients). No major differences in demographics or baseline characteristics of the patients were seen between the groups.

The percentage decrease in the combined symptom score between baseline and the end of the treatment period was significantly greater in the 0.1% tacrolimus group (68.5%) than in the vehicle control group (13.4%) ($p=0.002$). The difference