

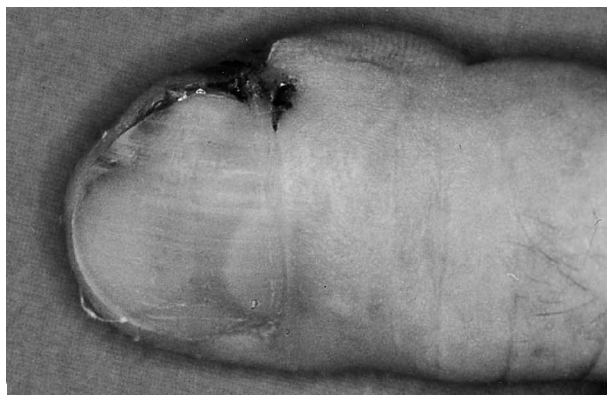Fig. 2. Patient 2: Ulcer near the proximal nail bed.

the aetiological role of periungual or subungual HPV infection (7).

SCC is considered a low-grade malignant tumour, characterized by slow growth and little pain. Treatment depends on the extension of the tumour and may vary from wide local excision to amputation of the distal phalanx and lymph node dissection in the case of metastasis.

We performed the first-choice treatment; that is surgical excision up to the cancer-free margin. No radiation therapy was given as its efficacy is doubtful (3–13), even though its association with surgery is recommended by some authors (2).

SCC has a high incidence of bone invasion and low propensity to lymph node metastasis. Disseminated metastases have rarely been reported, although they are more frequent in relatively young patients (1, 3, 4, 11, 12) and are influenced by the histological degree of differentiation and the depth of invasion of the primary tumour. Disseminated metastases of SCC are associated with a high mortality rate. A 10-year follow-up is recommended, as lymph node or distant metastases may appear many years after treatment (2). A 12-month follow-up with roentgenographic and ultrasonographic study

showed that both our patients were free from disease. The predisposing factors for the development of SCC appeared to be a chronic subungual infection in the first patient and previous repeated trauma in the second patient.

Disorders of the nail apparatus are often considered “minor diseases”, but we stress that if nail lesions are recurrent, persistent or insensitive to treatment, skin biopsy is advisable to prevent misdiagnosis and to single out rare but ambiguous subungual lesions such as achromic melanoma or SCC.

REFERENCES

1. Lai CS, Lin SD, Tsai CW, Chou CK. Squamous cell carcinoma of the nail bed. *Cutis* 1996; 57: 341–345.
2. Kouskoukis CE, Scher RK, Kopf AW. Squamous cell carcinoma of the nail bed. *J Dermatol Surg Oncol* 1982; 8: 853–855.
3. de Berker D, Derbyshire N. Squamous cell carcinoma of the nail bed. *Br J Radiol* 1993; 66: 849.
4. Lombardi LJ, Cleri DJ, Lashinsky AM, Papa TM, D'Amato RF. Squamous cell carcinoma of the nail bed. *South Med J* 1990; 83: 1098–1101.
5. Hazelrigg DE, Renne JW. Squamous cell carcinoma of the nail bed. *J Dermatol Surg Oncol* 1982; 8: 200–201.
6. Patel DU, Rolfes R. Squamous cell carcinoma of the nail bed. *J Am Podiatr Med Assoc* 1995; 85: 547–549.
7. Guitart J, Bergfeld WF, Tuthill RJ, Tubbs RR, Zienowicz R, Fleegler EJ. Squamous cell carcinoma of the nail bed: a clinicopathological study of 12 cases. *Br J Dermatol* 1990; 123: 215–222.
8. Mikhail GR. Subungual epidermoid carcinoma. *J Am Acad Dermatol* 1984; 11: 291–298.
9. Carrol RE. Squamous cell carcinoma of the nail bed. *J Hand Surg* 1976; 1: 92–97.
10. Failla JM. Subungual lipoma, squamous carcinoma of the nail bed, and secondary chronic infection. *J Hand Surg* 1996; 21: 512–514.
11. Campbell CJ, Klokarn T. Squamous cell carcinoma of the nail bed in epidermal dysplasia. *J Bone Joint Surg* 1966; 48: 92–99.
12. Fromer JL. Carcinoma of the nail bed: discussion. *Arch Dermatol* 1970; 101: 66–67.
13. Conill C, Verger E, Vilalta A, Palou J. Case report: squamous cell carcinoma of the nail bed. *Br J Radiol* 1993; 66: 163–164.

Malignant Granular Cell Tumour with Generalized Metastases and Polymyositis

U.-F. Haustein

University of Leipzig, Department of Dermatology, Stephanstr. 11, DE-04103 Leipzig, Germany

E-mail: ufh@medizin.uni-leipzig.de

Accepted May 16, 2001.

Sir,

Granular cell tumour is a rare, benign, soft tissue neoplasm. In 5.4–8.5% of cases it occurs with multiple lesions (1), and in 2% with malignant tumours (2, 3). A common characteristic of the cells is the presence of small cytoplasmic eosinophilic granulations. In terms of their histogenic origin, the results are not conclusive: fibroblasts, myoblasts, Schwann's cells, histiocytes and neurons have been discussed (4, 5).

Here we report on a 69-year-old female patient who was admitted to our hospital suffering from symptomatic polymyositis in the prefinal stage due to a generalized malignant granular cell tumour with metastases in the skeletal musculature. Her clinical course was similar to that of a patient

whose case was published in 1974 (6). The primary lesion could not be identified.

CASE REPORT

The patient was presented to our department in November 1999 with a history of multiple subcutaneous nodules during the previous 2 years. Physical examination revealed more than 100 nodules, 1–1.8 cm in diameter, oval or round, tense, mobile and covered by erythematous, smooth or verrucous skin localized to the trunk, extremities and neck, and with one nodule in the upper margin of the lip.

The lesions had increased in size, and were itchy and painful because of pressure. The primary lesion could not be identified. General health conditions were found to be poor, with a history that included fever, malaise, headache, weakness and muscular pain – particularly *M. deltoideus*, *M. biceps brachii* et *femoris*, *M. triceps brachii* et *surae*, *M. sternocleidomastoideus* and *M. levator palpebrae* – and weight loss.

The laboratory findings revealed anaemia, increase in the blood sedimentation rate, increase in the liver enzymes and creatinine phosphokinase (CPK), excretion of creatine in the urine and polyphasic spikes in the electromyogram (EMG). Antinuclear and anti-Jo1 (histidyl-tRNAsynthetase) antibodies were not detected.

Two deep biopsies were obtained from 2 nodules in the skin and one in the musculature of the *M. deltoideus*. Histopathological examination by haematoxylin and eosin-stained sections revealed irregular epidermal acanthosis. The dermis showed proliferation of polygonal, oval and spindle cells with granular eosinophilic cytoplasm and polymorphic, polychromatic and partly pyknotic nuclei with atypical mitoses grouped in nests, sheets and cords, as well as single cells infiltrating the subcutaneous fat tissue. The muscular lesion was similarly composed with destructions of the muscle fibres, loss of striation, oedema and slight lymphocytic infiltrates surrounding the infiltrating tumour cells (Fig. 1). In addition, the number of sarcolemmal nuclei was increased; the muscle fibres were focally degenerated demonstrating a fine granular or oedematous and homogeneous pattern or even completely destroyed. Immunohistochemical reactivity was positive to S-100 protein, neuron-specific enolase and partially to vimentin.

After 5 days the patient died of cardiac failure. Polychemotherapy had not been started; the application of 100mg prednisolone per day failed to stop the disastrous course of the disease. Autopsy findings revealed generalized metastases in the skin, subcutis, skeletal muscles, in a few joint capsules of the fingers, lymph nodes, spleen and heart muscle, occasionally with neurotropic spreading of the tumour cells along peripheral nerves.

DISCUSSION

Definited diagnosis of granular cell myoblastoma or schwannoma can only be made histologically.

The immunohistochemical findings (4) and the perineural extension of the tumour suggest a granular cell schwannoma origin (7). Furthermore, the cytoplasmic granules are lysosome-like structures containing myelin or its metabolic products. Granular cell schwannoma can clearly be distinguished from xanthoma and histiocytosis gigantocellularis (8). The generalization and malignant transformation of the tumour is remarkable. The histopathology, CPK level and the EMG support a true paramalignant myositis. Whether polymyositis is provoked by the spread of tumour antigens and the induction of a delayed type cytotoxic immune response could not be clarified. Alternatively, the simulation of a polymyositis, caused by diffuse destruction of the muscle fibres by metastases, should be considered.

Taken together, polymyositis can be associated as a paramalignant form or simulated by generalized metastases of a

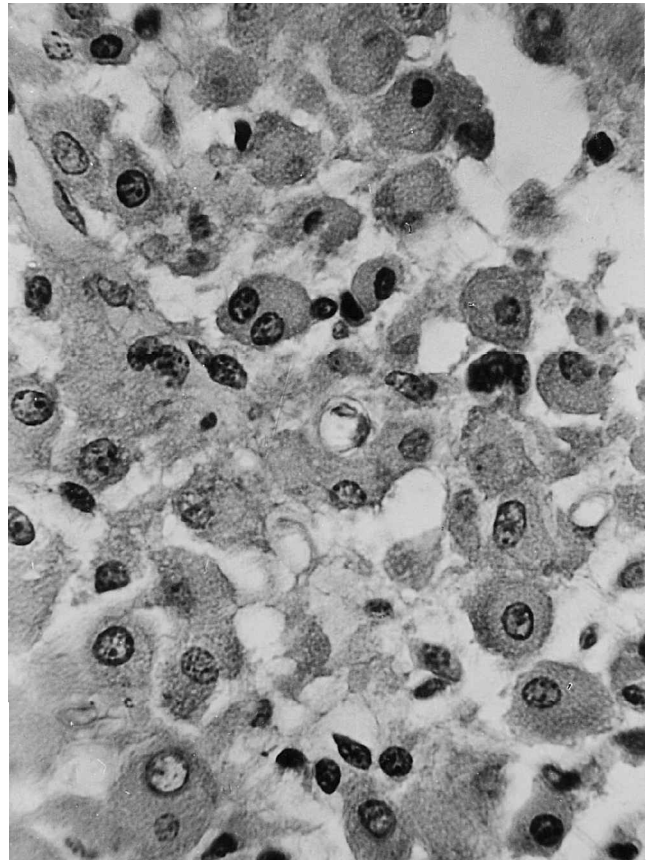


Fig. 1. Metastatic tumour formation within the striated musculus deltoideus. Polygonal polymorphous tumour cells with polychromatic nuclei, pathologic mitoses and granular cytoplasm (H&E, $\times 600$).

malignant tumour in rare events, in our case by a granular cell schwannoma.

REFERENCES:

- Lack EE, Worsham GF, Callihan MD. Granular cell tumor: a clinicopathological study of 110 patients. *J Surg Oncol* 1980; 13: 301–316.
- Benign tumors of peripheral nerves. In: Enzinger FM, Weiss SW. *Soft tissue tumors*. 2nd ed. St. Louis: Mosby, 1988: 757.
- Gokaslan ST, Terzakis JA, Santagada EA. Malignant granular cell tumor. *J Cutan Pathol* 1994; 21: 363–370.
- Junquera LM, Vicente JC de, Losa JL, Albertos JM, López-Arranz JS. Granular-cell tumours: an immunohistochemical study. *Br J Oral Maxillofac Surg* 1997; 35: 180–184.
- Ordóñez NG. Granular cell tumor: a review and update. *Adv Anat Pathol* 1999; 6: 186–203.
- Haustein U-F. Malignes metastasierendes Granularzellmyoblastom Abrikosow mit symptomatischer Dermatomyositis. *Dermatol Monatsschr* 1974; 160: 318–328.
- Fisher E, Wechsler H. Granular cell myoblastoma. A misnomer: electron microscopic and histochemical evidence concerning its Schwann cell derivation and nature (granular cell schwannoma). *Cancer* 1962; 15: 936–954.
- Haustein U-F, Thormann T, Klug H, Friedrich C. Histologische und elektronenmikroskopische Befunde bei Histiocytosis gigantocellularis (multizentrischer Retikulohistiozytose). *Dermatologica (Basel)* 1973; 146: 177–192.