

baseline warts (imiquimod 11% vs. vehicle 6%;  $p=0.488$ ), more imiquimod-treated patients experienced a  $\geq 50\%$  reduction in baseline wart area (38% vs. 14%;  $p=0.013$ ). Use of imiquimod was not associated with any changes in laboratory values, including CD4 count. It was not associated with any adverse drug-related events, and no exacerbation of HIV/AIDS was attributed to the use of imiquimod. However, it appeared that topical imiquimod was still less effective at achieving total clearance than in the studies with HIV-negative patients, which is most likely a reflection of the impaired cell-mediated immunity seen in the HIV-positive population (8).

There has also been a report of improved success when topical imiquimod was combined with more traditional destructive therapy for HPV infection in HIV-positive patients, particularly in the setting of the use of highly-active antiretroviral therapy (HAART) (9). This combination therapy appears to be increasingly more effective as viral load drops and CD4 count rises.

We believe that the case presented, particularly in the context of the studies already conducted, supports the utility of topical imiquimod for the treatment of anogenital HPV in HIV-positive individuals. Further investigation is warranted to determine the most effective regimen for its use, including the possibility of combined therapies and/or concomitant initiation of HAART.

#### REFERENCES

1. Edwards L, Ferenczy A, Eron L. Self-administered topical 5% imiquimod cream for external anogenital warts. *Arch Dermatol* 1998; 134: 25–30.
2. Buetner KR, Spruance SL, Hougham AJ, Fox TL, Owens ML, Douglas JM Jr. Treatment of genital warts with an immune-response modifier (imiquimod). *J Am Acad Dermatol* 1998; 32: 230–239.
3. Beutner KR, Tyring SK, Trofatter KF, Douglas JM, Spruance S, Owens ML, et al. Imiquimod, a patient-applied immune-response modifier for treatment of external genital warts. *Antimicrob Agents Chemother* 1998; 42: 789–794.
4. Tyring SK, Arany I, Stanley MA, Tomai MA, Miller RL, Smith MH, et al. A randomized, controlled, molecular study of condylomata acuminata clearance during treatment with imiquimod. *J Infect Dis* 1998; 178: 551–555.
5. Arany I, Tyring SK, Stanley MA, Tomai MA, Miller RL, Smith MH, et al. Enhancement of the innate and cellular immune response in patients with genital warts treated with topical imiquimod cream 5%. *Antiviral Res* 1999; 43: 55–63.
6. Arany I, Tyring SK. Systemic immunosuppression by HIV infection influences HPV transcription and thus local immune responses in condyloma acuminatum. *Int J STD AIDS* 1998; 9: 268–271.
7. Arany I, Evans T, Tyring SK. Tissue specific HPV expression and downregulation of local immune responses in condylomas from HIV seropositive individuals. *Sex Transm Infect* 1998; 74: 349–353.
8. Gilson RJ, Shupack JL, Friedman-Kien AE, Conant MA, Weber JN, Nayagam AT, et al. A randomized, controlled, safety study using imiquimod for the topical treatment of anogenital warts in HIV-infected patients. Imiquimod Study Group. *AIDS* 1999; 13: 2397–2404.
9. Conant MA. Immunomodulatory therapy in the management of viral infections in patients with HIV infection. *J Am Acad Dermatol* 2000; 43: S27–30.

## Delayed Granulomatous Lesion at the Bacillus Calmette-Guérin Vaccination Site

Barbara Gasior-Chrzan

Department of Dermatology, Tromsø University, Pb. 74, NO-9038 Tromsø, Norway. E-mail: barbara.gasior-chrzan@rito.no

Accepted May 11, 2001.

Sir,

Bacillus Calmette-Guérin (BCG) vaccine is an attenuated strain of *Mycobacterium bovis* that was developed from a more virulent strain in 1908 at the Pasteur Institute. It has been used in many parts of the world to enhance immunity to tuberculosis (1). The available strain in Norway is from the Statens Serum Institute, produced in Denmark, which is lyophilized and is constituted of sterile diluents (without aluminium hydroxide). In Norway, BCG vaccines are routinely given to all children aged 10–13 years, by intradermal or subcutaneous injection.

BCG vaccination provides 30–80% protection against the development of tuberculosis in susceptible and appropriate populations (2). The complications occurring after BCG vaccination for tuberculosis are rare in relation to the number of vaccinations carried out. They may be local or systemic, specific or non-specific reactions. The local changes are induration, blister formation, chronic-discharging ulcer, lupus vulgaris, and regional lymphadenopathy with or without suppurative drainage (3). The systemic reactions include erythema nodosum, erythema multiforme, generalized maculopapular eruption, exfoliative dermatitis, and papulonecrotic tuberculid (4).

We describe a peculiar post-BCG reaction that appeared as BCG granuloma 3 years after vaccination was performed.

#### CASE REPORT

A 16-year-old girl presented with a simple, firm, soft, painless nodule that appeared suddenly on the left upper arm in the sulcus over the insertion of the left deltoid muscle (Fig. 1), at the site of the previous BCG vaccination given intradermally 3 years earlier, under the school health services. The present lesion was approximately 3 cm in size, bluish, and surrounded by slightly inflamed skin. The draining lymphatic glands were not palpable. The patient's general health was good. There was no fever and weight loss. The laboratory examination was within the normal range (complete blood count, X-ray examination of the thorax, erythrocyte sedimentation rate and Pirque test). There was no past or family history of tuberculosis. The biopsy specimen of the nodule showed a granulomatous infiltrate consisting of epithelioid histiocytes, lymphocytes, and some Langerhans' giant cells. There was no caseation necrosis. A special stain for acid-fast bacilli, other bacilli and fungi was negative. Cultures of the biopsy specimen were negative at 8 weeks, and polymerase chain reaction (PCR)

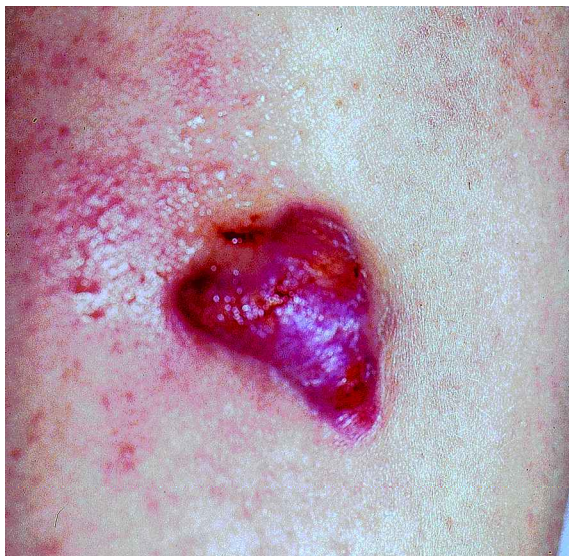

Fig. 1. The nodule (3 cm in size) on the left upper arm in the sulcus over the insertion of the left deltoid muscle.

studies were negative for mycobacteria. No antituberculous therapy was administered. Treatment with curettage was performed and the lesion healed within 3 weeks, without scarring. No recurrence was seen 2 years later.

## DISCUSSION

Cutaneous reactions to BCG have rarely been a problem and BCG is one of the safest vaccines in use. Each year in Norway ca. 52,000 schoolchildren are given BCG vaccinations. Of these, in 1999, ca. 0.03% complications were noted. These included 16 ulcerations, 5 abscesses, 2 adenitis and 2 keloids (5). Approximately 10–14 days after vaccination a small inflamed and infiltrated papule develops, which heals in 4–6 weeks. Sometimes the papule may slowly become enlarged and discharge purulent material, leaving a shallow ulcer that may last for months and is associated with a significant incidence of systemic BCG disease (4).

Vaccination can initiate keloid formation, which becomes evident several weeks following an injury, and the process may continue for months to years before spontaneous arrest occurs. Keloids are reported to be more common in tuberculin skin test reactors than in non-reactors. Although associated with the vaccination, they are not provoked by the BCG itself but by the trauma and they tend to occur particularly in certain ethnic groups (6). Early keloids have a rubbery consistency and may mimic hypertrophic scars. The distinction between the two is sometimes subtle, but, in general, keloids are larger and form over a longer period than hypertrophic scars. Microscopic examination reveals a fibroblastic response consisting of numerous fibroblasts, young collagen fibres and newly formed blood vessels that gradually decrease in late keloids, and the collagen shows sclerosis and hyalinization (7).

Clinically, the case presented here was suspected as being an abscess. The histopathological examination showed tuberculoid granuloma formation. BCG-induced granuloma is a rare complication of BCG vaccination. Our case is unique in that the lesion was localized to the left upper arm, exactly confined to the previous intracutaneous BCG vaccination site,

and did not involve other parts of the body. This localization strongly suggests a causal relationship between the BCG vaccination and the onset of this peculiar, cutaneous eruption. Because Ziehl stain, culture, and PCR mycobacterial DNA were negative, it seems that the present case represents a granulomatous reaction to proteins in the BCG vaccine and not true tuberculosis. However, the presence of tubercular bacilli has rarely been demonstrated in lesions by culture, or by DNA-PCR examination, in cases of true tuberculosis at the BCG vaccination site (8, 9).

Granulomatous reactions have been reported in cases of malignant melanoma (10–12) and other neoplasms (13) after BCG vaccine therapy, and during the course of Kawasaki disease (14). It has been postulated that molecule or molecules that are cross-reactive between suspected infectious agents and the mycobacterial BCG antigens may contribute to this inflammatory process (15).

Park et al. (16) reported lichen scrofulosorum-like eruptions localized to the previous multipuncture BCG vaccination site. The authors suspected that BCG vaccine antigens deposited in the skin together with the coexisting molluscum contagiosum in this patient could act as a trigger for a localized granulomatous reaction.

In the present case the BCG vaccination was not preceded by tuberculin skin testing or by any other vaccinations containing aluminium hydroxide used as the adsorbant, such as in diphtheria and tetanus vaccines, which may be a possible triggering factor for granulomatous formation.

The patient had not received any other vaccination at the same site, either shortly before the BCG or afterwards, at about the time of the appearance of the nodule. The triggering factor for the localized granulomatous reaction in our patient is therefore unknown. Although local persistent lesions are not so uncommon after a BCG vaccination, this case presents an unusually large lesion that appeared after a long latency period (3 years). Treatment with curettage was effective and antituberculous therapy was not needed. Most of the localized benign complications of BCG vaccination do not require medicament treatment, but if the lesion becomes particularly troublesome, then isoniazid may be considered.

## ACKNOWLEDGEMENT

The author thanks Dr. Leif Jørgensen, Department of Pathology, University of Tromsø, for kindly reviewing the biopsies.

## REFERENCES

1. Fine PEM. BCG vaccination against tuberculosis and leprosy. *Br Med Bull* 1988; 44: 691–703.
2. Eickhoff TC. The current status of BCG immunization against tuberculosis. *Annu Rev Med* 1977; 28: 411–423.
3. Dostrovsky A, Sagher F. Dermatological complications of BCG vaccination. *Br J Dermatol* 1963; 75: 181–192.
4. Moschella SL, Cropley TG. Bacillus Calmette-Guérin vaccine. In: Moschella SL, Hurley HJ, eds. *Dermatology*. Philadelphia: WB Saunders, 1992: 1082–1083.
5. <http://www.folkehelsa.no/nyhetsbrev/msis/2000/43/msis0043b.html>
6. Lotte A, Wasz-Höckert O, Poisson N, Dumitrescu N, Verron M, Couvet E. BCG complications. Estimates of the risks among vaccinated subjects and statistical analysis of their main characteristics. *Adv Tuberc Res* 1984; 21: 107–193.

7. Mancini RE, Quaife JV. Histogenesis of experimentally produced keloids. *J Invest Dermatol* 1962; 38: 143–181.
8. Renfro L, Miller D, Raszi L, Kamino H. Persistent plaque on the shoulder of a Chinese woman. BCG granuloma. *Arch Dermatol* 1993; 129: 231–236.
9. Misery L, Combemale P. BCG-vaccine-induced lupus vulgaris and urticarial vasculitis. *Dermatology* 1993; 186: 274.
10. Shea CR, Imber MJ, Cropely TG, Cosimi AB, Sober AJ. Granulomatous eruption after BCG vaccine immunotherapy for malignant melanoma. *J Am Acad Dermatol* 1989; 21: 1119–1122.
11. Jaffrey IS. Systemic epithelioid granulomata following immunotherapy with methanol extracted residue of bacillus Calmette-Guérin. *Cancer Treat Rep* 1978; 62: 573.
12. Rosenberg SA, Seipp C, Sears HF. Clinical and immunologic studies of disseminated BCG infection. *Cancer* 1978; 41: 1771–1780.
13. Magnon R, DeVillez RL. Disseminated cutaneous granulomas from BCG therapy. *Arch Dermatol* 1980; 116: 355.
14. Kuniyuki S, Asada M. An ulcerated lesion at the BCG vaccination site during the course of Kawasaki disease. *J Am Acad Dermatol* 1997; 37: 303–304.
15. Yokota S, Tsubaki K, Kuriyama T, Shimizu H, Ibe M, Mitsuda T, et al. Presence in Kawasaki disease of antibodies to mycobacterial heatshock protein HSP65 and autoantibodies to epitopes of human HSP65 cognate antigen. *Clin Immunol Immunopathol* 1993; 67: 163–170.
16. Park YM, Kang H, Cho SH, Cho BK. Lichen scrofulosorum-like eruption localized to multipuncture BCG vaccination site. *J Am Acad Dermatol* 1999; 41: 262–264.

## Ketoprofen-induced Pemphigus-like Dermatitis: Localized Contact Pemphigus?

Jean Kanitakis, Anne-Laure Souillet, Michel Faure and Alain Claudy

Department of Dermatology, Hôp. Ed. Herriot (Pav. R), FR-69437 Lyon Cédex 03, France. E-mail: kanitak@lyon151.inserm.fr

Accepted April 10, 2001.

Sir,

Ketoprofen is a non-steroidal anti-inflammatory drug, belonging to the group of arylpropionic derivatives, which is widely used per os and by cutaneous application as a 2.5% gel. Side-effects after oral administration mainly relate to the gastrointestinal tract and affect up to 15.3% of patients (1). Cutaneous side-effects secondary to local application are much rarer, with an estimated frequency ranging from 0.008% to 0.023% (2), depending on the commercial preparation. These consist mainly of contact dermatitis (3–6) and photocontact dermatitis (7–9), which may be persistent (10). We present herein a patient who developed a vesiculobullous dermatosis at the site of application of ketoprofen, with histologic and immunopathologic features of autoimmune pemphigus. As far as we know, contact pemphigus has never been reported before with ketoprofen.

### CASE REPORT

A 65-year-old Caucasian woman had been suffering from Waldenström's macroglobulinemia and was treated with

fludarabine. Some days prior to consultation she had applied ketoprofen gel (Ketum) on her knees on two occasions to relieve arthralgia. Within a matter of hours she developed pruritic, well-demarcated, erythematous lesions over both knees, which later became studded with vesicles and small bullae (Fig. 1). On examination an additional erythematous lesion was found on the thigh. The mucous membranes were unaffected. The vesicles and bullae subsided as a result of local steroid treatment but the erythema persisted on the knees for the next 10 days. Histologic examination of a skin lesion showed a moderately acanthotic epidermis. Several deeply-seated intraepidermal vesicles were found, whose floor consisted of a single row of basal keratinocytes. The vesicles were occasionally coalescing into small blisters and contained many eosinophils (Fig. 2). The underlying dermis contained a mild inflammatory infiltrate composed of lymphocytes and eosinophils. Direct immunofluorescence performed twice on perilesional skin (at the initial consultation and 10 days later) showed deposits of IgG and C3 on the surface of epidermal keratinocytes, i.e. an aspect of autoimmune pemphigus.

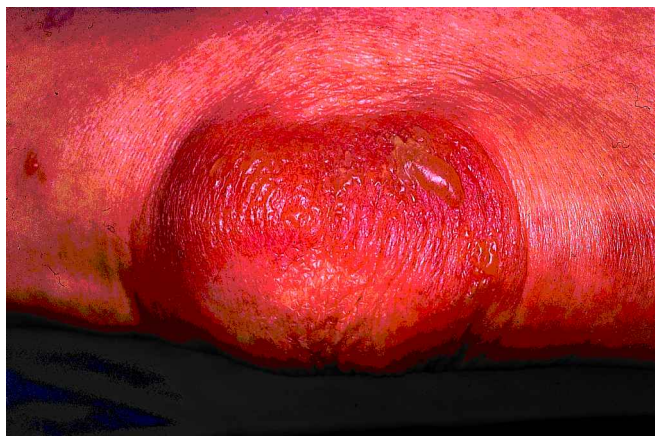

Fig. 1. Well-demarcated erythematous lesion of the knee studded with vesicles and small bullae.

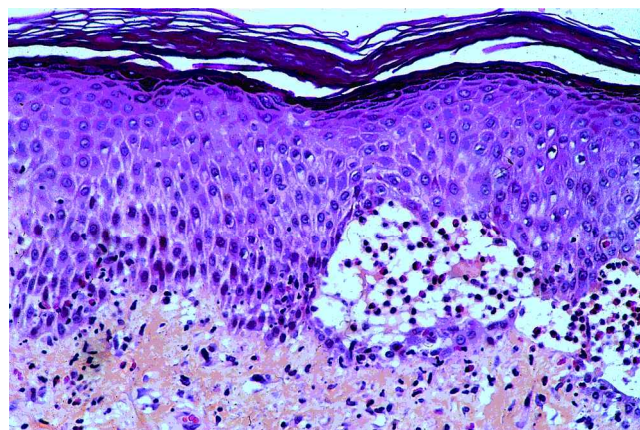


Fig. 2. Suprabasal intraepidermal clefting containing many eosinophils. Original magnification  $\times 250$ .