

## LETTERS TO THE EDITOR

### Topical Imiquimod Treatment of Human Papillomavirus in a Patient with Human Immunodeficiency Virus

Jeffrey Gilbert<sup>1</sup>, Molly M. Drehs<sup>2</sup> and Jeffrey M. Weinberg<sup>2\*</sup>

<sup>1</sup>STD Center for Excellence, Montefiore Medical Center, Bronx, New York, USA and <sup>2</sup>Department of Dermatology, St. Luke's–Roosevelt Hospital Center, 1090 Amsterdam Avenue, Suite 11D, New York, NY 10025, USA. \*E-mail:

jwein@bway.net

Accepted April 9, 2001.

Sir,

Multiple multicenter, prospective, randomized, double-blind, placebo-controlled studies have shown the effectiveness of topical imiquimod 5% cream, an immune response modifier, for the treatment of anogenital warts in otherwise healthy individuals (1–3). Analysis of wart skin biopsies has been conducted to determine the molecular mechanisms contributing to the effectiveness of imiquimod (4,5). These studies indicated that imiquimod increases the local production of multiple interferon mRNAs, including interferon-alpha, interferon-gamma, interleukin-12 and tumor necrosis factor-alpha. Increases in CD4 mRNA were also seen, suggesting an activation of the cell-mediated immune response. Furthermore, it was seen that imiquimod decreases the local viral load and human papillomavirus (HPV) DNA and mRNA for HPV proteins.

Because the mechanism of the effectiveness of imiquimod seems to be directly related to its local upregulation of the immune response, it was previously questionable as to whether imiquimod would be effective in the setting of immunosuppression, as is seen in human immunodeficiency virus (HIV)-positive patients. It has been determined that the pathogenesis of HPV in HIV-infected individuals is different, either directly through interactions between viral proteins or indirectly through altered immune functions (6, 7). HIV is thought to influence the expression of HPV genes, resulting in local immune suppression leading ultimately to decreased immune surveillance of viral infection. Consequently, HIV would be expected to directly oppose the action of imiquimod. We describe here successful treatment of HPV with imiquimod in a patient with HIV, and discuss the literature regarding treatment with imiquimod in this population.

#### CASE REPORT

A 28-year-old black man presented with the chief complaint of anal pain over the course of the previous 3 weeks. He was diagnosed with anal HPV (Fig. 1). At the same time, the patient was tested for HIV and was found to be positive. His CD4 count at that time was 100 cells/mm<sup>3</sup>, and his viral load was > 750,000. He was started on topical imiquimod 5% cream three times per week. After 8 weeks, treatment resulted in total clinical clearance of the warts (Fig. 2).

#### DISCUSSION

Gilson et al. (8) reported a study conducted in HIV-positive patients to assess the efficacy and safety of topical imiquimod for HPV infection in these individuals. It was concluded that there may indeed be some clinical utility of imiquimod in these

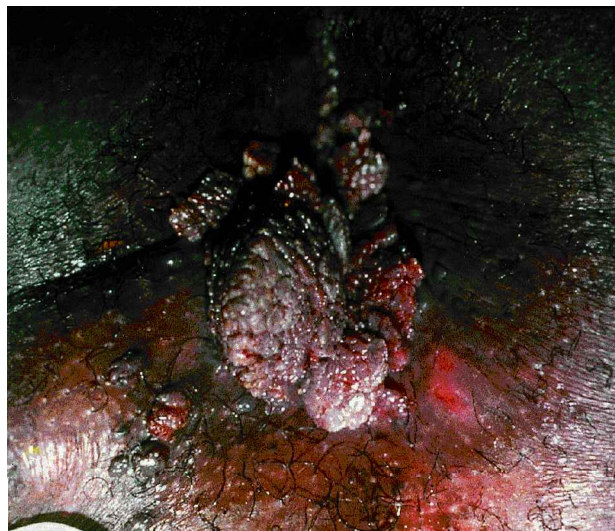

Fig. 1. Perianal condyloma prior to treatment.

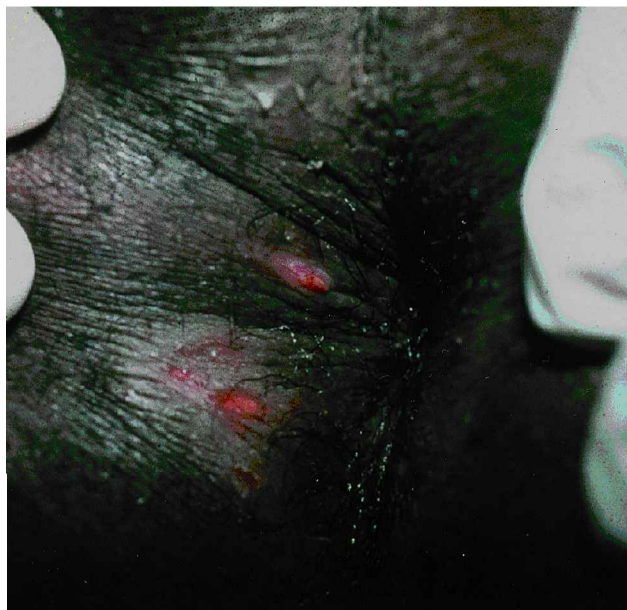


Fig. 2. Clearance of lesions after 8 weeks of therapy.

patients, with some patients experiencing total clearance and many showing a significant decrease in total wart area. While there was no significant difference between treatment groups in terms of the number of patients who totally cleared their

baseline warts (imiquimod 11% vs. vehicle 6%;  $p=0.488$ ), more imiquimod-treated patients experienced a  $\geq 50\%$  reduction in baseline wart area (38% vs. 14%;  $p=0.013$ ). Use of imiquimod was not associated with any changes in laboratory values, including CD4 count. It was not associated with any adverse drug-related events, and no exacerbation of HIV/AIDS was attributed to the use of imiquimod. However, it appeared that topical imiquimod was still less effective at achieving total clearance than in the studies with HIV-negative patients, which is most likely a reflection of the impaired cell-mediated immunity seen in the HIV-positive population (8).

There has also been a report of improved success when topical imiquimod was combined with more traditional destructive therapy for HPV infection in HIV-positive patients, particularly in the setting of the use of highly-active antiretroviral therapy (HAART) (9). This combination therapy appears to be increasingly more effective as viral load drops and CD4 count rises.

We believe that the case presented, particularly in the context of the studies already conducted, supports the utility of topical imiquimod for the treatment of anogenital HPV in HIV-positive individuals. Further investigation is warranted to determine the most effective regimen for its use, including the possibility of combined therapies and/or concomitant initiation of HAART.

#### REFERENCES

1. Edwards L, Ferenczy A, Eron L. Self-administered topical 5% imiquimod cream for external anogenital warts. *Arch Dermatol* 1998; 134: 25–30.
2. Buetner KR, Spruance SL, Hougham AJ, Fox TL, Owens ML, Douglas JM Jr. Treatment of genital warts with an immune-response modifier (imiquimod). *J Am Acad Dermatol* 1998; 32: 230–239.
3. Beutner KR, Tyring SK, Trofatter KF, Douglas JM, Spruance S, Owens ML, et al. Imiquimod, a patient-applied immune-response modifier for treatment of external genital warts. *Antimicrob Agents Chemother* 1998; 42: 789–794.
4. Tyring SK, Arany I, Stanley MA, Tomai MA, Miller RL, Smith MH, et al. A randomized, controlled, molecular study of condylomata acuminata clearance during treatment with imiquimod. *J Infect Dis* 1998; 178: 551–555.
5. Arany I, Tyring SK, Stanley MA, Tomai MA, Miller RL, Smith MH, et al. Enhancement of the innate and cellular immune response in patients with genital warts treated with topical imiquimod cream 5%. *Antiviral Res* 1999; 43: 55–63.
6. Arany I, Tyring SK. Systemic immunosuppression by HIV infection influences HPV transcription and thus local immune responses in condyloma acuminatum. *Int J STD AIDS* 1998; 9: 268–271.
7. Arany I, Evans T, Tyring SK. Tissue specific HPV expression and downregulation of local immune responses in condylomas from HIV seropositive individuals. *Sex Transm Infect* 1998; 74: 349–353.
8. Gilson RJ, Shupack JL, Friedman-Kien AE, Conant MA, Weber JN, Nayagam AT, et al. A randomized, controlled, safety study using imiquimod for the topical treatment of anogenital warts in HIV-infected patients. Imiquimod Study Group. *AIDS* 1999; 13: 2397–2404.
9. Conant MA. Immunomodulatory therapy in the management of viral infections in patients with HIV infection. *J Am Acad Dermatol* 2000; 43: S27–30.

## Delayed Granulomatous Lesion at the Bacillus Calmette-Guérin Vaccination Site

Barbara Gasior-Chrzan

Department of Dermatology, Tromsø University, Pb. 74, NO-9038 Tromsø, Norway. E-mail: barbara.gasior-chrzan@rito.no

Accepted May 11, 2001.

Sir,

Bacillus Calmette-Guérin (BCG) vaccine is an attenuated strain of *Mycobacterium bovis* that was developed from a more virulent strain in 1908 at the Pasteur Institute. It has been used in many parts of the world to enhance immunity to tuberculosis (1). The available strain in Norway is from the Statens Serum Institute, produced in Denmark, which is lyophilized and is constituted of sterile diluents (without aluminium hydroxide). In Norway, BCG vaccines are routinely given to all children aged 10–13 years, by intradermal or subcutaneous injection.

BCG vaccination provides 30–80% protection against the development of tuberculosis in susceptible and appropriate populations (2). The complications occurring after BCG vaccination for tuberculosis are rare in relation to the number of vaccinations carried out. They may be local or systemic, specific or non-specific reactions. The local changes are induration, blister formation, chronic-discharging ulcer, lupus vulgaris, and regional lymphadenopathy with or without suppurative drainage (3). The systemic reactions include erythema nodosum, erythema multiforme, generalized maculopapular eruption, exfoliative dermatitis, and papulonecrotic tuberculid (4).

We describe a peculiar post-BCG reaction that appeared as BCG granuloma 3 years after vaccination was performed.

#### CASE REPORT

A 16-year-old girl presented with a simple, firm, soft, painless nodule that appeared suddenly on the left upper arm in the sulcus over the insertion of the left deltoid muscle (Fig. 1), at the site of the previous BCG vaccination given intradermally 3 years earlier, under the school health services. The present lesion was approximately 3 cm in size, bluish, and surrounded by slightly inflamed skin. The draining lymphatic glands were not palpable. The patient's general health was good. There was no fever and weight loss. The laboratory examination was within the normal range (complete blood count, X-ray examination of the thorax, erythrocyte sedimentation rate and Pirque test). There was no past or family history of tuberculosis. The biopsy specimen of the nodule showed a granulomatous infiltrate consisting of epithelioid histiocytes, lymphocytes, and some Langerhans' giant cells. There was no caseation necrosis. A special stain for acid-fast bacilli, other bacilli and fungi was negative. Cultures of the biopsy specimen were negative at 8 weeks, and polymerase chain reaction (PCR)