

Multiple Paraneoplasia in the Absence of a Detectable Tumour

Sir,

Acanthosis nigricans maligna comprises paraneoplastic skin symptoms, which usually indicate malignancy, primarily gastric or oesophageal cancer. We describe here a patient who is free of any detectable tumour 3 years after the onset of different paraneoplastic syndromes.

CASE REPORT

A 53-year-old Pakistani woman, the mother of 5 children, presented darkening of the skin. She had a body mass index of 30.11, no history of drug abuse or medicine intake, and no family history of diseases or medical prehistory, except for a hysterectomy performed because of proven endometriosis and polycystic ovaria. About 2 months before her hysterectomy she noticed the first signs of acanthosis on her gingiva. The gingiva was hypertrophic with multiple aggregated papules. About the same time the skin of her palms and soles began to change, to feel rougher and, finally, to display "tripe palms" (Fig. 1). One month later her skin in the axillae, genitofemoral region and elbows began to darken and to show a rough, verrucous, dark black tanned surface (Fig. 2). In addition, both cheeks showed hypertrichosis lanuginosa acquisita and multiple verrucae filiformes spreading over her body were found. Furthermore, she reported a diffuse loss of hair and at the time of examination displayed alopecia with scar formation and signs of perifolliculitis decalvans. There was a remarkable cutis verticis gyrata on the back of her head and on her forehead. The diagnosis of acanthosis nigricans maligna was proven histopathologically.

As a result, we started a thorough search for tumours including tumour markers and a slight elevation of neuron specific enolase was found (7.4 ng/ml; normal < 5 ng/ml). A temporary increase in serum cortisol occurred, which may have resulted from her intake of oestrogen after the hysterectomy, and thyroid-stimulating hormone levels were raised. This was checked using a thyrotropin-releasing hormone test, and turned out to be within the normal range. The cortisone-releasing test was also within the normal range. The only laboratory abnormality found during the 3-year follow-up period was hyperinsulinism as an indication of insulin resistance. The elevated cortisol was also further investigated by an X-ray of the sellar region, but no abnormalities were found. During the past 3 years the patient has been repeatedly assessed using computer tomography, magnetic resonance tomography, positive emission tomography, sonography of the abdominal region and lymph nodes, gastroscopy, colonoscopy and X-rays, but no abnormalities or signs of a tumour have been detected.

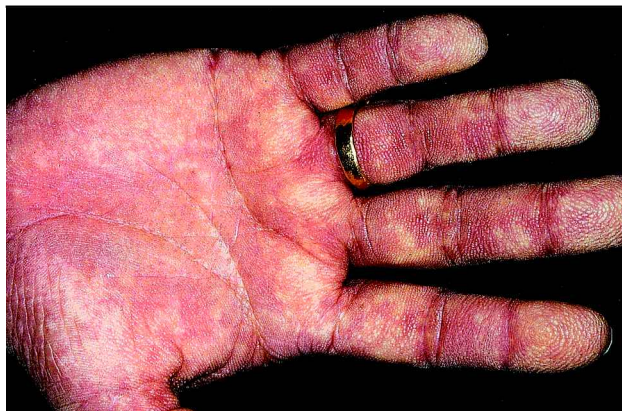

Fig. 1. "Tripe palms" with well-demarcated hyperkeratosis and accentuation of the normal skin markings on the palm.

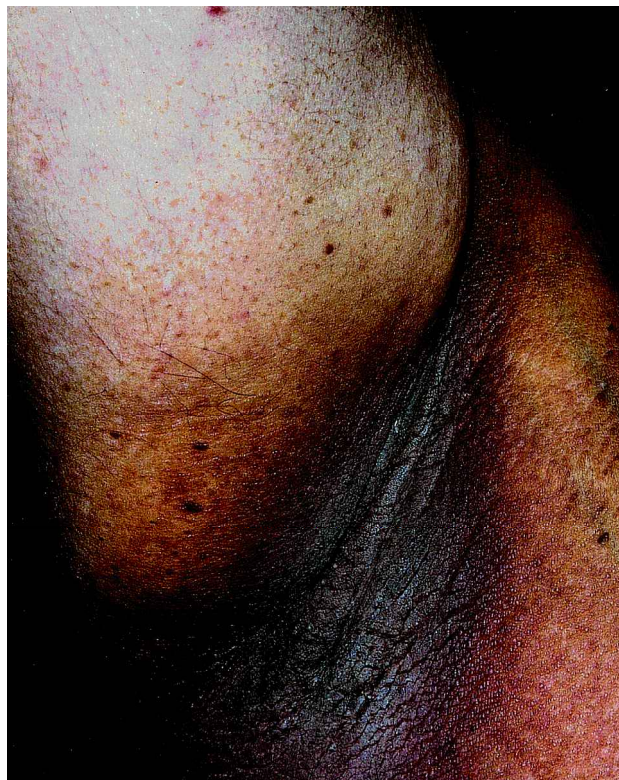


Fig. 2. Skin manifestations of malignant acanthosis nigricans in the axillary region with dark, hyperpigmented, hyperkeratotic skin.

DISCUSSION

Acanthosis nigricans maligna is well known as paraneoplasia (1, 2) and recently it has also been recognized as a marker for systemic disorders associated with insulin resistance (3). Acanthosis nigricans is also found in association with obesity; the prevalence was 66% in adolescents who weighed more than 200% of their ideal body weight (4). Acanthosis nigricans, associated with malignant cancer, occurs in about one-third of cases with gastric cancer, in another third with abdominal tumours and in 10% with extra-abdominal tumours. The incidence of acanthosis nigricans maligna is about 1:10,000, with a predominance in females (5). The disease is characterized by the symmetrical eruption of hyperpigmentation and papillomatosis in the axillae, sides of the neck, antecubital, periumbilical and popliteal surfaces. The oral mucosa may be significantly involved. In our case this was the earliest symptom, when the gingiva began to become hypertrophic. Subsequently, both the hands and soles showed lichenification and hyperkeratosis. This phenomenon is called "tripe palms" (6–9). The acanthosis nigricans maligna can occur either after or up to 18 years before the manifestation of the malignancy (5) and, therefore, tumour staging is essential. Histologically, the skin lesions show hyperkeratosis, papillomatosis and acanthosis.

Besides the acanthosis nigricans maligna our patient showed prominent hypertrichosis on both cheeks. She reported that this had not been the case in the previous years, so it was also

presumed to be a paraneoplasia, a “hypertrichosis lanuginosa acquisita”. With this very rare paraneoplasia, the hair remains in the anaphase for longer than usual. The pathomechanism is unknown, but the hypertrichosis usually occurs at those locations where lanugo hair is apparent in adults. In females the hairs grow on the face, ears, neck and body, whereas in males they are located on the eyelids, forehead, elbows, knees and backs of the feet. Cases have been reported with total hypertrichosis of the integument. This paraneoplasia is associated with gastric and intra-abdominal cancer and the laboratory assessments are in the normal range. Association with acanthosis nigricans maligna has been occasionally reported (10, 11). Furthermore, in our patient there were multiple verrucae filiformes; these are not paraneoplasias, but a sudden eruption of multiple verrucae is often seen in patients with immunodeficiency.

Cutis verticis gyrata as a paraneoplasia is associated with lung cancer as well as with gastric and oesophagus cancers. This disease is indicated by a hypertrophy of the periost and a resulting exostosis, as well as thickened skin, and is best recognized on the face and head but also on the hands and feet. Our patient exhibited cutis verticis gyrata on her forehead as well as on her neck. Moreover, loss of hair (as in our case) is associated with cutis verticis gyrata and gynaecomastia and elevated serum oestrogen levels are occasionally observed. She also presented a perifolliculitis decalvans with scar formation, which is not typical for cutis verticis gyrata and has not been reported as being a paraneoplasia. However, both cutis verticis gyrata and loss of hair have been reported as symptoms of acanthosis nigricans maligna (12).

Our patient now only complains of diffuse hair loss and gingivitis. The pigmentation of acanthosis nigricans maligna is still present without regression and repeated examinations have not shown any accompanying tumour. The pathologist who investigated the organs removed by hysterectomy was interviewed carefully. He stated that the removed organs were tumour-free; all of the removed organs had been inspected macroscopically and the ovaries and most of the uterus microscopically. All parameters assessed, with the exception of the elevated tumour marker and the hyperinsulinism, were

normal. However, follow-up at short, regular intervals is necessary as the development of a tumour must be expected.

REFERENCES

1. Pollitzer S. Acanthosis nigricans. In: Unna PG, Morris M, Besnier E, et al. eds. International atlas of rare skin diseases. London: HK Lewis & Co., 1890; Chap. 10: 1–3.
2. Schwartz RA. Acanthosis nigricans. *J Am Acad Dermatol* 1994; 31: 1–19.
3. Kahn CR, Flier JS, Bar RS, Archer JA, Gorden P, Martin MM, et al. The syndromes of insulin resistance and acanthosis nigricans: insulin-receptor disorders in man. *N Engl J Med* 1976; 294: 739–745.
4. Hud JA Jr, Cohen JB, Wagner JM, Cruz PD. Prevalence and significance of acanthosis nigricans in an adult obese population. *Arch Dermatol* 1992; 128: 941–944.
5. Herzberg J. Cutane paraneoplastische Syndrome der Haut, Beiträge zur Dermatologie, Band 5. Perimed Verlag, 1980.
6. Breathnach SM, Wells GC. Acanthosis palmaris. Tripe palms: a distinctive pattern of palmar keratoderma frequently associated with internal malignancy. *Clin Exp Dermatol* 1980; 5: 181–189.
7. Lo WL, Wong CK. Tripe palms: a significant cutaneous sign of internal malignancy. *Dermatology* 1992; 185: 151–153.
8. Cohen PR, Grossman ME, Almeida L, Kurzrock R. Tripel palms and malignancy. *J Clin Oncol* 1989; 7: 669–678.
9. Mullans EA, Cohen PR. Tripe palms: a cutaneous paraneoplastic syndrome. *South Med J* 1996; 89: 626–627.
10. Dingley ER, Marten RH. Adenocarcinoma of the ovary presenting as acanthosis nigricans. *J Obstet Gynaecol Br Emp* 1957; 64: 898–900.
11. Farina MC, Tarin N, Grilli R, Soriano ML, Sarasa JL, Martin L, Requena L. Acquired hypertrichosis lanuginosa: case report and review of the literature. *J Surg Oncol* 1998; 68: 199–203.
12. Azizi E, Trau H, Schewach-Millet M, Rosenberg V, Schneebaum S, Michalevicz R. Generalized malignant acanthosis nigricans. *Arch Dermatol* 1980; 116: 381.

Accepted February 5, 2001

Astrid E. Steen, Kay H. Steen* and Thomas Bieber
 Department of Dermatology, University of Bonn, Sigmund-Freud-Str. 25, D-53105 Bonn, Germany.
 *E-mail: khsteen@ukb.uni-bonn.de