

## CLINICAL REPORT

# Relationship Between Season and Diagnoses of Melanocytic Tumours

MICHAEL TRONNIER and CHRISTIAN MÜLLER

*Department of Dermatology, Medical University of Lübeck, Germany*

**The frequency of various diagnoses of pigmented lesions, their distribution on various body sites and the seasonal variations in their diagnoses were studied according to the specimen of pigmented lesions sent to a laboratory for histopathological examination. From the total number of 18,402 investigated lesions, 7,682 were excised from males and 10,720 from females. Melanoma was diagnosed in 2.5% of all excised tumours more often during the summer months. Lighter clothing and greater awareness during summer may explain this finding. Additional factors such as a sun-induced melanocytic activation in naevi cannot be ruled out. Dysplastic naevi, which represented 26% of all naevi in this study, were excised less often during summer. Presuming that the majority of the north German population acquires the highest ultraviolet (UV) doses of the year during summer, it seems unlikely that the histological features of dysplasia in naevi are related to short-term UV activation. The localization of dysplastic naevi did not correspond to the body-site distribution of melanoma according to sex. This finding does not indicate the dysplastic naevus as a possible precursor lesion of malignant melanoma. Key words: dysplasia; naevus; melanoma; body site; sex.**

(Accepted January 10, 2001.)

Acta Derm Venereol 2001; 81: 112–115

Professor Dr Michael Tronnier, Department of Dermatology, Medical University of Lübeck, Ratzeburger Allee 160, D-23538 Lübeck, Germany. E-mail: tronnier@medinf.mu-luebeck.de

Sunlight has been reported to represent an important factor in the pathogenesis of malignant melanoma (1–3). The site distribution of malignant melanoma and information on sunburn suggest that intermittent, short-duration ultraviolet (UV) light exposure is more important for the development of melanoma than chronic sun exposure, which is thought to be the major factor in epithelial skin cancer (4). The number of melanocytic naevi on an individual seems to be influenced by UV radiation, at least in part. Higher counts of melanocytic naevi have been found on sun-exposed skin than on sun-protected areas (5), and the presence of a high number of naevi correlates with the history of intensive sun exposure and sunburn (6). For malignant melanoma an increase in the frequency of diagnosis during summer has been described by several authors (7–9).

Possible reasons for this finding include a direct influence of the increased UV radiation in summer on melanoma development, and a change in clothing habits during the summer months, resulting in an increased detection rate. Holman *et al.* found a junctional component and signs of inflammation more often in naevi excised in summer than in those excised in winter (10). More mitotic figures were

observed by Larsen *et al.* in naevi excised in summer than in those excised in winter (11). Both groups suggested that UV light also has a short-term promotional effect on melanocytes in melanocytic naevi. A direct comparison of one part of the naevus which has been UV-irradiated with another non-irradiated part of the same naevus showed that a single erythemogenic dose of UVB light is able to induce morphological changes simulating the presence of melanoma (12). Further studies demonstrated that the activation of melanocytes is reversible after a few weeks (13).

The aim of the present study was to investigate the frequency of various diagnoses of melanocytic tumour excised from patients in one region of Germany in relation to the season with regard to additional information on sex and body-site distribution.

## MATERIAL AND METHODS

### *Cases and diagnoses*

This study included patients who underwent excision of 1–6 melanocytic naevi, from all cases examined in the dermatohistological laboratory of the Department of Dermatology, University of Lübeck, during the years 1993–1995. This material included excision material from the department as well as specimens sent to the department for histopathological examination after excision in private offices located exclusively in northern Germany. The slides were examined by 5 colleagues experienced in the field of dermatopathology, who had the same scientific background and had gained the same dermatopathology training in this department.

A total number of reports from 18,402 melanocytic lesions was studied: 7,682 (42%) lesions were excised from male and 10,720 (58%) from female patients. The mean age was  $35 \pm 13$  years for women and  $36 \pm 15$  years for men.

From all diagnoses the following diagnoses were selected for the study: melanocytic naevus, junctional type; melanocytic naevus, dermal type; melanocytic naevus, compound type; dysplastic naevus, junctional type; dysplastic naevus, compound type; malignant melanoma; and Spitz's naevus. Note that the authors were aware of the difficulties in defining clearly the morphological characteristics of dysplastic naevi. The dysplastic naevi were considered to represent benign melanocytic lesions. Criteria for the diagnosis of a dysplastic naevus were architectural disorder and some nuclear pleiomorphism.

Body areas were summarized in the following groups: head and neck, trunk, upper extremities, lower extremities, and other sites.

Summer months were considered to be June, July, August and September, and winter months were November, December, January and February.

### *Statistical evaluation*

The  $\chi^2$ -test after Pearson was performed.  $p < 0.05$  was regarded as a significant difference.

## RESULTS

From all specimens sent to the laboratory in 1993, 38%, and in 1994 and 1995, 35% represented melanocytic tumours; 58% of all excised melanocytic tumours were excised from female patients and 42% from male patients. Melanocytic naevi were most often excised in patients between 20 and 40 years of age. Most of the melanoma cases were in the age group of 50–60 years (2%).

The seasonal variations in the diagnoses are summarized in Fig. 1. Of all excised melanocytic tumours sent to the laboratory for histological examination, 2.5% were diagnosed as malignant melanoma. In the years 1993–1995 melanomas were more often excised during the summer months (187; 40.7%) than during the winter months (149; 32.5%).

Twenty-six per cent of all melanocytic naevi (1993–1995) were diagnosed as dysplastic naevi. During the winter months more dysplastic naevi of both junctional and compound type

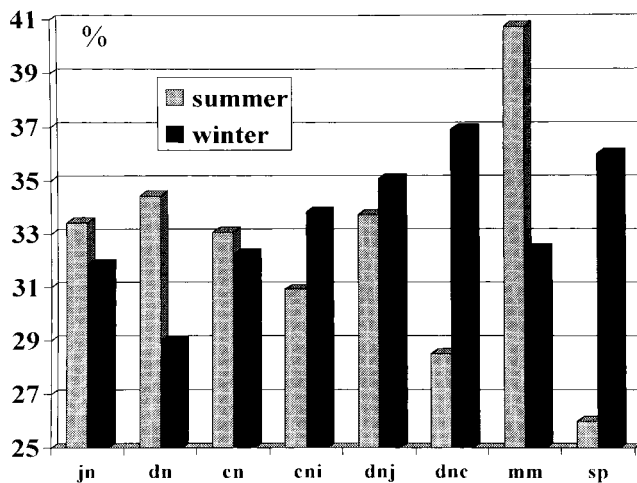


Fig. 1. Seasonal variation in the diagnosis of melanocytic tumours. The frequency of diagnosis is shown as a percentage of all excised tumours over the year. Mean values are given from the years 1993–1995. Summer months: June, July, August, September; winter months: November, December, January, February. jn: junctional naevus; dn: dermal naevus; cn: compound naevus; cni: compound naevus with signs of inflammation; dnj: dysplastic naevus, junctional type; dnc: dysplastic naevus, compound type; mm: malignant melanoma; sp: Spitz's naevus.

Table I. Body-site distribution of various melanocytic lesions

	Head		Trunk			Upper extremities			Lower extremities			Other	Total	
	M	F	Total	M	F	Total	M	F	Total	M	F			Total
Dermal naevus			726			465			147			196	26	1,560
Junctional naevus			24	352	416	768			282	317	516	833	9	1,916
Compound naevus			157	1,619	1,905	3,524			700	783	1,112	1,895	79	6,355
Dysplastic naevus junct.			21	399	362	761			208	229	434	663	13	1,666
Dysplastic naevus comp.			60	986	912	1,898			279	437	325	762	40	3,039
Melanoma	41	59	100	93	52	145	21	49	70	32	108	140	4	459
Total			1,088			7,561			1,686			4,489	171	14,995

M: male; F: female.

were excised. Spitz's naevi were more often found during the winter months, but the total number was small.

No clear correlation between the season of excision and other diagnoses of melanocytic naevi was found.

Statistically, the seasonal distribution of all diagnoses of melanocytic tumours was not random in male patients for 1993–1995 (1993:  $p=0.002$ ; 1994:  $p<0.0001$ ; 1995:  $p=0.038$ ). For females significance was seen in 1993 and 1995 (1993:  $p=0.026$ ; 1995:  $p=0.016$ ), but not in 1994 ( $p=0.059$ ).

Dermal naevi were most often located in the body area of the head and neck. Junctional and compound naevi, of the common as well as the dysplastic type, were most often excised from the trunk and lower extremities (Table I).

When the distribution according to sex for a single diagnosis in a single location was adjusted to the total sex distribution of the excised material (male 42%, female 58%), the following observations were made.

In male patients a relatively high number of junctional and compound naevi of normal and dysplastic type was located on the trunk compared with female patients. Malignant melanomas in male patients were most often located on the trunk.

In female patients a relatively high number of junctional and compound naevi was found on the lower extremities. Dysplastic naevi of junctional type were more often located on the lower extremities in women, but compound dysplastic naevi on the lower extremities were much more often diagnosed in male patients. Malignant melanomas in female patients were most often located on the lower extremities.

There was a seasonal variation in the number of specimens received by the laboratory, with a decrease in total number in April (Easter holiday), in July and August (summer holiday) and in December (Christmas holiday) (Fig. 2).

## DISCUSSION

A higher number of excised melanocytic tumours was found in females (10,720) than in males (7,682) in this study. This may reflect the greater awareness of female patients (14). Counts of the total number of naevi are different between the sexes, with most studies describing a higher number in male individuals (15). Moles are not distributed evenly over the body areas. Irrespective of the number per surface area, the trunk and lower extremities are the sites where most melanocytic naevi are located (16). In total, the trunk was the site

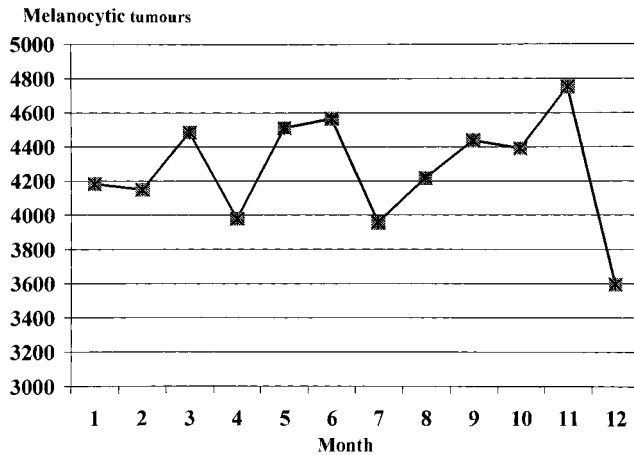


Fig. 2. Mean of total number of specimens received for histopathological examination at different times of the year. There is a decrease in number during holiday periods in northern Germany: Easter (4), summer (7) and Christmas (12).

from which the most lesions were excised. Dermal naevi were most often located in the face and neck.

The distribution of melanoma according to sex was as reported in the literature, with the trunk being the most frequent location in males and the lower extremities in females (17). The sex differences in anatomical site distribution are consistent with intermittent exposure of susceptible skin to the sun (2). In a study by Bell *et al.* (18) 42.6% of all melanomas in female patients were located on the lower extremities (26.3% lower leg). They described a decrease in frequency of melanoma on the lower leg in female patients (1966–1976 vs 1977–1987) according to fashionable clothing. In the present study, however, 39.7% of the female melanoma cases came from the lower extremities. With increasing age an increase in melanoma in chronically sun-exposed skin can be observed, e.g. on the ear or face, especially if the incidence is adjusted to the surface area of the body site (4, 16).

The localization of dysplastic naevi in this study did not completely correspond to the distribution pattern of melanoma and therefore did not support the hypothesis that dysplastic naevi may be precursors of melanoma. The slight male predominance of dysplastic naevi excised from the trunk does not correlate with the clear predominance of melanoma cases from the trunk in males. Whereas many more junctional dysplastic naevi were excised from the lower extremities in females, the opposite was found for compound dysplastic naevi.

Seasonal variations in the frequency of the diagnosis of melanoma, with an increased diagnosis during the summer months as seen in this study, is well documented in the literature (7–9). Schwartz *et al.* suggested that sunlight may play a promotional role in the development of melanoma, possibly from pre-existing naevi (7). Experimental exposure of melanocytic naevi to UV light results in morphological changes simulating the presence of melanoma, changes which have been found to be reversible (13). It is possible that in very rare cases this activational status of the naevus persists and subsequently leads to a malignant transformation of the melanocytes. So far, the time taken to complete each step of carcinogenesis is completely unknown. Therefore, the seasonal increase in melanoma during summer must be interpreted with

caution. In addition, it cannot be ruled out with certainty that some UV-activated melanocytic naevi were misinterpreted as malignant melanomas.

Blum *et al.* suggested that the higher detection rate of melanoma during summer months is due to clothing habits, because of the easier detection of suspicious pigmented tumours (8). In addition, public-health campaigns are usually performed in the summer, leading to greater awareness by the patients (8). Theobald *et al.* (19) reported an increase of 167% in diagnosed melanoma following a 60-min television programme shown during peak viewing time about the fate of a young male melanoma patient.

It is unclear why dysplastic naevi were more often excised during the winter season, a finding particularly observed for compound dysplastic naevi. Clinically atypical naevi which turned out to be dysplastic naevi on histology should also be detected more easily in the summer months if lighter clothing is of importance. However, histological dysplasia may correlate poorly with the clinical phenotype (20). In favour of a summer peak in dysplastic naevi would also have been that the morphological changes in a possible short-term activation of melanocytic naevi by sunlight during the summer may be interpreted as “dysplasia”. The present findings make a possible role of sunlight in the development of “dysplasia” in melanocytic naevi unlikely, at least in a short-term pathway. Stierner *et al.* (21), in a case-control study, found a body-site distribution of dysplastic naevi which did not support a significant role of sunlight in the pathogenesis of dysplastic naevi.

It should be taken into account that the total number of excisions of melanocytic tumours during a certain season influences the frequency of a single diagnosis (e.g. during holiday periods). Other factors such as sunbed usage and recreational sun exposure during the winter months may also have influenced the results.

## REFERENCES

1. Kopf AW, Kripke ML, Stern RS. Sun and malignant melanoma. *J Am Acad Dermatol* 1984; 11: 674–684.
2. Elder DE. Human melanocytic neoplasms and their relationship with sunlight. *J Invest Dermatol* 1989; 92 Suppl: 297–303.
3. Elwood JM. Melanoma and ultraviolet radiation. *Clin Dermatol* 1992; 10: 41–50.
4. Franceschi S, Levi F, Randimbison L, La Vecchia C. Site distribution of different types of skin cancer: new aetiological clues. *Int J Cancer* 1996; 67: 24–28.
5. Augustsson A, Stierner U, Rosdahl I, Suurkula M. Melanocytic naevi in sun-exposed and protected skin in melanoma patients and controls. *Acta Derm Venereol* 1991; 71: 512–517.
6. Harrison SL, MacLennan R, Speare R, Wronski I. Sun exposure and melanocytic naevi in young Australian children. *Lancet* 1994; 344: 1529–1532.
7. Schwartz SM, Armstrong BK, Weiss NS. Seasonal variation in the incidence of cutaneous malignant melanoma: an analysis by body site and histologic type. *Am J Epidemiol* 1987; 126: 104–111.
8. Blum A, Ellwanger, Grabe C. Seasonal patterns in the diagnosis of cutaneous malignant melanoma: analysis of the data of the German Central Malignant Melanoma Registry. *Br J Dermatol* 1997; 136: 968–969.
9. Braun MM, Tucker MA, Devesa SS, Hoover RN. Seasonal variation in frequency of diagnosis of cutaneous malignant melanoma. *Melanoma Res* 1994; 4: 235–241.
10. Holman CDJ, Heenan PJ, Caruso V, Glancy RJ, Armstrong BK.

- Seasonal variation in the junctional component of pigmented naevi. *Int J Cancer* 1983; 31: 213–215.
11. Larsen TE, Mogensen SB, Holme I. Seasonal variations of pigmented naevi. *Acta Derm Venereol* 1990; 70: 115–120.
  12. Tronnier M, Wolff HH. UV-irradiated melanocytic nevi may simulate melanoma in situ. *Am J Dermatopathol* 1995; 17: 1–6.
  13. Tronnier M, Smolle J, Wolff HH. UV-irradiation induces acute changes in melanocytic nevi. *J Invest Dermatol* 1995; 104: 475–478.
  14. Koh HK, Miller DR, Geller AC, Clapp RW, Mercer MB, Lew RA. Who discovers melanoma? *J Am Acad Dermatol* 1992; 26: 914–919.
  15. English DR, Armstrong BK. Melanocytic nevi in children. I. Anatomic sites and demographic and host factors. *Am J Epidemiol* 1994; 139: 390–401.
  16. MacKie RM, English J, Aitchison TC, Fitzsimons CP, Wilson P. The number and distribution of benign pigmented moles (melanocytic naevi) in a healthy British population. *Br J Dermatol* 1985; 113: 167–174.
  17. Bulliard JL. Site-specific risk of cutaneous malignant melanoma and pattern of sun exposure in New Zealand. *Int J Cancer* 2000; 85: 627–632.
  18. Bell M, Beyl CM, Schopf RE, Schramm P. Light exposure of the lower leg as a pathogenetic factor in the occurrence of malignant melanoma. *Dermatology* 1992; 185: 257–261.
  19. Theobald T, Marks R, Hill D, Dorevitch A. “Goodbye sunshine”: effects of a television program about melanoma on beliefs, behavior, and melanoma thickness. *J Am Acad Dermatol* 1991; 25: 717–723.
  20. Piepkorn M, Meyer LJ, Goldgar D, Seuchter SA, Cannon-Albright LA, Skolnick MH, Zone JJ. The dysplastic nevus: a prevalent lesion that correlates poorly with clinical phenotype. *J Am Acad Dermatol* 1989; 20: 407–415.
  21. Stierner U, Augustsson A, Rosdahl I, Suurkula M. Regional distribution of common and dysplastic naevi in relation to melanoma site and sun exposure. A case-control study. *Melanoma Res* 1991; 1: 367–375.