

Narrow-band UVB Treatment in Atopic Dermatitis

Mika Hjerpe, Taina Hasan, Irma Saksala and Timo Reunala*

Department of Dermatology, University and University Hospital of Tampere, P.O. Box 2000 FIN-33521 Tampere, Finland.

E-mail: timo.reunala@tays.fi

Accepted September 26, 2001.

Sir,

Atopic dermatitis (AD) is common in the Nordic countries and adult patients are frequently treated with various UV-light modalities. These include selective ultraviolet phototherapy (SUP), combined UVAB and broad-band UVB (1–3). Previously, Falk (2) and Jekler & Larkö (3) found that combined UVAB treatment was more effective than broad-band UVB in resolving AD. Narrow-band UVB (TL-01; 311–313 nm) is a recent development that has rapidly gained popularity in the treatment of psoriasis (4, 5). Narrow-band UVB has also been tried in a few open studies in AD (6–8), and recently this treatment was shown to have equal efficacy to bath-PUVA in severe AD (9).

In our department, we have used combined UVAB treatment for AD for several years and have now compared this treatment to narrow-band UVB.

MATERIAL AND METHODS

Ten adult patients (mean age 27 years) with symmetrical AD were included in the half-side (right/left) comparison study. One side of the body was treated with narrow-band UVB, the other with combined UVAB. The light source for narrow-band UVB was Waldman TL01 (initial dose 0.33 J/cm², maximum dose 0.6–2.10 J/cm²). Combined UVAB was given in a Waldman cabin (UVA F85/100W; UVB F85/100W/UV21) with initial doses of 2.0 J/cm² for UVA and 0.02 J/cm² for UVB, and maximum doses of 4.0–10.7 J/cm² and 0.06–0.17 J/cm², respectively. Treatment was given 3 times a week for 6 weeks. The patients used the same emollient cream during the treatment course and, if needed, they were also allowed to use 1% hydrocortisone cream.

Treatment effects were evaluated for both sides of the body with SCORAD (10) at 3 and 6 weeks on treatment, and 6 weeks after stopping the therapy. The scoring investigator was blinded to the type of UV treatment given for each side of the body.

RESULTS

Narrow-band UVB lowered SCORAD more than combined UVAB (Fig. 1), but the difference was non-significant at 3 weeks ($p=0.066$; Wilcoxon rank sum test) and at 6 weeks ($p=0.069$). When pruritus was analysed separately, narrow-band UVB caused a significant reduction at 6 weeks compared to combined UVAB (mean visual analogue scores 2.7 and 3.8; $p=0.043$). At 12 weeks, i.e. 6 weeks after stopping the treatment, the results were still good, and no difference was found between the body sides treated.

All 10 patients preferred narrow-band UVB to combined UVAB, the reasons being more efficient relief of pruritus and shorter duration of exposure to UV.

DISCUSSION

Our study confirmed previous reports on the efficacy of narrow-band UVB treatment in moderate to severe AD (6–8). In the present study, we also compared in half-side fashion narrow-band UVB to combined UVAB. The latter treatment

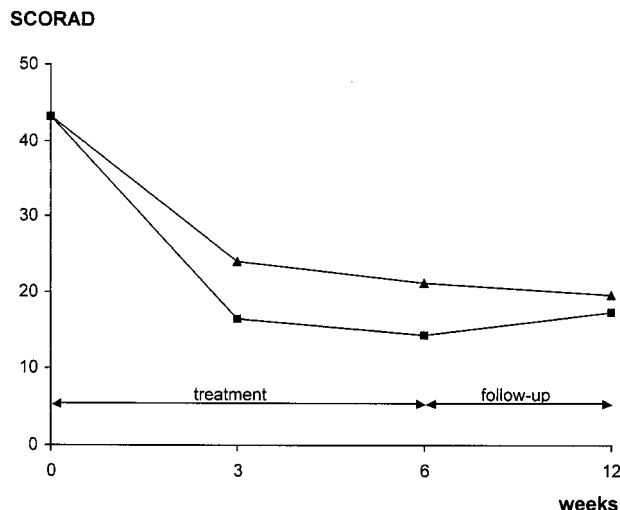


Fig. 1. Narrow-band UVB (NB-UVB) and combined UVAB treatment results in half-side comparison study in 10 patients with atopic dermatitis (■ = NB-UVB; ▲ = UVAB).

has previously been reported efficient in AD (2, 3) and has been in routine use in our department for several years. In the present study, individual minimal erythema doses were not measured, but we used an in-house standard regimen for combined UVAB and about equi-erythemogenic doses for narrow-band UVB. Our comparison results evaluated by SCORAD showed that the narrow-band UVB was as effective as the combined UVAB. The effects solely on pruritus and patient preference are clearly better for narrow-band UVB than for combined UVAB.

In agreement with the narrow-band UVB results in the present 10 patients with moderate AD, Der-Petrossian et al. (9) found, in a half-side comparison study in 12 patients with severe AD, that the narrow-band UVB decreased SCORAD by 64% and that the effect was similar to that of bath-PUVA. In the present study, the treatment effect persisted at least for 6 weeks. Previously, George et al. (6) and Der-Petrossian et al. (9) observed several long-lasting remissions in their narrow-band UVB-treated patients with AD.

We conclude that narrow-band UVB appears to be a promising treatment for AD, but large patients series, different dosing schedules and long-term safety considerations should be carefully evaluated in the future.

REFERENCES

1. Salo O, Lassus A, Juvankoski T, Kanerva L, Lauharanta J. Behandlung der Dermatitis atopica und der Dermatitis seborrhoica mit selektiver UV-phototherapie und PUVA. *Dermatol Monatsschr* 1983; 169: 371–375.
2. Falk ES. UV-light therapies in atopic dermatitis. *Photodermatology* 1985; 2: 241–246.

3. Jekler J, Larkö O. Combined UVA-UVB versus UVB phototherapy for atopic dermatitis: a paired comparison study. *J Am Acad Dermatol* 1990; 22: 49–53.
4. El-Ghorr AA, Norval M. Biological effects of narrow-band (311 nm TL01) UVB irradiation: a review. *J Photochem Photobiol* 1997; 38: 99–106.
5. Coven TR, Burack LH, Gilleaudeau P, Keogh M, Ozava M, Krueger JG. Narrowband UV-B produces superior clinical and histopathological resolution of moderate-to-severe psoriasis in patients compared with broadband UV-B. *Arch Dermatol* 1997; 133: 1514–1522.
6. George SA, Bilstrand DJ, Johnson BE, Ferguson J. Narrow-band (TL01) UVB air-conditioned phototherapy for chronic severe adult atopic dermatitis. *Br J Dermatol* 1993; 128: 49–56.
7. Hudson-Peacock MJ, Diffey BL, Farr PM. Narrow-band UVB phototherapy for severe atopic dermatitis. *Br J Dermatol* 1996; 135: 332.
8. Grundmann-Kollman M, Behrens S, Podda M, Peter RU, Kaufmann R, Kerscher M. Phototherapy for atopic eczema with narrow-band UVB. *J Am Acad Dermatol* 1999; 40: 995–997.
9. Der-Petrossian M, Seeber A, Hönigsmann H, Tanew A. Half-side comparison study on the efficacy of 8-metoxypsoralen bath-PUVA versus narrow-band ultraviolet B phototherapy in patients with severe chronic atopic dermatitis. *Br J Dermatol* 2000; 142: 39–43.
10. Kunz B, Oranje AP, Labreze L, Stalder JF, Ring J, Taieb A. Clinical validation and guidelines for the SCORAD index: consensus report of the European Task Force for Atopic Dermatitis. *Dermatology* 1997; 195: 10–19.

Acrokeratosis Paraneoplastica (Bazex's Syndrome): Unusual Association with a Peripheral T-cell Lymphoma

Yu-Chih Lin, Chia-Yu Chu and Hsien-Ching Chiu

Department of Dermatology, National Taiwan University Hospital, 7, Chung-Shan South Road, Taipei, Taiwan.

E-mail: hcc@ha.mc.ntu.edu.tw

Accepted September 26, 2001.

Sir,

Acrokeratosis paraneoplastica (AP), also known as Bazex's syndrome, is a paraneoplastic dermatosis characterized by dusky erythematous to violaceous keratoderma of the palms and soles. The scaly plaques may also involve the ears, nose and, in advanced cases, knees, elbows and trunk. In most cases reported there has been an underlying squamous cell carcinoma (SCC) (1). Some other associated malignancies have also been reported (2–8). We hereby describe a case of AP in association with peripheral T-cell lymphoma. To our knowledge, this association has not been reported in the literature.

CASE REPORT

A 57-year-old woman visited our clinic with hyperkeratotic palms and soles which had been present for 2 weeks. In addition, she had been suffering from cervical lymphadenopathy for 5 months. Physical examination revealed well-demarcated, dusky red, thick, scaly plaques on the palms and soles with sparing of the insteps (Figs 1, 2). A few eczematous patches were scattered on the nose and ears. Several enlarged, elastic-firm, movable lymph nodes with a diameter of 1–2 cm were also palpable on both sides of the neck.

One of the cervical lymph nodes was biopsied, and the histology showed features of peripheral T-cell lymphoma. Examination of an iliac crest marrow aspirate showed involvement of lymphoma. Computed tomographic examination revealed multiple enlarged lymph nodes and a tumour with a diameter of 10 cm in the abdomen. Based on these findings, a diagnosis of AP associated with stage IV peripheral T-cell lymphoma was made.

The skin lesions were treated with 0.05% fluocinonide cream and 10% urea cream, and the effect was slight and transient.

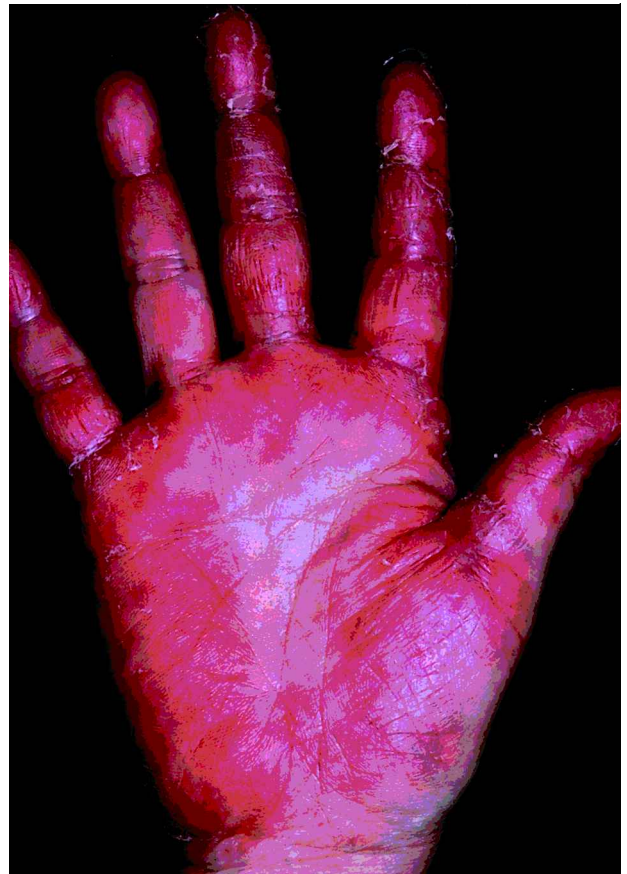

Fig. 1. Typical dusky red palmar keratoderma.

An initial combined chemotherapy with cyclophosphamide, epirubicin, vincristine and prednisolone was poor. The lymphoma progressed in spite of another chemotherapy with