

CLINICAL REPORT

Variegate Porphyrria with Coexistent Decrease in Porphobilinogen Deaminase Activity

GEORG WEINLICH¹, MANFRED O. DOSS², NORBERT SEPP¹ and PETER FRITSCH¹

¹Department of Dermatology, University of Innsbruck, Innsbruck, Austria and ²Department of Clinical Biochemistry, University of Marburg, Marburg, Germany

Variegate porphyria is a rare disease caused by a deficiency of protoporphyrinogen oxidase. In most cases, the clinical findings are a combination of systemic symptoms similar to those occurring in acute intermittent porphyria and cutaneous lesions indistinguishable from those of porphyria cutanea tarda. We report on a 24-year-old woman with variegate porphyria who, after intake of lynestrenol, developed typical cutaneous lesions but no visceroneurological symptoms. The diagnosis was based on the characteristic urinary coproporphyrin and faecal protoporphyrin excretion patterns, and the specific peak of plasma fluorescence at 626 nm in spectrofluorometry. Biochemical analysis revealed that most of the family members, though free of clinical symptoms, excrete porphyrin metabolites in urine and stool similar to variegate porphyria, accompanied by a significant decrease of porphobilinogen deaminase activity of a range which is ordinarily found in patients with acute intermittent porphyria only (~50%). These data first led to the assumption of two separate and independently inherited genetic defects, similar to the dual porphyria of Chester. Molecular analysis, however, revealed only a missense mutation of the protoporphyrinogen oxidase gene, but not of the porphobilinogen deaminase gene. Thus, in the family presented, porphobilinogen deaminase deficiency is likely to be a phenomenon secondary to the genetic defect of protoporphyrinogen oxidase. *Key words: acute intermittent porphyria; lynestrenol; porphobilinogen deaminase; porphyria cutanea tarda; protoporphyrinogen oxidase; variegate porphyria.*

(Accepted August 22, 2001.)

Acta Derm Venereol (Stockh) 2001; 81: 356–359.

Georg Weinlich, Department of Dermatology, University of Innsbruck, A-6020 Innsbruck, Austria.
E-mail: georg.weinlich@uibk.ac.at

Porphyrias comprise a group of predominantly hereditary diseases caused by disturbances of one or more enzymes which catalyse the haem biosynthetic pathway (1, 2). According to the site of derailed porphyrin synthesis, erythropoietic and hepatic porphyrias are traditionally distinguished. Some porphyrias feature characteristic cutaneous reactions in sun-exposed areas (3).

Porphyria cutanea tarda (PCT, chronic hepatic porphyria), the most common porphyria, results from uroporphyrinogen (URO) decarboxylase deficiency. Skin symptoms include cutaneous fragility, blistering (because of accumulation of water-soluble uro- and coproporphyrins), scarring, milia and hyperpigmentation and hypertrichosis, especially of sun-exposed areas (2, 3). Acute intermittent porphyria (AIP), the most common acute hepatic porphyria, is caused by an autosomal-dominant deficiency of porphobilinogen (PBG)

deaminase. Its activity is reduced by about 50%, resulting in varying degrees of overproduction and increased urinary excretion of delta-aminolaevulinic acid (ALA) and PBG. In AIP, skin changes are absent, but patients suffer from episodic central or peripheral nervous system and/or psychiatric symptoms, or acute attacks of abdominal pain (2, 4).

Variegate porphyria (VP), a rare autosomal-dominant hepatic porphyria due to a deficiency of protoporphyrinogen (PROTO) oxidase, the related gene (PPOX) for which has been located to chromosome 1q22-23 (5, 6), is characterized by both acute neurological symptoms as in AIP and skin lesions indistinguishable from PCT; it is thus also termed mixed porphyria (2, 7, 8). The highest prevalence of VP has been reported for South Africa (3 per 1000). In Europe, VP is less common than AIP. Only 30–45% of patients develop skin symptoms (9, 10). Acute attacks (neurological or cutaneous) may be precipitated by drugs (e.g. hormones, antibiotics, barbiturates), pregnancy or reduced carbohydrate intake, but most patients are symptom-free throughout life (2, 3, 11, 12).

The diagnosis of VP is based on clinical features, the pattern of porphyrin metabolites in urine and faeces, and the demonstration of a specific peak of plasma fluorescence at 626 nm by spectrofluorometry (13–15).

In approximately half of the patients with VP, the specific enzymatic defect of PROTO oxidase is accompanied by a slight decrease of PBG deaminase activity (20–25%). This enzyme defect appears to be without clinical consequence in most patients, because no severe additional symptoms are found and the porphyrin excretion pattern is not typical for AIP (9, 16).

A kinship exhibiting a “dual” enzyme defect (decrease of PROTO oxidase of about 25% and of PBG deaminase of about 50%) with attacks of neurovisceral dysfunction, but devoid of cutaneous photosensitivity, has been described under the term “Chester porphyria” (17, 18). In this specific type of porphyria, the porphyrin excretion patterns vary between those typical for AIP and for VP.

The present report describes a patient (and her family) with VP who developed cutaneous symptoms only after the administration of lynestrenol. Although the activity of PBG deaminase was decreased to 50% as well, neither she nor her family ever showed clinical symptoms of AIP, as would be expected for dual porphyria of Chester, and no genetic defect in the PBG deaminase gene was detected.

CASE REPORT

In September 1995, a 24-year-old woman presented with blisters, superficial erosions, haemorrhagic crusts, milia and patchy hyperpigmentation of the extensor sites of fingers and hands. Similar but milder lesions were found in the face, which appeared unusually sun-damaged (Fig. 1). The patient had been aware of having special

skin fragility since youth; minimal trauma, particularly to sun-exposed areas, had readily resulted in skin abrasions which were slow to heal.

Photosensitivity had never been noted, there was no history of abdominal colicky pains nor of neuropsychiatric disturbance. Previous drug intake, including a contraceptive composed of desogestrel, ethinyl-estradiol and tocopherol, had never led to systemic or skin symptoms. Two months prior to admission, the patient had begun taking lynestrenol (5 mg/day) to delay ovulation after a planned summer vacation in Greece. The vacation was spent without trouble, but 2 weeks after her return home, she noticed sensitivity to sunlight, i.e. itching and burning, erythema and vesicles of sun-exposed areas. While feeling healthy in general, she noted that her urine became unusually dark.

A skin biopsy showed a subepidermal blister and a moderate perivascular inflammatory infiltrate; dermal blood vessel walls were thickened and PAS-positive. Immunofluorescence studies revealed IgM and C3 deposits in papillary dermal vessels. Routine laboratory tests, including blood count and iron levels, were within normal limits.

Screening of urinary porphyrins in our laboratory showed elevated levels of total porphyrins (TP), coproporphyrin (COPRO) and URO, with a moderate dominance of COPRO. No fluorocytes were detected in the peripheral blood by fluorescence microscopy.

A diagnosis of PCT was assumed, and a combined regimen of phlebotomies (2 × 300 ml) and chloroquine (125 mg twice weekly, orally) was initiated, accompanied by sun-protective measures. No therapeutic effect became apparent within 6 weeks, however; new blisters continued to appear and the elevation of urinary porphyrins (COPRO > URO) persisted.

A more specific analysis of the porphyrin abnormalities carried out by one of us in the laboratory (M.O.D.) revealed a high elevation of urinary porphyrins with a predominance of COPRO and an elevation of faecal porphyrins with a predominance of protoporphyrin (PROTO > COPRO); also, urinary ALA and PBG were moderately elevated (Table I).

This porphyrin excretion pattern and the normal activity of URO decarboxylase definitively ruled out PCT and was highly suggestive of VP. Fluorescence spectrophotometry of the plasma, excitation at 405 nm, revealed an emission peak at 626 nm (scanning 610–650 nm). This finding confirmed the biochemical analysis, and a diagnosis of a gestagen triggered VP, without visceroneurological symptoms, was established.

Chloroquine was withdrawn and low-dose beta-carotene (25 mg twice daily, orally) was instituted (07/96). Within 4 weeks, skin lesions

and photosensitivity gradually disappeared, faecal and urinary porphyrins slowly decreased over the next 3 months. No flare-ups were observed in a 48-month follow-up period, although the patient discontinued beta-carotene after 9 months and the (faecal) porphyrins slowly increased again (Table I). At the last control (09/99), ALA, PBG and urinary TP were normal, with a slight elevation of COPRO (90% of TP). Faecal excretion of TP was increased (1.2 mg, normal 0–0.1 mg) with a predominance of PROTO (50% of TP). These values are suggestive of low disease activity typical for latent VP.

Family history disclosed skin fragility and delayed wound healing in the mother and the grandmother of the proposita as well as in two of her three sisters; neither photosensitivity nor blister formation was reported. Clinical examination of the parents (both from Austrian extraction) and sisters yielded no skin lesions suggestive of PCT, nor was there a clear history of neurological, abdominal or cardiovascular symptoms of AIP. Only the patients' mother reported past attacks of abdominal colic, once in association with estrogen intake. Stool and urine samples of the mother and the two sisters with skin fragility yielded elevated porphyrins in a pattern consistent with latent VP; plasma fluorescence emission spectroscopy showed typical emission peaks at 626 nm, confirming the biochemical analysis. Only the father and the eldest sister, who had never had skin problems showed normal porphyrin excretion and no emission peak at 626 nm (Table II).

As the enzymatic defect of PROTO oxidase in patients with VP may be accompanied by a slight decrease of PBG deaminase activity, this latter enzyme was investigated in a further analysis. Surprisingly, its activity was found significantly reduced in the proposita and the sisters with skin fragility, the range of reduction (about 50%) equalling that of patients with AIP. Even the sister who had never had skin symptoms nor a porphyrin excretion pattern of VP was identified as a carrier of PBG deaminase deficiency (enzyme activity decreased by 59%). Both parents had slightly decreased activities (about 25%) (Fig. 2).

Molecular mutational analysis of our patient identified a single missense mutation in the protoporphyrinogen oxidase (PPOX) gene, whereas analysis of the PBG deaminase gene showed a normal sequence of the coding region (laboratory Dr. Erhard & Partners, Dortmund) (manuscript in preparation).

DISCUSSION

VP is a rare disease in Europe, whereas in South Africa the reported prevalence is 3 per 1000. Acute neurological attacks

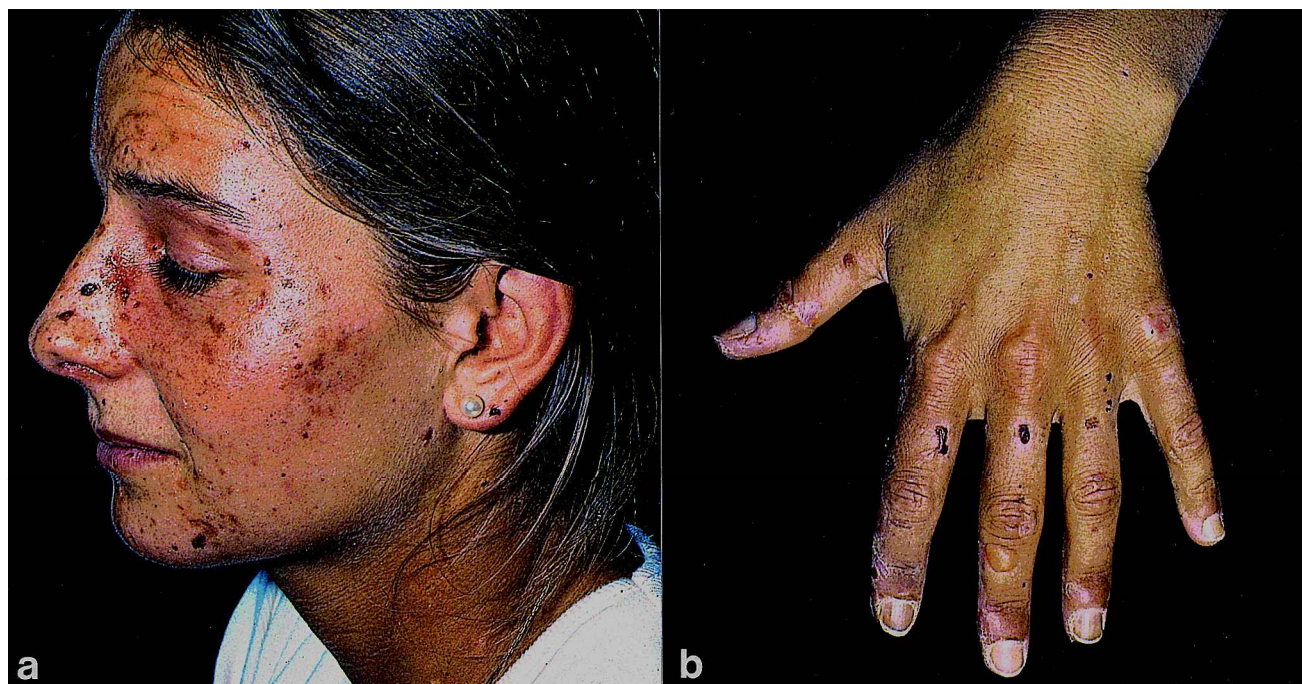

Fig. 1. The face (a) and the left hand (b) of the patient with erosions, crusts, blisters, scars and milia formation in active phase of variegate porphyria.

Table I. Porphyrin excretion pattern of the patient's urine and stool at time of diagnosis and during a 42-month follow-up period

Date of investigation	96-01-25		96-07-15		97-10-27		99-09-22		Normal values	
	Urine ($\mu\text{g}/24\text{ h}$)	Faeces ($\mu\text{g}/\text{g}$)	Urine ($\mu\text{g}/24\text{ h}$)	Faeces ($\mu\text{g}/\text{g}$)	Urine ($\mu\text{g}/24\text{ h}$)	Faeces ($\mu\text{g}/\text{g}$)	Urine ($\mu\text{g}/24\text{ h}$)	Faeces ($\mu\text{g}/\text{g}$)	Urine ($\mu\text{g}/24\text{ h}$)	Faeces ($\mu\text{g}/\text{g}$)
Total porphyrins	449	870	1101	891	625	773	154	1200	< 1000	< 200
delta - ALA	6300		15015		8050		1750		< 6400	
Porphobilinogen	1800		9867		3960		440		< 1700	
Uroporphyrin	60	< 3	57	< 3	48	< 3	16	< 3	< 24	< 3
Coproporphyrin	377	241	937	220	570	248	131	523	< 78	3–24
Protoporphyrin	< 1	626	< 1	653	< 1	522	< 1	626	< 1	12–85

ALA: aminolaevulinic acid.

Table II Symptoms and results of porphyrin examination of the family with variegate porphyria (VP) and porphobilinogen deaminase deficiency (PBD) (see Fig. 2)

	Symptoms		Fluorescence	Excr. pattern	Enzyme pattern ($\mu\text{mol}/\text{lxh}$) (% of normal controls, $n = 4$)	
	Cutaneous	Systemic			PBG-deaminase	URO-decarboxilase
Patient	Fragile, blisters	Negative	626 nm	VP	40.7 (58%)	7.8 (94%)
Sister 1	Fragility	Negative	626 nm	VP	38.8 (53%)	8.4 (101%)
Sister 2	Fragility	Negative	626 nm	VP	42.5 (58%)	8.12 (98%)
Sister 3	Negative	Negative	Negative	Negative	46.3 (59%)	3.6 (53%)
Mother	Fragility	Colic symptoms?	626 nm	VP	66.6 (87%)	5.9 (85%)
Grandmother	Fragility	Negative	n.d.	n.d.	n.d.	n.d.
Father	Negative	Negative	Negative	Negative	64.8 (85%)	5.0 (73%)

n.d.: not done.

URO = oruroporphyrinogen.

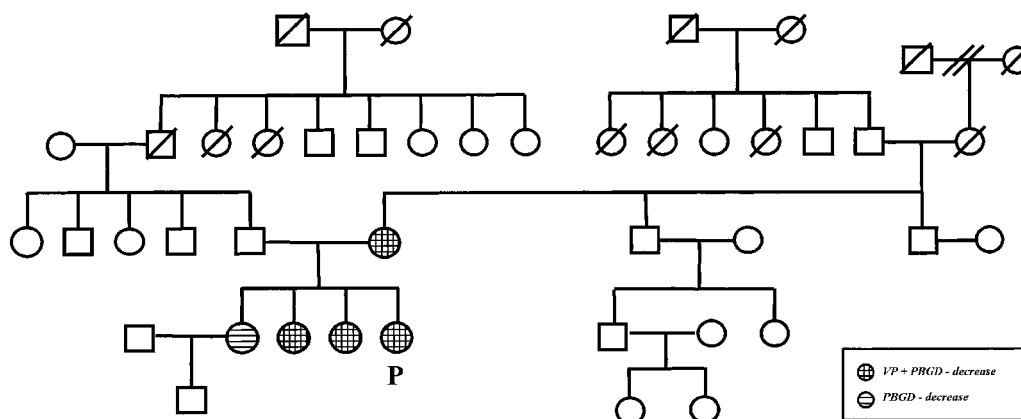


Fig. 2. Genealogical tree of the family with variegate porphyria and porphobilinogen deaminase deficiency (see Table II).

are often induced by various drugs (e.g. estrogens, barbiturates, dapsone, sulfonamides) or starvation (2–4), whereas induction of cutaneous symptoms due to oral contraceptives is rare (19, 20). In most cases, VP is caused by a heterozygous PROTO oxidase deficiency and is inherited as an autosomal-dominant trait. Homozygous VP has been reported (5, 21, 22). Reduced PROTO oxidase activity, caused by a defect at chromosome 1q22–23, is thought to be the primary defect (5, 6, 23–25) which leads to a compensatory upregulation of ALA synthase, the initial and rate-controlling enzyme of the haem synthesis pathway, by a negative feedback mechanism controlled by

haem. Overproduction of the porphyrins and their precursors upstream of the enzymic block ensues.

In VP, ALA and PBG are elevated during acute attacks and return to normal values during symptom-free intervals in most patients. Urinary COPRO is increased, higher than urinary URO. Another characteristic finding is the faecal porphyrin excretion pattern: even asymptomatic patients show increased levels of PROTO and COPRO; PROTO typically exceeding COPRO (1, 2, 7, 9).

Besides repeated appropriated laboratory tests of stool and urine, another test is helpful in the diagnosis of VP (even in

asymptomatic carriers of this disease) – the fluorescence emission spectroscopy of plasma (14–16). Using excitation at 405 nm, this test shows an emission peak at 626 nm, highly specific for VP. The main abnormal porphyrin in the plasma which causes this typical peak is believed to be a covalently bound dicarboxylic porphyrin-protein complex (15). Although the sensitivity of this test in asymptomatic first- and second-degree relatives varies between 60% and 100%, fluorescence emission scanning of plasma is a quick, cheap and specific test in the screening for VP.

Coexistence of PROTO oxidase deficiency with moderate PBG deaminase deficiency (20–25%) has been detected in about 50% of patients with VP (9, 16). These findings were thought to be of no clinical relevance as the excretion pattern was conclusive with VP, and the PBG deaminase deficiency was not found exclusively in patients with neurological, abdominal or cardiovascular symptoms. A 50% decrease of PBG deaminase in VP, however, as seen in our family, is unusual, especially since symptoms of AIP were absent. Consequently, a dual porphyria was first suspected.

In 1985, a dual porphyria with coexisting defects of PROTO oxidase and PBG deaminase was described as “Chester porphyria” (17, 18). In this large family, which originates from a founder couple married in 1896 and comprises 200 descendants, the dual enzyme defect caused porphyrin excretion patterns typical of AIP in some affected individuals and of VP in others, some patients showing intermediate patterns. Patients with lower PBG desaminase values tended to have AIP excretion patterns, those with lower PROTO oxidase values VP patterns. But in contrast to the family reported above, patients with Chester porphyria never showed photosensitivity.

Meissner et al. propose that the PBG deaminase deficiency in VP may be a secondary phenomenon to the PROTO oxidase defect (16), because if it was due to an independent dominant mutation (as in AIP), some family members would be expected to manifest a PBG deaminase deficiency alone. Our family data were more consistent with two independently inherited mutations, as one of the sisters, who had never had symptoms for VP or AIP, has a PBG deaminase deficiency of about 50%, although her excretion pattern of porphyrins in urine and stool was normal and the fluorospectrometric test of the plasma showed no peak at 626 nm. This interpretation could not be corroborated on the molecular level, however, because gene sequencing of our patient revealed only a missense mutation of the PROTO oxidase gene but not of the PBG deaminase gene, ruling out a dual porphyria with a high degree of likelihood. The unusual low PBG deaminase activity present in our family thus represents a unique and at present unexplained feature of VP.

REFERENCES

1. Kappas A, Sassa S, Galbraith RA, Nordmann Y. The porphyrias. In: Scriver CR, Beaudet AL, Sly WS, Valle D, eds. *The metabolic basis of inherited disease*, vol. 2, 7th ed. New York: McGraw-Hill, 1995: 2103–2159.
2. Doss MO, Sassa S. The porphyrias. In: Noe DA, Rock RC, eds. *Laboratory medicine. The selection and interpretation of clinical laboratory studies*, 2nd ed. Baltimore, MD: Williams & Wilkins, 1994: 535–553.
3. Murphy GM. The cutaneous porphyrias: a review. *Br J Dermatol* 1999; 140: 573–581.

4. Eales L, Day RS, Blekkenhorst GH. The clinical and biochemical features of variegate porphyria: an analysis of 300 case studies at Groote Schuur Hospital, Cape Town. *Int J Biochem* 1980; 12: 837–853.
5. Taketani S, Inazawa J, Abe T, Furukawa T, Kohono H, Tokunaga R, et al. The human protoporphyrinogen oxidase gene (PROX): organisation and location to chromosome 1. *Genomics* 1995; 29: 698–703.
6. Frank J, Jugert FK, Kalka K, Goerz G, Merk HF, Christiano AM. Variegate porphyria: identification of a nonsense mutation in the protoporphyrinogen oxidase gene. *J Invest Dermatol* 1998; 110: 449–451.
7. Corey TJ, DeLeo VA, Christianson H, Poh-Fitzpatrick MB. Variegate porphyria. Clinical and laboratory features. *J Am Acad Dermatol* 1980; 2: 36–43.
8. Epstein JH, Tuffanelli DL, Epstein WL. Cutaneous changes in the porphyrias. A microscopic study. *Arch Dermatol* 1973; 107: 689–698.
9. Doss MO, Grob U, Honcamp M, Jacob K. Variegate porphyria in Germany: a 25-year clinical, diagnostic, biochemical and therapeutic study. *Hepatology* 1996; 23: 285H.
10. Mustajoki P. Variegate porphyria. *Q J Med* 1980; 194: 191–203.
11. Timonen K, Niemi KM, Mustajoki P, Tenhunen R. Skin changes in variegate porphyria. Clinical, histopathological and ultrastructural study. *Arch Dermatol Res* 1990; 282: 108–114.
12. Crimlisk HL. The little imitator – porphyria: a neuropsychiatric disorder. *J Neurol Neurosurg Psychiatry* 1997; 62: 319–328.
13. Poh-Fitzpatrick MB. A plasma porphyrin fluorescence marker for variegate porphyria. *Arch Dermatol* 1980; 116: 543–547.
14. Enriquez de Salamanca R, Sepulveda P, Moran MJ, Santos JL, Fontanellas A, Hernandez A. Clinical utility of fluorometric scanning of plasma porphyrins for the diagnosis and typing of porphyrias. *Clin Exp Dermatol* 1993; 18: 128–130.
15. Long C, Smyth SJ, Woolf J, Murphy GM, Finlay AY, Newcombe RG, et al. Detection of latent variegate porphyria by fluorescence emission spectroscopy of plasma. *Br J Dermatol* 1993; 129: 9–13.
16. Meissner PN, Day RS, Moore MR, Disler PB, Harley E. Protoporphyrinogen oxidase and porphobilinogen deaminase in variegate porphyria. *Eur J Clin Invest* 1986; 16: 257–261.
17. McColl KE, Thompson GG, Moore MR, Goldberg A. Chester porphyria: biochemical studies of a new form of acute porphyria. *Lancet* 1985; 2(8459): 796–799.
18. Qadiri MR, Church SE, McColl KE, Moore MR, Youngs GR. Chester porphyria: a clinical study of a new form of acute porphyria. *BMJ* 1986; 292: 455–459.
19. Fowler CJ, Ward JM. Porphyria variegata provoked by contraceptive pill. *BMJ* 1975; 1: 663–664.
20. McKenzie AW, Acharya U. The oral contraceptive and variegate porphyria. *Br J Dermatol* 1972; 86: 453–457.
21. Kordac V, Deybach JC, Martasek P, Zeman J, da Silva V, Nordmann Y, et al. Homozygous variegate porphyria. *Lancet* 1984; 1(8381): 851.
22. Norris PG, Elder GH, Hawk JLM. Homozygous variegate porphyria: a case report. *Br J Dermatol* 1990; 122: 253–257.
23. Roberts AG, Whatley SD, Daniels J, Holmans P, Fenton I, Owen MJ, et al. Partial characterization and assignment of the gene for protoporphyrinogen oxidase and variegate porphyria to human chromosome 1q23. *Hum Mol Genet* 1995; 4: 2387–2390.
24. Whatley SD, Puy H, Morgan RR, Robreau AM, Roberts AG, Nordmann Y, et al. Variegate porphyria in Western Europe: identification of PPOX gene mutations in 104 families, extent of allelic heterogeneity, and absence of correlation between phenotype and type of mutation. *Am J Hum Genet* 1999; 65: 984–994.
25. Palmer RA, Elder GH, Barrett DF, Keohane SG. Homozygous variegate porphyria: a compound heterozygote with novel mutations in the protoporphyrinogen oxidase gene. *Br J Dermatol* 2001; 144: 866–869.