

INVESTIGATIVE REPORT

Why are Scars Pale? An Immunohistochemical Study Indicating Preservation of Melanocyte Number and Function in Surgical Scars

SHIREEN S. VELANGI¹ and JONATHAN L. REES²

Departments of Dermatology of ¹Sunderland Royal Hospital, Sunderland, UK and ²The University of Edinburgh, Edinburgh, UK

The cosmetic effect of many mature scars is largely due to their paler appearance than the surrounding skin. The aim of the study was to identify whether melanocytes are present and functioning within pale scars. Cryosections from scar and normal tissue were stained with murine monoclonal antibodies mel-5, c-kit and NKI/beteb to detect melanocytes and precursor melanocytes. The mean number of mel-5 immunopositive melanocytes within scar tissue was similar to that seen in normal skin (26, SEM 3.5, versus 28.9, SEM 4.1, per 200 basal cells). Where paired samples were available, there was no statistically significant difference between scar tissue and adjacent skin (95% CI = -7.8 to +4.6, $p=0.53$). Masson-Fontana stain for melanin was positive in both scar tissue and adjacent normal skin, with no evidence for differences in melanin transfer to keratinocytes. Our results suggest that neither differences in melanocyte number nor melanogenic activity explain the appearance of scars. It would seem likely that a combination of both vascular and optical factors relating to dermal or epidermal characteristics are more important. Key words: pigment; melanocytes; scars.

(Accepted August 27, 2001.)

Acta Derm Venereol 2001; 81: 326–328.

Shireen Velangi, Department of Dermatology, Sunderland Royal Hospital, Kayll Road, Sunderland, Tyne and Wear SR4 7TP, England. E-mail: ms.velangi@btinternet.com

Many, if not most, scars following excisional biopsies are paler than the surrounding epidermis. The reasons for the paleness of the scars and melanocyte behaviour within scars have received little attention. Some scars are pigmented and it is known that under the influence of melanotrophic hormones such as ACTH or MSH scars can hyperpigment (1). This would imply that these melanotrophic peptides influence melanocyte function or migration following wounding.

Because of our interest in the receptor for α MSH, the melanocortin 1 receptor (2, 3), we wondered whether scars were pale because of an absence of functional melanocytes, but that under the influence of melanotrophic peptides melanocyte number could be increased. In order to examine this hypothesis we carried out immunostaining on a number of scars and adjacent (control) skin. We show that our original hypothesis is wrong and discuss alternative explanations.

MATERIALS AND METHODS

Patients

Sixteen Caucasian volunteers agreed to participate in this study (mean age 44; range 22–75). The male:female ratio was 1:1. All had

long-standing pale scars and gave consent for a 4 mm punch biopsy to be taken from the scar. Eleven biopsies were taken from sun-protected sites (chest 4; abdomen 5; thigh 2) and five from sun-unprotected sites (face 3; forearm 2). Subjects were skin type 2 or 3 and had not had significant recent sun exposure. In addition, in 6 of these volunteers, a 4 mm punch biopsy was also taken from adjacent normal skin (within 3–5 cm of the scar). Ethical approval was granted by Sunderland City Hospitals Trust ethics committee. Tissue was frozen in embedding medium (OCT; Miles, Elkhart, USA), cut into 7 μ m-thick sections and placed on Tespa coated glass slides (Sigma-Aldrich, St Louis, USA) for immunohistochemical and Masson-Fontana staining.

Immunohistochemistry

The sections were air-dried and acetone fixed at 4°C for 10 min. These specific monoclonal antibodies were used in the 10 unpaired samples (Table 1). Mel-5 detects a 75-kDa pigment-associated glycoprotein found on normal melanocytes and melanoma cells (4). The c-kit detects a tyrosine kinase receptor found on melanocytes and mast cells; interaction between mast cell growth factor and this receptor regulates the migration of melanoblasts from the neural crest and their subsequent differentiation into pigment-producing cells (5). NKI-beteb detects a 100-kDa melanosome-associated antigen found in precursor melanocytes, mature melanocytes and melanoma cells (6). Because Mel-5 seemed to give the most reproducible staining, Mel-5 alone was used for cell counts. The histological sections were incubated with the primary antibodies for 1 h at room temperature. Antibody reactivity was visualized by the peroxidase reaction using an avidin-biotin Vectostain kit (Vector Laboratories, UK) and diaminobenzidine (DAB) enhanced with nickel (7).

Melanocytes were identified by their positive staining with Mel-5, dendritic appearance and location in the basal layer of the epidermis. The number of melanocytes per 200 basal cells was counted by one observer (using a cell counter to prevent counting bias). In order to reduce observer error and represent all areas within the tissue, between 5 and 10 melanocyte counts (each from a different tissue section) were performed for each sample and the mean used in subsequent calculations.

Masson-Fontana staining

In order to assess melanin production, the Masson-Fontana stain was used. Unfixed frozen sections were incubated in ammoniacal silver solution in the dark for 30 min at 56°C. After bleaching with 0.5% sodium thiosulphate solution for 2 min and dehydration and mounting, melanin can be seen as black staining (8).

Statistics

Distribution of cell numbers appeared normal and results were compared using a paired *t*-test using StatsDirect (9).

RESULTS

The mean melanocyte number per 200 basal cells in scar tissue was 26 ($n=16$, SEM 3.5) compared to 28.9 in non-scar tissue ($n=6$, SEM 4.1). There was no statistically significant

Table I. Details of antibodies used

Antibody	Type	Detects	Source
Mel-5	Mouse monoclonal	75 kDa pigmentation glycoprotein	Signet Laboratories Inc.
c-kit	Mouse monoclonal	Tyrosine kinase transmembrane receptor	Novocastra Laboratories Ltd.
NKI-beteb	Mouse monoclonal	Premelanosomal 100+7 kDa glycoprotein	Accurate Chemical & Scientific Corporation

difference in melanocyte number between scars and paired normal sites (95% CI - 7.8 to 4.6, $p=0.53$, $n=6$) (see Fig. 1).

A Masson-Fontana stain was positive with similar intensity in both scar and normal tissue. Although the majority of melanin granules were found in the basal layer, they were also visible in other layers of the epidermis and did not appear to differ between scar and normal tissue.

DISCUSSION

Our results are different from what we had anticipated, but nevertheless are decisive. Few authors have examined melanocyte behaviour in wounding and in scars. Snell carried out experiments on guinea pigs and showed that melanocytes gradually migrate into the healing wound, and that there is an apparent increase in melanocyte number in early scar tissue (10). Unfortunately, long-term scars were not studied. Breathnach showed melanocytes within the central area of an early scar, in keeping with the idea of melanocyte migration

from the wound edges (11). He also showed, on a single patient, small freckles within pale epidermis covering a stretched scar (12). It is known of course that pigmented areas can rise or cross scars close to previous melanoma excisions.

Our original hypothesis was that scars were pale due to a decrease in either the number or activity of melanocytes within the scar. The oft-quoted observations on patients with Addison's disease would have been compatible with such a theory with melanotrophic activity being increased in response to circulating factors (1). However, although our numbers are small, we believe it unlikely that changes in melanocyte number or activity explain the paleness of most scars. Alternative hypotheses therefore need to be considered.

First, vascularity in scar tissue may be different from adjacent skin dermal tissue. If there was decreased blood within the scar tissue then it may appear paler than the surrounding skin. We suspect this is part of the explanation. Injection of noradrenaline certainly can diminish the contrast between a scar and adjacent skin, but it does not usually abolish it (JLR unpublished).

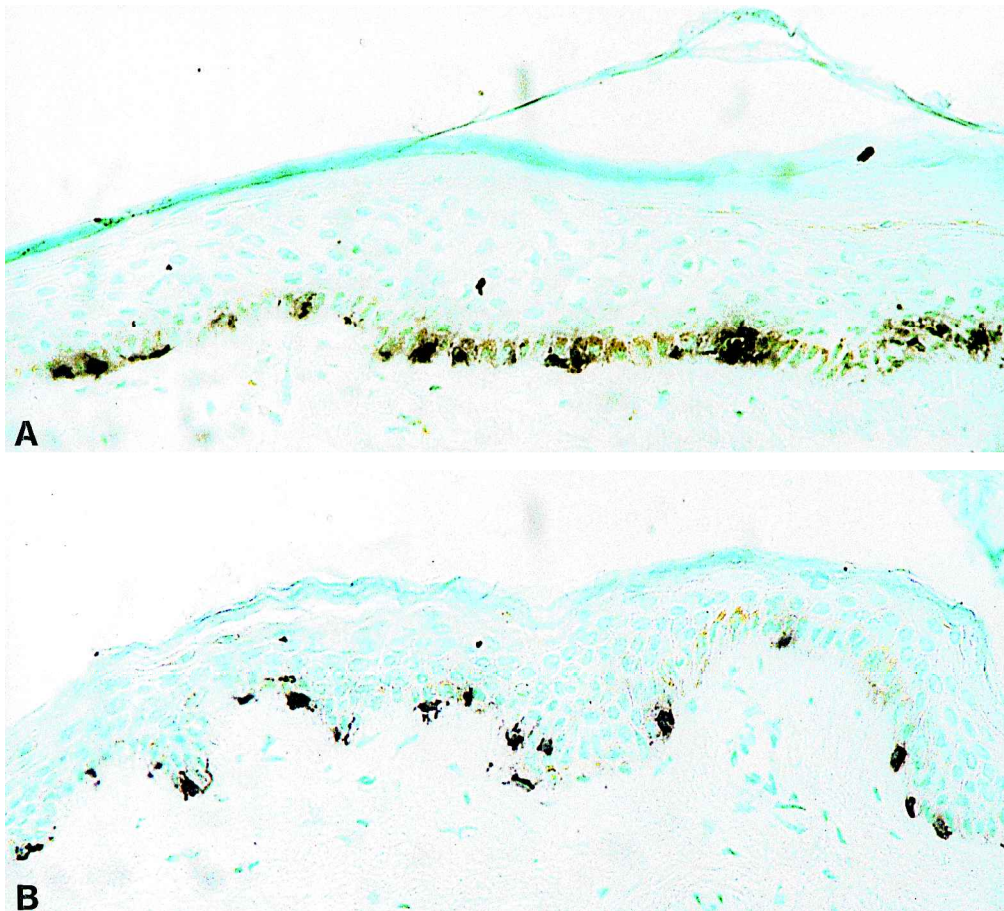


Fig. 1. Mel-5 immunostaining in normal skin (a) and scar (b).

A second possibility is that the abnormal organization of collagen fibres within the dermis, or even epidermal change, results in a greater reflection of light back towards the observer (13). In normal skin, where collagen fibres are randomly oriented, it is said that the scattering pattern is nearly circular and therefore little light is reflected back towards the light sources. In scar tissue, by contrast, which consists of parallel orientated fibres, light is scattered primarily in the direction perpendicular to the fibres (14). Finally, the lack of undulation of some epidermis in a scar, or epidermal thinning, may result in a drop in optical density.

We believe that all three mechanisms may be relevant as to why scars usually appear pale, but nevertheless still consider that the increased pigmentation seen under melanotrophic influence is worthy of further experimentation.

REFERENCES

1. Orth DN, Kovacs WJ. The adrenal cortex. In: Wilson JD, Foster DW, Kronenberg HM, Larsen PR, eds. *Williams' textbook of endocrinology*. Philadelphia: W. B. Saunders, 1998: 517–664.
2. Rees JL. The Melanocortin 1 Receptor (MC1R): more than just red hair. *Pigment Cell Res* 2000; 13: 135–140.
3. Healy E, Flannagan N, Ray A, Todd C, Jackson IJ, Matthews JNS, et al. Melanocortin 1 receptor gene and sun sensitivity in individuals without red hair. *The Lancet* 2000; 335: 1072–1073.
4. Thomson TM, Mattes MJ, Roux L, et al. Pigmentation-associated glycoprotein of human melanomas and melanocytes: definition with a mouse monoclonal antibody. *J Invest Dermatol* 1985; 85: 169–174.
5. Fleischman R. From white spots to stem cells: the role of the kit receptor in mammalian development. *Trends Genet* 1993; 9: 285–290.
6. Le Poole IC, Van den Wijngaard RMJGJ, Westerhof W, et al. Presence or absence of melanocytes in vitiligo lesions: an immunohistochemical investigation. *J Invest Dermatol* 1993; 100: 816–822.
7. Shu SY, Ju G, Fan LZ. The glucose oxidase-DAB-nickel method in peroxidase histochemistry of the nervous system. *Neurosci Lett* 1988; 85: 169–171.
8. Culling CFA, Allison RT, Barr WT. *Cellular pathology technique*, 4th ed. London: Butterworths.
9. Buchan I. *StatsDirect statistical software*. <http://www.statsdirect.com>. 2001 England: CamCode.
10. Snell RS. A study of the melanocytes and melanin in a healing deep wound. *J Anat Lond* 1963; 97: 243–253.
11. Breathnach AS. Melanocytes in early regenerated human epidermis. *J Invest Dermatol* 1960; 35: 245.
12. Breathnach AS. Melanocyte pattern of an area of freckled epidermis covering a stretched scar. *J Invest Dermatol* 1958; 29: 237–241.
13. Anderson RR, Parrish JA. The optics of human skin. *J Invest Dermatol* 1981; 77: 13–19.
14. Ferdman AG, Yannas IV. Scattering of light from histological sections: a new method for the analysis of connective tissue. *J Invest Dermatol* 1993; 100: 710–716.