

## Primary Cutaneous Aspergillosis in an Immunocompetent Host

Sir,

Primary cutaneous aspergillosis is rare and when seen it is usually associated with compromised immune status of the host. The lesions usually occur at the site of trauma, e.g. in a sick patient at the site of armboards, tapes or intravenous catheters. The fungus, *Aspergillus*, is a saprophytic dimorphic mould present in soil, decaying vegetation and organic debris. Clinically it involves the lungs, central nervous system, naso-orbital area, skin and sometimes it may be disseminated.

### CASE REPORT

A 30-year-old male developed a pea-sized nodule in the right axilla 15 years earlier. There was no history of trauma preceding the lesion or of pain, ulceration or discharge of granules from the lesion. The nodule increased in size to approximately 7 × 2 cm in 4 years. At this stage, it was excised and the patient was given 9 months of anti-tubercular therapy. Eighteen months after the excision, he developed a nodule again at the excision site, which reached the previous dimensions in 2 years with overlying ulcers occasionally exuding seropurulent discharge. There was no history of fever, cough, dyspnoea, chest pain, haemoptysis, nasal or ear discharge, weight loss, loss of appetite, diabetes or hypertension, nor any symptoms suggestive of ophthalmological, neurological, bladder or bowel involvement.

At the time of presentation, cutaneous examination showed a subcutaneous nodular, lobulated swelling in the right axilla, extending linearly from the posterior axillary to the mid-clavicular line. It was 14 cm long and 5 cm wide and broadest at the centre (Fig. 1). The margins of the lesion were well defined and at the anterior and posterior ends, the finger could be insinuated under the margins slightly. The consistency was soft in the centre and firm towards the periphery, with a few puckered sinuses over the lesion, which on pressure yielded scanty seropurulent discharge. The skin overlying the lesion was erythematous, with loss of hair and the excisional scar running linearly through its length. The central portion of the lesions had an ulcer, 6 cm long and 3 cm wide, with irregular bluish margins and granulation tissue on the floor. Just below the lesion, there was a single firm, mobile non-tender, axillary lymph node. Examination of the middle ear, the dentition and slit lamp examination of the eyes were normal.

The haemogram, biochemical tests for liver and kidney functions, urine and stool examinations were within normal limits. Montoux was 4 × 4 mm. An ELISA test for HIV was negative. Fine needle

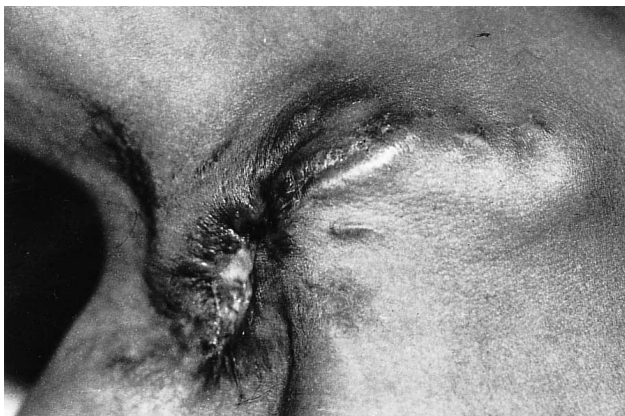

Fig. 1. Nodular, lobulated subcutaneous swelling with central ulceration and well-defined margins in the right axilla.

aspiration cytology (FNAC) from the lesion showed foreign body giant cells, some containing branched, septate hyphae. FNAC of the axillary lymph node was unremarkable. Skin biopsy of the lesion revealed foreign body granulomas in the dermis with septate fungal hyphae, suggestive of aspergillosis. Sputum smears and cultures were negative for acid-fast bacilli and fungi. Cultures of the seropurulent discharge for *Mycobacterium tuberculosis*, atypical mycobacteria and other bacteria did not yield any growth. The pus and tissue fungal culture on Sabouraud's dextrose agar revealed granular, flat colonies with radial grooves. Initially yellow, the colony colour changed to dark yellow-green. Smears from the cultures revealed hyaline septate conidiophores. The vesicle was covered with uniseriate phialides on which globose conidia were seen, diagnostic of *Aspergillus flavus*. Electro-cardiogram and X-rays of the chest, right axilla and skull were normal. X-rays of the paranasal sinuses showed haziness of the maxillary sinuses and CT scan revealed bilateral maxillary and ethmoidal sinusitis. No radiodense concretions were seen. A biopsy from the maxillary sinus mucosa was unremarkable, with negative staining for fungus.

A diagnosis of primary cutaneous aspergillosis was made and the patient was treated with saturated solution of potassium iodide 35 drops 3 times daily for 3 weeks. There was minimal response and after 3 weeks, the treatment was changed to itraconazole 200 mg twice daily. Within the first week of treatment there was up to 25% improvement with reduction in induration and in ulcer size. The treatment was continued for a period of 7 weeks; by that time the induration ulceration and erythema subsided completely. A repeat skin biopsy from the affected site was unremarkable. While on treatment, the patient did not complain of any side-effects attributable to itraconazole therapy. There was no recurrence during 1 year of follow-up.

### DISCUSSION

Primary cutaneous aspergillosis in immunocompetent hosts, as seen in our patient, has been reported in only 5 patients to date (1–5). It is usually caused by *A. flavus* or *A. niger*. Clinically, cutaneous aspergillosis usually appears as erythematous to violaceous papules or plaques that may progress to form necrotic ulcers with a central eschar (6). Unusual cases have been reported resembling lepromatous leprosy (7), mycetoma (8), dermatophytoses (9), purpura, panniculitis and molluscum contagiosum. The nodular subcutaneous lesion in our patient resembled subcutaneous phycomycosis.

Itraconazole, a triazole antimycotic, acts against the fungal cell wall and collects in cytoplasmic vacuoles. Studies have shown a therapeutic response comparable to that of Amphotericin-B with a lower incidence of side-effects (10). Other drugs found to be effective in the treatment of aspergillosis include potassium iodide, 5-fluocytosine, superconazole, fluconazole, terbinafine and granulocyte colony stimulating factor (10). Our patient did not show any response to treatment with potassium iodide, but had complete clearance of the lesion clinically and histopathologically with itraconazole 400 mg, given for 7 weeks. There were no side-effects of the therapy.

### REFERENCES

1. Silva HD, Burke JF, Cho SY. Disseminated aspergillosis in a presumably immunocompetent host. *J Am Med Assoc* 1982; 248: 1495–1497.

2. Handog EB, Nishimoto K, Honma K, Kikitsu K. A case of primary cutaneous aspergillosis of the foot triggered by an orthopedic shoe. *Jap J Med Mycol* 1985; 26: 212–215.
3. Bohler K, Metz D, Poitsscek C, Jurecka W. Cutaneous aspergillosis. *Clin Exp Dermatol* 1990; 15: 446–450.
4. Granstein RD, First LE, Sober AJ. Primary cutaneous aspergillosis in a premature neonate. *Br J Dermatol* 1980; 103: 681–684.
5. Mowad CM, Mguyen TC, Joworsky C, Honig PJ. Primary cutaneous aspergillosis in an immunocompetent child. *J Am Acad Dermatol* 1995; 33: 136–137.
6. Isaac M. Cutaneous aspergillosis. *Dermatol Clin* 1996; 14: 137–140.
7. Cahill KM, El Mofty AM, Kawaguchi TP. Primary cutaneous aspergillosis. *Arch Dermatol* 1967; 96: 545–547.
8. Witzig RS, Greer DL, Hyslop NE Jr. *Aspergillus flavus*;

mycetoma and epidural abscess successfully treated with itraconazole. *J Med Vet Mycol* 1996; 34: 133–137.

9. Googe PB, DeCoste SD, Herold WH, Mihm MC Jr. Primary cutaneous aspergillosis mimicking dermatophytosis. *Arch Pathol Lab Med* 1989; 113: 1284–1286.
10. Georgiev V St. Treatment and developmental therapeutics in aspergillosis. Azoles and other antifungal drugs. *Respiration* 1992; 59: 303–313.

Accepted October 11, 1999.

Shruti Lakhnarpal<sup>1</sup>, R.K. Pandhi<sup>1</sup>, Binod K. Khaitan<sup>1</sup>, Venkateswaran K. Iyer<sup>2</sup> and Uma Bannerjee<sup>3</sup>  
Departments of, <sup>1</sup>Dermatology and Venereology, <sup>2</sup>Pathology and <sup>3</sup>Microbiology, All India Institute of Medical Sciences, New Delhi-110 029, India.

## Asymptomatic Bilateral Optic Perineuritis in Secondary Syphilis

Sir,

The importance of syphilis as a cause of ocular disease has been recognized since 1858 (1); however, over the years, the spectrum of ocular manifestations of this disease has changed, possibly due to the advent of antibiotic therapy (2). Early diagnosis is important, in view of the potentially sight-threatening sequelae of syphilitic eye disease, which strongly suggests involvement of the central nervous system and requires aggressive therapy with high-dose aqueous penicillin (3, 4). In an attempt to increase awareness among dermatologists of this manifestation, we describe here 2 cases of asymptomatic bilateral optic perineuritis in HIV-negative patients with secondary syphilis.

### CASE REPORTS

#### Case 1

A 20-year-old Caucasian female presented with a 2-month history of generalized rash, malaise and fatigue. She denied knowledge of exposure to syphilis and of previous skin lesions on the genital region or elsewhere. She revealed diffuse lymphadenopathy and a generalized

rash consisting of multiple round, indurated, erythematous papules on the palms and soles. These lesions were hyperkeratotic, whereas in the anogenital and buccal regions they were flattened and macerated. Dark-field microscopy of these lesions showed the presence of spirochetes. Routine laboratory investigations revealed a positive (1:10,240) *Treponema pallidum* haemagglutination assay (TPHA). Lumbar puncture showed normal opening cerebrospinal fluid (CSF) pressure, negative syphilis serology and cryptococcal antigen assay, a total protein level of 40 mg/100 ml, a glucose level of 53 mg/100 ml and a white blood cell count of 13/mm<sup>3</sup>.

#### Case 2

A 32-year-old Caucasian female patient presented with a 3-week history of painless, papular lesions in the anogenital region. She denied knowledge of previous exposure to syphilis and any constitutional symptoms.

Her medical history was unremarkable. She revealed several erythematous, painless, oozing papules with partially papillated surface in the anogenital region and a generalized lymphadenopathy. Dark-field microscopy of the lesions showed the presence of spirochetes. Routine laboratory investigations revealed a serum TPHA of 1:2560 and a positive (4+) fluorescent *Treponema pallidum* antibody absorption. Lumbar puncture demonstrated a normal

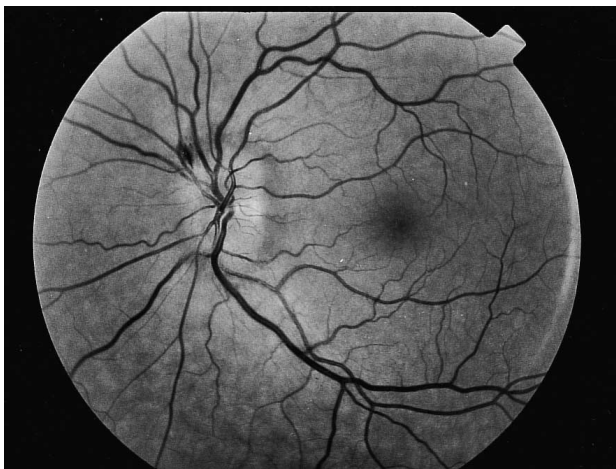

Fig. 1. Blurred optic disc margins and a superficial flame-shaped haemorrhage at 11 o'clock position in the left eye of case 1.

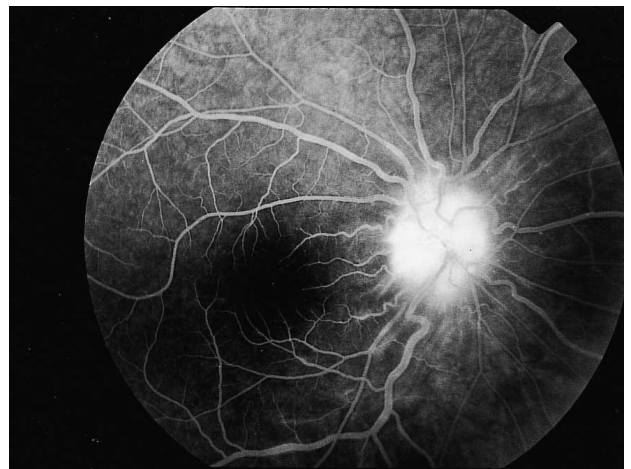


Fig. 2. Fuzzy hyperfluorescence at the optic disc due to leakage from the dilated capillaries in the right eye of case 2.