

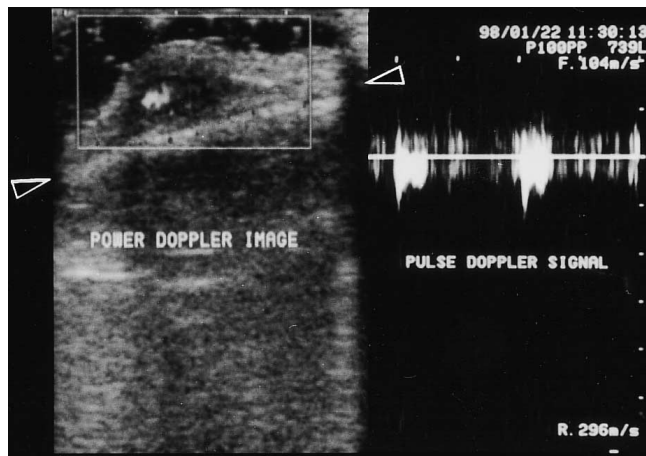Fig. 2. Doppler ultrasound scan of the lesion. Left: power Doppler image. Note the well-defined subcutaneous low echogenic mass with blood flow, indicated by the central whitish area. Cranial bone (arrowhead). Right: pulse Doppler image. Note the pulsatile and arterial flow.

REFERENCES

1. Lewis EC, Southwick EG. Aneurysm of the superficial temporal artery. *Arch Dermatol* 1978; 114: 587–588.
2. Inoue Y, Iwamoto T, Kitoh M, Yoshimura K, Ono T. Traumatic aneurysm of the temporal artery: a report of five cases. *J Dermatol* 1997; 24: 246–248.
3. Han KR, Borah GL. Pseudoaneurysm of the anterior superficial temporal artery. *Ann Plast Surg* 1996; 37: 650–653.
4. Peick AL, Nichols WK, Curtis JJ, Silver D. Aneurysms and pseudoaneurysms of the superficial temporal artery caused by trauma. *J Vasc Surg* 1988; 8: 606–610.
5. Fox JT, Cordts PR, Gwinn BC. Traumatic aneurysm of the superficial temporal artery: case report. *J Trauma* 1994; 36: 562–564.

Accepted August 16, 1999.

Masao Fukuzawa^{1,2} and Toshiaki Saida²

¹Department of Dermatology, Suwa Red Cross Hospital and

²Shinshu University School of Medicine, Asahi 3-1-1, Matsumoto, 390-8621, Japan.

Topical All-trans Retinoic Acid Does not Influence Minimal Erythema Doses for UVB Light in Normal Skin

Sir,

Retinoids are used in several skin disorders, such as acne, psoriasis and ichthyoses. It is well established that retinoids interfere with epidermal proliferation (1, 2), keratinization (3) and inflammation control (4). Retinoids influence UV-induced skin changes (5). Topical all-trans retinoic acid (RA) improves photodamaged skin (5, 6).

Parallel with the therapeutic effect, topical retinoids often cause irritation, with erythema and some scaling (7). Although the irritant effect is probably not involved in the therapeutic action of retinoids, it is possible that the irritation property of all-trans RA could be, in part, accountable for some therapeutic effects (1, 7).

In this study we would like to challenge the common belief that topical retinoids enhance UV-induced inflammation. We therefore evaluated the minimal erythema dose (MED) for UVB irradiation on topical all-trans RA (tretinoin cream 0.05%) pre-treated skin compared with vehicle cream pre-treated skin and untreated skin. The degree of erythema at different times before and after UVB irradiation was scored in the 3 different areas.

The following questions were addressed: (i) To what extent does a 7-day treatment of normal skin with all-trans RA 0.05% in its vehicle or its vehicle alone induce erythema? (ii) To what extent do these creams influence the MED for UV-B irradiation? (iii) What are the dynamics of erythema 24 and 48 h after UVB irradiation in all-trans RA pre-treated skin, vehicle pre-treated skin and untreated skin?

MATERIALS AND METHODS

The study was a single-centre, double-blind, placebo-controlled study. Approval of the Ethics Committee was obtained. A total of 15 healthy volunteers (8 men, 7 women) participated in the study. The mean age was 25 years (range 21–30 years). Their skin types were varying from type I to type III according to Fitzpatrick's classification (8).

An area of 8 × 20 cm on the ventral upper part of one leg was treated twice daily with all-trans RA (tretinoin cream 0.05%), which is a frequently used clinical concentration, for 10 days. An area of the same size on the upper part of the other leg was treated with the vehicle of tretinoin cream (per 100 g: cremor cetomacrogolis 88 g, alcohol ketonatus 12 g and butylhydroxytolueen 40 mg) also twice daily and for 10 days. The application of both creams on the legs was selected at random and was applied in a double-blind manner. From the beginning of the application, until 4 days after the last application of the creams the volunteers were instructed to avoid sunlight exposure and not to wash the area to which the cream was applied for at least 1 h after each application.

On day 8 of treatment, irradiation of the skin was performed in 12 evaluable subjects in order to determine the MED with 3 series of 6 increasing intensities of UVB light related to the skin type of the subjects: 1 series on the all-trans RA cream pre-treated skin, 1 on the vehicle cream pre-treated skin and 1 on non-treated skin on the lateral side of the upper part of one leg. Each dose was given to a piece of skin of 4 cm². For UVB irradiation, UV21 lamps were used.

Before irradiation on days 8, 9 and 10 the skin was examined for erythema by visual scoring. The MED was defined as the lowest UVB dose that caused a distinct erythema with sharp margins over the irradiated area 24 h after irradiation. For erythema the following scale was used: 0=no erythema; 1=weak erythema; 2=moderate

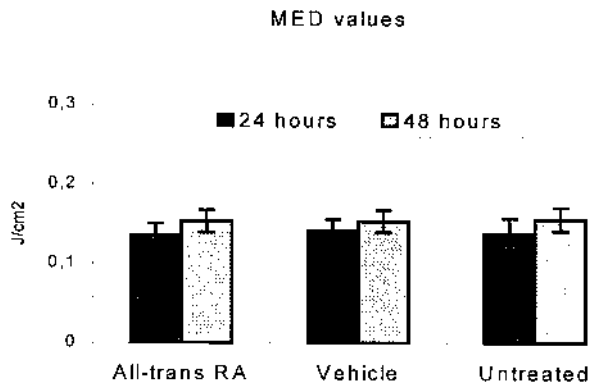


Fig. 1. Minimal erythema doses (mean \pm SEM) for UVB light at test areas treated with all-trans retinoic acid (RA), vehicle and untreated skin 24 and 48 hours after irradiation.

erythema; and 3=strong erythema. Visual scoring occurred under similar conditions of light and temperature.

RESULTS AND DISCUSSIONS

Previous studies showed that erythema induced by topically applied retinoids is frequently seen during the first weeks of treatment and usually subsides with continued treatment. This erythematous reaction is clinically similar to a mild irritant dermatitis (9) and therefore is designated also as 'retinoid dermatitis' (10). In this study the Wilcoxon matched-pairs signed-ranks test showed a significant difference ($p < 0.01$) between all-trans RA cream and its vehicle with respect to the induction of erythema (skin irritation) before UVB irradiation and therefore this study reconfirms the irritative effect of all-trans RA following twice daily applications during 7 days.

Dermatologists tend to avoid all-trans RA applications in conjunction with UV exposure in order to avoid additive irritation. Some studies investigated the relationship between pre-treatment with all-trans RA and UVB irradiation, regarding this expected additive irritation or intensity of erythema (11, 12). However, no data are shown about the question whether all-trans RA can influence the value of the MED for UVB light itself.

The present study showed no significant difference ($p < 0.05$) as to MED values either 24 or 48 h after UVB irradiation between the all-trans RA cream treated skin, the vehicle cream treated skin and untreated skin (Fig.1) using the ANOVA test. When looking at the relationship between skin type and MED value a significant higher MED value was found in skin type 3 vs. skin type 1 and 2 ($p < 0.01$).

As both all-trans RA cream and the vehicle cream in itself can induce erythema of the skin, it might be difficult to grade post UVB irradiation erythema in retinoid-treated areas. However, a marked difference was found in erythema pattern between cream-induced erythema and UVB-induced erythema. UVB-induced erythema showed a diffuse erythema, while (especially all-trans RA) cream-induced erythema showed a marked erythema restricted to the perifollicular areas. This perifollicular pattern may be related to the actions of all-trans RA on the pilosebaceous duct and can also be seen with other irritants, e.g. glycolic acid (13). These 2

distinct patterns of erythema permitted us to score both parameters independently and separately.

The present study shows that topical treatment with all-trans RA does not influence the response to a single exposure to UVB light and does not change the MED.

REFERENCES

- Marks R, Hill S, Barton SP. The effects of an abrasive agent on normal skin and on photoaged skin in comparison with topical tretinoin. *Br J Dermatol* 1990; 123: 457–466.
- Griffiths CEM, Voorhees JJ, Nickoloff BJ. Characterisation of intercellular adhesion molecule-1 (ICAM-1) and HLA-DR in normal and inflamed skin: Modulation by recombinant gamma-interferon and tumor necrosis factor. *J Am Acad Dermatol* 1989; 20: 617–629.
- Fry L, MacDonald A, McMinn RM. Effects of retinoic acid in psoriasis. *Br J Dermatol* 1970; 83: 391–396.
- Bradshaw D, Cashin CH, Kennedy AJ. Anti-inflammatory effects of the retinoids. In: Cunliffe WJ, Miller AJ (eds.). *Retinoid therapy*. Lancaster 1984, MTP Press: 335–343.
- Kligman AM, Grove GL, Hirose R, Leyden JJ. Topical tretinoin for photoaged skin. *J Am Acad Dermatol* 1986; 15: 836–859.
- Griffiths CEM, Goldfarb MT, Finkel LJ, Roulia V, Bonawitz M, Hamilton TA, et al. Topical tretinoin (retinoic acid) treatment of hyperpigmented lesions associated with photoaging in Chinese and Japanese patients: a vehicle-controlled trial. *J Am Acad Dermatol* 1994; 30: 76–84.
- Fullerton A, Serup J. Characterisation of irritant patch test reactions to topical D vitamins and all-trans retinoic acid in comparison with sodium lauryl sulphate. Evaluation by clinical scoring and multiparameter non-invasive measuring techniques. *Br J Dermatol* 1997; 137: 234–240.
- Madhu P, Nghiem P, Fitzpatrick TB. Acute and chronic effects of the sun. In: Freedberg I, Eisen AZ, Wolff K, Austen KF, Goldsmith LA, Katz SI, et al. *Fitzpatrick's dermatology in general medicine*. New York: McGraw-Hill, 1999: 1606.
- Fisher GJ, Esmann J, Griffiths CEM, Talwar HS, Duell EA, Hammerberg C, et al. Cellular, immunologic and biochemical characterisation of topical retinoic acid-treated human skin. *J Invest Dermatol* 1991; 96: 699–707.
- Shalita A, Weiss JS, Chalker DK, Ellis CN, Greenspan A, Katz HI, et al. A comparison of the efficacy and safety of adapalene gel 0.1% and tretinoin gel 0.025% in the treatment of acne vulgaris: a multicenter trial. *J Am Acad Dermatol* 1996; 34: 482–485.
- Juhlin L, Shroet B. Intensity and area increase of UVB-induced erythema: two variables used for studies of the influence of topically applied drugs. *Acta Derm Venereol* 1993; 73: 273–275.
- Meunier L, Voorhees JJ, Cooper KD. In vivo retinoic acid modulates expression of the class II major histocompatibility complex and function of antigen-presenting macrophages and keratinocytes in ultraviolet-exposed human skin. *J Invest Dermatol* 1996; 106: 1042–1046.
- Effendy I, Kwangstuth C, Lee JY, Maibach HI. Functional changes in human stratum corneum induced by topical glycolic acid: comparison with all-trans retinoic acid. *Acta Derm Venereol* 1995; 75: 455–458.

Accepted August 10, 1999.

J. V. Smit, E. M. G. J. de Jong, G. J. de Jongh and P. C. M. van de Kerkhof
 Department of Dermatology, University Hospital Nijmegen,
 PO Box 9101, 6500 HB Nijmegen, The Netherlands.
 E-mail: j.smit@derma.azn.nl