

## Pseudoaneurysm of the Superficial Temporal Artery

Sir,

We report here the case of a man with pseudoaneurysm of the superficial temporal artery, triggered by a blunt trauma to the right temporal area. Doppler ultrasound scan disclosed fusiform dilatation of this artery and arterial blood flow within the aneurysm. Since the first report of a pseudoaneurysm of the temporal artery (1), there has been only scant mention of this condition in the literature; only 6 cases have been reported so far (2).

### CASE REPORT

The patient was a 65-year-old Japanese man with no significant past medical history. He had been struck bluntly on the right side of his forehead in December 1997, resulting in a large contusion of this area, which subsided within 2 weeks, leaving a small, pulsatile nodule. In January 1998, 6 weeks after the accident, the patient noticed that he had a painful mass on the right side of his forehead. The mass did not expand, though he felt a little discomfort. On examination, a 10 × 10 × 5 mm pulsatile and spherical mass was found on the right side of his forehead, located in the course of the anterior branch of the superficial temporal artery (Fig. 1). The pulsations of the mass disappeared with pressure on the afferent portion of the superficial temporal artery. The skin could be moved easily over the lesion. A Doppler ultrasound scan of the lesion showed a fusiform dilatation of the superficial temporal artery measuring 8 mm in maximum diameter with turbulent and arterial flow (Fig. 2). A diagnosis of superficial temporal artery aneurysm was made. There was no evidence of arteriovenous fistula. The aneurysm was excised under local anaesthesia, with ligation of the proximal and distal ends of the lesion. The postoperative course of the patient was uneventful. Histopathological examination of the resected lesion revealed a medium-sized artery with a large area of nodular fibrosis attached to the vessel wall adjacent to connective tissue with neovascularization, confirming the diagnosis of arterial pseudoaneurysm.

### DISCUSSION

Muscle tissue can cushion vessels against traumatic pressures. However, there is a gap between the frontal and temporal muscles, and the anterior branch of the temporal artery transverses the lateral border of this frontal muscle. Thus, in this area, the artery is susceptible to traumatic injury (3). In this particular patient, the aneurysm first manifested itself clinically 6 weeks after the initial trauma. In previous reports also, traumatic aneurysm mostly appeared within 1–6 weeks. Most superficial temporal artery aneurysms caused by trauma are pseudoaneurysms (4). A pseudoaneurysm is defined as one in which the lumen is not surrounded by all three layers of the arterial wall. The mechanism of aneurysmal formation may be as follows; the haemorrhage and haematoma, resulting from blunt damage to the superficial temporal artery, are progressively organized, so that a fibrous pseudocapsule is formed. In the course of absorption and organization of the haematoma, the pulsatile symptom appears with recanalization of the hematoma. Therefore, in the case with insufficient recanalization, the aneurysm may be non-pulsatile (5).

This type of aneurysm can be suspected by both history and physical examination. Compression of the proximal artery will diminish the pulsation or make it disappear altogether. The differential diagnoses includes other pulsatile lesions,

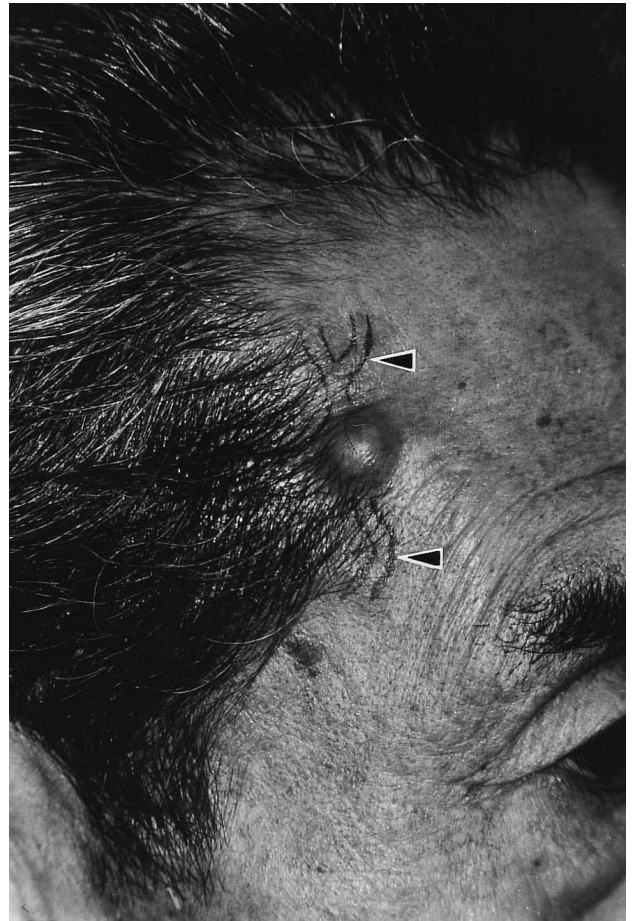


Fig. 1. Clinical appearance of the pseudoaneurysm of the superficial temporal artery (arrowheads). Note the hemispherical mass on the right side of the forehead.

such as arteriovenous fistula, vascular tumours, and aneurysm of the middle meningeal artery with erosion of the temporal bone, and non-pulsatile lesions, such as epidermal inclusion cyst, haematoma, lipoma, neuroma, and abscess overlying the temporal artery (3, 4). Dermatologists should be aware of these differential diagnoses, especially intracranial disease. Angiography or CT scan is needed in the case of suspicion of intracranial lesion (4, 5). The most accurate non-invasive and safe modality to aid in the diagnosis is Doppler ultrasound scan examination, which shows the native vessel along with a fusiform dilatation and turbulent intraluminal arterial flow. Our case is the first demonstration of the usefulness of pulse Doppler image and non-invasive method.

Surgery is the recommended treatment for pseudoaneurysm of the superficial temporal artery. It reduces the risk of haemorrhage from subsequent trauma, relieves headache, and resolves the cosmetic defect of the lesion. Spontaneous rupture of the aneurysm has been reported (4). The technique is to excise the pseudoaneurysm along with ligation of the afferent and efferent vessels under local anaesthesia. In rare cases, resection under general anaesthesia, compression and/or embolization are indicated (3, 4). Han & Borah stated that there was no need to reconstruct the superficial temporal artery after excision of an aneurysm or pseudoaneurysm (3).

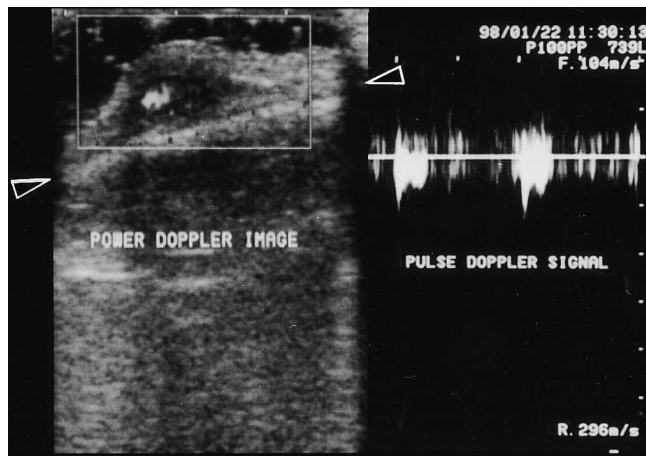


Fig. 2. Doppler ultrasound scan of the lesion. Left: power Doppler image. Note the well-defined subcutaneous low echogenic mass with blood flow, indicated by the central whitish area. Cranial bone (arrowhead). Right: pulse Doppler image. Note the pulsatile and arterial flow.

## REFERENCES

1. Lewis EC, Southwick EG. Aneurysm of the superficial temporal artery. *Arch Dermatol* 1978; 114: 587–588.
2. Inoue Y, Iwamoto T, Kitoh M, Yoshimura K, Ono T. Traumatic aneurysm of the temporal artery: a report of five cases. *J Dermatol* 1997; 24: 246–248.
3. Han KR, Borah GL. Pseudoaneurysm of the anterior superficial temporal artery. *Ann Plast Surg* 1996; 37: 650–653.
4. Peick AL, Nichols WK, Curtis JJ, Silver D. Aneurysms and pseudoaneurysms of the superficial temporal artery caused by trauma. *J Vasc Surg* 1988; 8: 606–610.
5. Fox JT, Cordts PR, Gwinn BC. Traumatic aneurysm of the superficial temporal artery: case report. *J Trauma* 1994; 36: 562–564.

Accepted August 16, 1999.

Masao Fukuzawa<sup>1,2</sup> and Toshiaki Saida<sup>2</sup>

<sup>1</sup>Department of Dermatology, Suwa Red Cross Hospital and

<sup>2</sup>Shinshu University School of Medicine, Asahi 3-1-1, Matsumoto, 390-8621, Japan.

## Topical All-trans Retinoic Acid Does not Influence Minimal Erythema Doses for UVB Light in Normal Skin

Sir,

Retinoids are used in several skin disorders, such as acne, psoriasis and ichthyoses. It is well established that retinoids interfere with epidermal proliferation (1, 2), keratinization (3) and inflammation control (4). Retinoids influence UV-induced skin changes (5). Topical all-trans retinoic acid (RA) improves photodamaged skin (5, 6).

Parallel with the therapeutic effect, topical retinoids often cause irritation, with erythema and some scaling (7). Although the irritant effect is probably not involved in the therapeutic action of retinoids, it is possible that the irritation property of all-trans RA could be, in part, accountable for some therapeutic effects (1, 7).

In this study we would like to challenge the common belief that topical retinoids enhance UV-induced inflammation. We therefore evaluated the minimal erythema dose (MED) for UVB irradiation on topical all-trans RA (tretinoin cream 0.05%) pre-treated skin compared with vehicle cream pre-treated skin and untreated skin. The degree of erythema at different times before and after UVB irradiation was scored in the 3 different areas.

The following questions were addressed: (i) To what extent does a 7-day treatment of normal skin with all-trans RA 0.05% in its vehicle or its vehicle alone induce erythema? (ii) To what extent do these creams influence the MED for UV-B irradiation? (iii) What are the dynamics of erythema 24 and 48 h after UVB irradiation in all-trans RA pre-treated skin, vehicle pre-treated skin and untreated skin?

## MATERIALS AND METHODS

The study was a single-centre, double-blind, placebo-controlled study. Approval of the Ethics Committee was obtained. A total of 15 healthy volunteers (8 men, 7 women) participated in the study. The mean age was 25 years (range 21–30 years). Their skin types were varying from type I to type III according to Fitzpatrick's classification (8).

An area of 8 × 20 cm on the ventral upper part of one leg was treated twice daily with all-trans RA (tretinoin cream 0.05%), which is a frequently used clinical concentration, for 10 days. An area of the same size on the upper part of the other leg was treated with the vehicle of tretinoin cream (per 100 g: cremor cetomacrogolis 88 g, alcohol ketonatus 12 g and butylhydroxytolueen 40 mg) also twice daily and for 10 days. The application of both creams on the legs was selected at random and was applied in a double-blind manner. From the beginning of the application, until 4 days after the last application of the creams the volunteers were instructed to avoid sunlight exposure and not to wash the area to which the cream was applied for at least 1 h after each application.

On day 8 of treatment, irradiation of the skin was performed in 12 evaluable subjects in order to determine the MED with 3 series of 6 increasing intensities of UVB light related to the skin type of the subjects: 1 series on the all-trans RA cream pre-treated skin, 1 on the vehicle cream pre-treated skin and 1 on non-treated skin on the lateral side of the upper part of one leg. Each dose was given to a piece of skin of 4 cm<sup>2</sup>. For UVB irradiation, UV21 lamps were used.

Before irradiation on days 8, 9 and 10 the skin was examined for erythema by visual scoring. The MED was defined as the lowest UVB dose that caused a distinct erythema with sharp margins over the irradiated area 24 h after irradiation. For erythema the following scale was used: 0=no erythema; 1=weak erythema; 2=moderate