

- general medicine, 5th edn. New York: McGraw-Hill, 1995: 746–748.
2. Miyachi Y, Horio T, Yamada A, Ueo T. Linear melorheostotic scleroderma with hypertrichosis. *Arch Dermatol* 1979; 115: 1233–1234.
  3. Chabot J, Faulong L. Melorheostosis with stripe-shaped cutaneous sclerosis and localized hypertrichosis. *Rev Rhum Mal Osteoartic* 1966; 33: 274–275.
  4. Wagers LT, Young AW Jr, Ryan SF. Linear melorheostotic scleroderma. *Br J Dermatol* 1972; 86: 297–301.
  5. Morris JM, Samilson RL, Corley CL. Melorheostosis: review of the literature and report of an interesting case with a 19-year follow-up. *J Bone Joint Surg Am* 1963; 45: 1191–1206.
  6. Campbell CJ, Papademetriou T, Bonfiglio M. Melorheostosis. *J Bone Joint Surg* 1968; 50A: 1281–1304.
  7. Muller SA, Henderson ED. Melorheostosis with linear scleroderma. *Arch Dermatol* 1963; 88: 142–145.
  8. Soffa DJ, Sire DJ, Dodson JH. Melorheostosis with linear sclerodermatous skin changes. *Radiology* 1975; 114: 577–578.
  9. Mehregan AM, Hashimoto K, Mehregan DA, Mehregan DR. *Pinkus' guide to dermatohistopathology*, 6th edn. New Jersey: Prentice-Hall International Inc., 1995: 27–29.

Accepted July 14, 1999.

Bum-Jin Juhn, Yang-Hoon Cho and Mu-Hyoung Lee  
Department of Dermatology, College of Medicine, Kyunghee University, 1 Hoegi-Dong, Dongdaemun-Ku, Seoul, 130-702, Korea.  
E-mail: pibu@nuri.net

## Eosinophil Activation in Wells' Syndrome Demonstrated Immunohistochemically with Antibodies Against Eosinophilic Cationic Protein

Sir,

The important role of the eosinophilic granulocyte has been recognized in a number of skin disorders. The mediators released are especially important in defence against parasites and bacteria, but the toxic proteins may also cause damage to keratinocytes (1). The number of eosinophilic granulocytes in peripheral blood and tissue has been reported to correlate well with clinical severity in disorders such as allergic bronchial asthma, allergic rhinitis and atopic eczema (2). The clinical effects are thought to be mediated partly through cationic proteins released from the eosinophils (3). The granules in the eosinophilic granulocytes have been shown to contain 4 predominant cationic molecules with cytotoxic properties, including eosinophilic peroxidase, major basic protein, eosinophilic cationic protein and eosinophil-derived neurotoxin (4).

Recurrent granulomatous dermatitis with eosinophilia was first described by Wells in 1971 (5). Typically, single or multiple lesions erupt on a limb, the face or the trunk, after a short prodromal itching or burning, and blistering may occur. The skin is usually restored after a few weeks, although recurrences over many years are common (6).

Histopathologically, different stages have been described; in the acute stage the dermis is infiltrated with leukocytes, especially eosinophils, and shows oedema. In the subacute phase histiocytes together with eosinophils adhering to collagen bundles ("flame figures") dominate the picture, and in the later stage microgranulomas with histiocytes are present (7, 8).

In order to investigate the role of eosinophilic proteins in Wells' syndrome, biopsies from 2 patients with this rare skin disorder were reacted immunohistochemically with antibodies against the eosinophilic proteins eosinophil-derived neurotoxin, eosinophilic peroxidase and eosinophilic cationic protein.

### PATIENTS AND METHODS

#### Patient 1

A 12-year-old boy presented at the department with bluish-erythematous infiltrations on his trunk and extremities of 1–5 cm in diameter. There were no general symptoms, no fever, but marked

peripheral blood eosinophilia ( $550 \times 10^9/l$ ). Histopathological investigation of a 3-mm punch biopsy revealed infiltration of eosinophilic granulocytes around vessels, but also between collagen fibres and extending down to the subcutaneous tissue. Together with the clinical picture, an early stage of eosinophilic cellulitis was diagnosed. As he did not suffer from general symptoms, he was observed, and on the clinical follow-up after 3 weeks presented only post-inflammatory hyperpigmentations.

#### Patient 2

A 43-year-old woman had experienced erythematous papules and dermal nodules on the face for about 12 months, associated with fever, malaise and peripheral blood eosinophilia ( $460 \times 10^9/l$ ). The histopathological investigation of a 4-mm punch biopsy specimen showed a diffuse and perivascular infiltration of lymphocytes, histiocytes, and numerous eosinophils. In one section neutrophilic and eosinophilic granulocytes centred around a granular eosinophilic degenerated material, consistent with flame figures were seen. In all, and considering the clinical course, a subacute stage of eosinophilic cellulitis was diagnosed. She received treatment with oral steroids starting with 30 mg daily for 4 weeks, and after 1 month showed only scattered erythematous macules on the face, but no dermal nodules or infiltration.

#### Immunohistochemical procedure

Immunohistochemistry was performed on sections from the formalin-fixed, paraffin-embedded biopsies from these 2 patients. Serial sections 6  $\mu$ m thick were de-waxed, trypsinated and incubated for 12 h at room temperature with antibodies against eosinophilic cationic protein (ECP; EG-2, dilution 1/320; Pharmacia, Sweden), and with antibodies against eosinophilic peroxidase and eosinophil-derived neurotoxin (both kindly supplied by Pharmacia, Sweden). After washing, antigen localization was accomplished by the alkaline phosphatase-anti-alkaline phosphatase (APAAP) method (9), using the APAAP-complex (Dakopatts, Denmark) in dilution 1/40. The sections were counterstained with haematoxylin and mounted in Apathy's mounting medium (RA Lamb Lab., London, UK).

### RESULTS AND DISCUSSION

In the conventional histopathology, eosinophils were seen extending into the subcutaneous tissue in patient 1, and in the dermis and around vessels in patient 2. Immunohistologically,

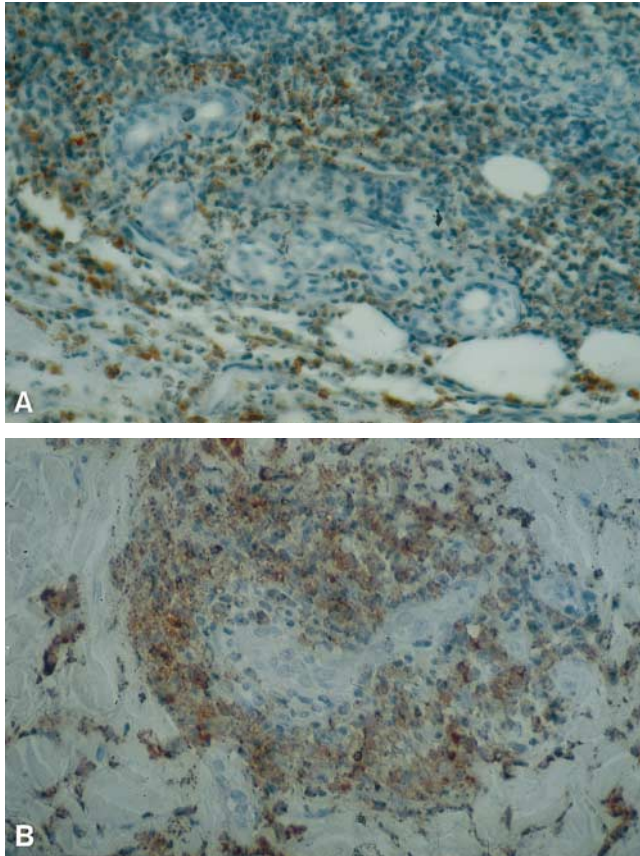


Fig. 1. Immunohistochemical procedure on formalin-fixed, paraffin-embedded material with antibodies against eosinophilic cationic protein, (a) showing that the majority of the eosinophils expressed this marker of activation and (b) demonstrating deposition of the antibodies in the intercellular matrix, pointing towards activation with subsequent degranulation of the eosinophils.

the majority of the eosinophil cells expressed eosinophilic cationic protein (Fig. 1a from patient 1), and there was also considerable deposition of the antibodies in the intercellular matrix (Fig. 1b from patient 2), pointing towards activation of the eosinophils with subsequent degranulation.

No reactivity was observed towards the other 2 antibodies.

Earlier investigations have shown that, in biopsies from patients with Wells' syndrome that are reacted with antibodies against major basic protein, the pattern of the extracellular staining corresponded to the configuration of flame figures (10). The characteristic flame figures are believed to represent eosinophil activity and degranulation (8, 11). In our material, flame figures were detected in 1 section in the routine-histopathological investigation, but sections were unfortunately not available for immunohistochemistry.

Flame figures are, however, not pathognomonic for Wells' syndrome, and may also be seen in other disorders with eosinophil infiltration (12).

A correlation between clinical activity, eosinophils in blood and bone marrow, and ECP and IL-5 levels in peripheral

blood and tissues of patients with Wells' syndrome was reported recently (13).

In conclusion, we demonstrate eosinophilic cationic protein in the eosinophils and in the tissue where there is eosinophil infiltration, thus indicating the important role of eosinophils and their proteins in the pathogenesis of dermatoses with eosinophil infiltration, and Wells' syndrome.

#### REFERENCES

1. Gleich GJ, Adolphson CR, Leiferman KM. The biology of the eosinophilic leukocyte. *Annu Rev Med* 1993; 44: 85–101.
2. Ring J, Bieber T, Vieluf D, Kunz B, Przybilla B. Atopic eczema, Langerhans cells and allergy. *Int Arch Allergy Appl Immunol* 1991; 94: 194–201.
3. Kägi MK, Joller-Jemelka H, Wüthrich B. Correlation of eosinophils, eosinophil cationic protein and soluble interleukin-2 receptor with the clinical activity of atopic dermatitis. *Dermatology* 1992; 185: 88–92.
4. Venge P, Dahl R, Hällgren R, Olsson I. Cationic proteins of human eosinophils and their role in the inflammatory reaction. In: Mahmoud AAF, Austen KF (eds). *The eosinophil in health and disease*, New York: Grune and Stratton: 131–144.
5. Wells GC. Recurrent granulomatous dermatitis with eosinophilia. *Trans St Johns Hosp Dermatol Soc* 1971; 57: 46–56.
6. Fisher GB, Greer KE, Cooper PH. Eosinophilic cellulitis (Wells' syndrome). *Int J Dermatol* 1985; 24: 101–107.
7. Wood C, Miller AC, Jacobs A, Hart R, Nickoloff BJ. Eosinophilic infiltration with flame figures. A distinctive tissue reaction seen in Wells' syndrome and other diseases. *Am J Dermatopathol* 1986; 8: 186–193.
8. Brehmer-Andersson E, Kaaman T, Skog E, Frithz A. The histopathogenesis of the flame figure in Wells' syndrome based on five cases. *Acta Derm Venereol* 1986; 66: 213–219.
9. Cordell JL, Falini B, Erber WN, Ghosh AK, Abdulaziz Z, MacDonald S, et al. Immunoenzymatic labelling of monoclonal antibodies using immune complexes of alkaline phosphatase and monoclonal anti-alkaline phosphatase (APAAP complexes). *J Histochem Cytochem* 1984; 2: 219–229.
10. Peters MS, Schroeter AL, Gleich GJ. Immunofluorescence identification of eosinophil granule major basic protein in the flame figures of Wells' syndrome. *Br J Dermatol* 1983; 109: 141–148.
11. Stern JB, Sobel HJ, Rotchford JP. Wells' syndrome: is there collagen damage in the flame figures? *J Cutan Pathol* 1984; 11: 501–505.
12. Melski JW. Wells' syndrome, insect bites, and eosinophils. *Dermatol Clin* 1990; 8: 287–293.
13. Espana A, Sanz ML, Sola J, Gil P. Wells' syndrome (eosinophilic cellulitis): correlation between clinical activity, eosinophil levels, eosinophil cation protein and interleukin-5. *Br J Dermatol* 1999; 140: 127–130.

Accepted August 10, 1999.

Edgar Selvaag<sup>1</sup> and Borghild Roald<sup>2</sup>

<sup>1</sup>Department of Dermatology, University of Copenhagen, Bispebjerg Hospital, Bispebjerg Bakke 23, DK-2400 Copenhagen NV, Denmark and <sup>2</sup>Department of Pathology, Ullevaal Hospital, University of Oslo, Norway.