

## DISCUSSION

Based on the findings presented here we recommend that *H. pylori* diagnosis is included in the laboratory work-up of CU, preferably using the high valid [<sup>13</sup>C]-urea breath test. Detection of circulating specific IgG and/or IgA antibodies against *H. pylori* does not necessarily indicate ongoing infection and titres may remain positive even after successful eradication therapy (9, 10).

From a review of the literature, there is evidence that *H. pylori* eradication therapy leads to a remission rate in CU of 29–100%, indicating a causal relationship (1–5, 11). However, a recent study reported only a 10% remission rate of CU, although *H. pylori* was successfully eradicated in most of the cases (12). In our opinion *H. pylori*-infected patients with CU should receive therapy for eradication of *H. pylori*. However, other possible causes of disease should be sought and treated. In addition, one should bear in mind that it cannot be excluded that *H. pylori* therapy leads to eradication of an occult, otherwise undiagnosed, bacterial infection.

The pathophysiological role of *H. pylori* in CU remains an enigma. Based on our current knowledge of *H. pylori* interactions with the stomach mucosa, 2 hypotheses may be discussed: firstly, *H. pylori* was shown to have a toxic effect on the mucosa cells, where the pathogen is able to induce interleukin 8 (IL-8) mRNA expression. IL-8 as well as urease and lipopolysaccharides, both secreted by *H. pylori*, may induce attraction of neutrophilic granulocytes, which are able to destroy the mucosa barrier via oxidative stress and proteolytic enzymes (13, 14). Penetration of food allergens/pseudoallergens may be promoted by this toxic cell damage. This hypothesis is supported by the fact that *H. pylori* is not an occult infection in patients with CU; it led to symptoms of chronic gastritis in all our patients. The other possibility is that *H. pylori* may be able to induce some unknown IgE-mediated or non-IgE-mediated immunomechanism, leading to urticaria disease. Experimental evidence supporting this concept demonstrated the presence of specific IgE directed against *H. pylori* on basophils and in sera (15).

## REFERENCES

1. Tebbe B, Geilen CC, Schulzke JD, Bojarski C, Radenhausen M, Orfanos CE. Helicobacter pylori infection and chronic urticaria. *J Am Acad Dermatol* 1996; 34: 685–686.
2. Kolibasova K, Cervenkova D, Hegyi E, Lengyelova J, Toth J. Helicobacter pylori: ein möglicher ätiologischer Faktor der chronischen Urticaria. *Dermatosen* 1994; 42: 235–236.
3. Bohmeyer J, Heller A, Hartig C, Westenberger-Treumann M, Huchzermeyer H, Otte HG, et al. Assoziation der chronischen Urtikaria mit Helicobacter pylori-induzierter Antrum-Gastritis. *Hautarzt* 1996; 47: 106–108.
4. Di Campli C, Gasbarrini A, Nucera E, Franceschi F, Ojetti V, Sanz Torre E, et al. Beneficial effects of Helicobacter pylori eradication on idiopathic chronic urticaria. *Dig Dis Sci* 1999; 43: 1226–1229.
5. Özkaya-Bayazit E, Demir K, Özgüroglu E, Kaymakoglu S, Özarmagan G. Helicobacter pylori eradication in patients with chronic urticaria. *Arch Dermatol* 1999; 134: 1165–1166.
6. Halasz CLG. Helicobacter pylori antibodies in patients with psoriasis. *Arch Dermatol* 1996; 132: 95–96.
7. Mégraud F. Epidemiology of Helicobacter pylori infection. *Gastroenterol Clin North Am* 1993; 22: 1870–1873.
8. Eggers RH, Kulp A, Tegeler R. A methodological analysis of the <sup>13</sup>C-urea breath test for detection of Helicobacter pylori infections: high sensitivity and specificity within 30 min using 75mg of <sup>13</sup>C-urea. *Eur J Gastroenterol* 1990; 2: 437–444.
9. Caspary WF, Arnold R, Bayerdörffer E, Behrens R, Birkner B, Braden B, et al. Diagnostik und Therapie der Helicobacter pylori Infektion. *Z Gastroenterol* 1996; 34: 392–402.
10. Cutler AF, Prasad VM. Long-term follow-up of Helicobacter pylori serology after successful eradication. *Am J Gastroenterol* 1996; 91: 85–88.
11. Wedi B, Wagner S, Werfel T, Manns MP, Kapp A. Prevalence of Helicobacter pylori-associated gastritis in chronic urticaria. *Int Arch Allergy Immunol* 1999; 116: 228–294.
12. Valsecchi R, Pigatto P. Chronic urticaria and Helicobacter pylori. *Acta Derm Venerol* 1998; 78: 440–442.
13. Mégraud F. Toxic factors of Helicobacter pylori. *Eur J Gastroenterol Hepatol* 1994; 6: S5–S10.
14. Crabtree JE. Immune and inflammatory responses to Helicobacter pylori infection. *Scand J Gastroenterol* 1996; 31 Suppl 215: 3–10.
15. Aceti A, Celestino D, Caferro M, Casale V, Citarda F, Conti EM, et al. Basophil-bound and serum immunoglobulin E directed against Helicobacter pylori in patients with chronic gastritis. *Gastroenterology* 1991; 101: 131–137.

Accepted June 18, 1999.

Michael Radenhausen<sup>1</sup>, Jörg-Dieter Schulzke<sup>2</sup>, Christoph C. Geilen<sup>1</sup>, Ulrich Mansmann<sup>3</sup>, Regina Treudler<sup>1</sup>, Christian Bojarski<sup>2</sup>, Constantin E. Orfanos<sup>1</sup> and Beate Tebbe<sup>1</sup>  
Departments of <sup>1</sup>Dermatology, <sup>2</sup>Gastroenterology and <sup>3</sup>Medical Statistics and Informatics, University Medical Center Benjamin Franklin, The Free University of Berlin, Hindenburgdamm 30, D-12200 Berlin, Germany

## Perianal Ulcer as a Leading Symptom of Paediatric Langerhans' Cell Histiocytosis

Sir,

Langerhans' cell histiocytosis (recently termed Langerhans' cell granulomatosis) is a clonal tumour-like proliferative disease of Langerhans' cells. Positivity for HLA-DR, S-100 and CD1a, as well as the presence of Birbeck granules seen by electronmicroscopy is characteristic of these cells (1). The process affects different tissues and organs, and can be manifested either as a single lesion or as a multisystemic

disease (2, 3). The course of the disease varies from an acute disseminated lethal form via benign forms with a chronic course to spontaneous healing (4, 5). Skin symptoms are important diagnostics features, which occur in 50–80% of patients with Langerhans' cell histiocytosis (6, 7). We describe here a case of paediatric Langerhans' cell histiocytosis in which perianal ulcer was a leading symptom.

## CASE REPORT

A 2-year-old boy was treated for mild seborrhoeal dermatitis of the glabrous skin persisting since birth. The patient was admitted for perianal alterations that had developed several months before and had caused hardly any complaints. He was a normally developed child of adequate nutritional status. Discrete crusted and scaling yellowish-brown papules 2–3 mm in diameter, eroded on the flexure areas, occurred on the glabrous skin, inguinal fossa, abdomen and gluteal area. A superficial, slightly discharging, pale pink perianal ulcer with infiltrated edges 1.5 cm in diameter was found (Fig. 1). The mucosa was unaffected. Physical examination revealed only minor hepatosplenomegaly.

*Test results*

The specific gravity of spontaneously emptied urine was 1005. Mild anaemia and minor eosinophilia (8%) was seen. There were no changes in other laboratory values. RPR reaction was negative. Skull CT showed a CSF space of normal size and localization; routine scans revealed no pathological alterations in the brain. Bone destruction of 1.5 × 2.6 cm in diameter was detected at the top of the right orbit; 2 loci of lesions (6 mm each) were seen in the calvaria and a destructive area with sharp edges (12 mm in diameter) in the vertex. The latter lesion was of button-like appearance exhibiting regions of internal pseudosequestration. X-ray of the extremities showed no alterations in the tubular bone structure. Chest CT revealed central accumulation of the connective tissue. A lymph node 6 mm in diameter was found in the angle between the aorta and the vena cava. Abdominal ultrasound showed that liver was enlarged by 1.0 cm, slightly echodense and homogenous. Scintigraphy revealed hepatosplenomegaly and diffuse lesions of the parenchyma. Examination of the eyes showed normal papilla, with vessels showing average filling. Histological study of the edge of the ulcer showed a marked, diffuse infiltration with heterogeneous inflammatory cells, predominantly large, histiocyte-like cells with light-coloured cytoplasm both on the surface of the ulcer and under the intact epithelium. Other cells were lymphocytes, neutrophil granulocytes, eosinophils and mastocytes. Immunohistology results were CD1a+++; S-100 protein+++ (Fig. 2). Electron microscopic study did not reveal any Birbeck granules in the paraffin-embedded sections.

After therapy with low-dose steroids (10 mg prednisolone daily), external agents stimulating epithelization, and antiseborrhoeal treatment, the perianal ulcer sloughed off and seborrhoeal dermatitis was healed. Two months later a control skull X-ray study showed regression.

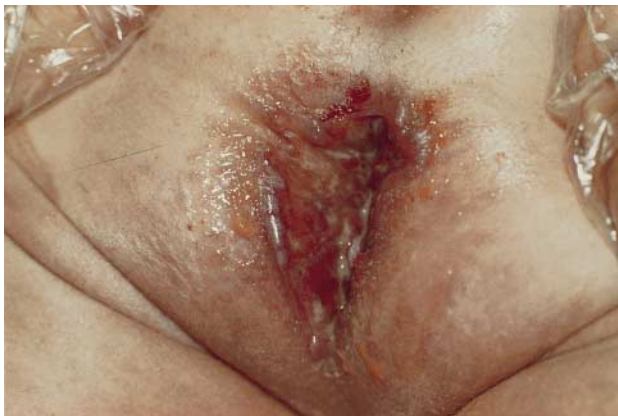

Fig. 1. Superficial perianal ulcer in Langerhans-cell histiocytosis.

## DISCUSSION

The clinical picture of Langerhans' cell histiocytosis showed marked heterogeneity that is due to localization, extent, and organ dysfunction of the disease (6, 7). As a rule the process affects bones (skull), and is extended to the glabrous skin, liver, spleen, lung, bone marrow, lymphatic nodes and the CNS (7). Cutaneous symptoms occur mainly in infants and children and usually affect the glabrous skin, as well as the abdominal, gluteal, and intertriginous areas. The classic seborrhoeic symptoms comprise skin lesions of yellowish-brownish colour, with a scaly or crusty surface. Papulous or papulo-ulcerous symptoms with characteristic haemorrhages either appear in groups or are disseminated.

Persistent, erosive or granulomatous-ulcerous symptoms typically develop in the intertriginous areas (behind the ears, in the armpits, groins and perianal area). In rare cases, solitary, cutaneous or subcutaneous nodes can develop; those localized in the genital, perigenital and perianal areas are prone to ulceration. Cases of ulceration of intertriginous and genital areas as a sole sign of the disease are documented in the literature (3). It is noteworthy that ulcers of the buccal mucosa, mainly the gingiva and the palate, are of diagnostic value.

In the case described here the perianal ulcer was the only symptom of the disease. The diagnostic value of such ulcers in infants and children (and in rare cases in adults) is of utmost importance. Therefore, presence of chronic ulcers that affect the perianal, genital or other intertriginous areas in children under 3 years of age, should always be taken to imply a possibility of Langerhans' cell histiocytosis. It should be emphasized that these ulcers have no differential diagnostic value in different forms of Langerhans' cell histiocytosis, because they can occur in congenital and acquired spontaneously healing forms, as well as in benign and malignant forms of Letterer-Siwe's syndrome.

## ACKNOWLEDGEMENT

We thank Professor Szabolcs Virág (Department of Pathology, Haynal Imre Medical University of postgraduate training) for electron microscopy studies.

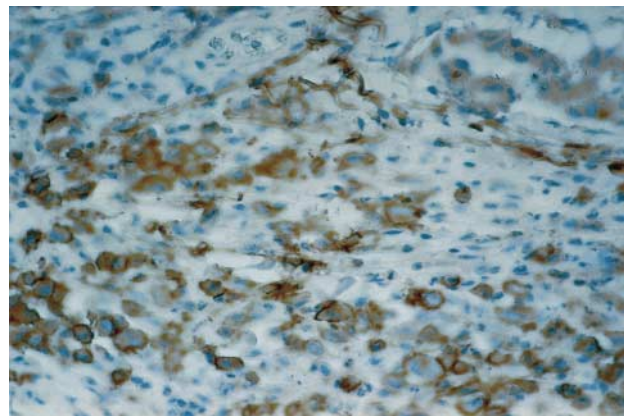


Fig. 2. Immunohistochemical verification of CD1a.