

# Excision of Lipodermatosclerotic Tissue: An Effective Treatment for Non-healing Venous Ulcers

INGELA AHNILIDE<sup>1</sup>, MATS BJELLERUP<sup>2</sup> and HENRIK ÅKESSON<sup>3</sup>

Departments of Dermatology, <sup>1</sup>University Hospital, Malmö, <sup>2</sup>Helsingborg Hospital, Helsingborg and <sup>3</sup>Department of Vascular Surgery, University Hospital, Malmö, Sweden

**In longstanding venous ulcers, the development of lipodermatosclerosis of the skin surrounding the ulcer is common. According to our clinical experience lipodermatosclerosis impairs the opportunities for the ulcer to heal. In this combined retrospective and prospective study the lipodermatosclerotic skin area was excised in 7 non-healing venous ulcers and then covered with split skin graft. All 7 legs had previously been treated with superficial venous surgery. Laser Doppler scanning of the ulcer area was performed pre- and postoperatively. Five of the 7 ulcers healed within 4 months and 1 healed within 9 months. Laser Doppler scanning showed increased blood flow in the lipodermatosclerotic skin area, which was decreased after the operation. This study indicates that excision of the lipodermatosclerotic skin area followed by split skin grafting can accomplish healing in non-healing venous leg ulcers that have failed to respond to previous superficial venous surgery. Key words: leg ulcer; venous insufficiency; split skin grafting; laser Doppler scanning.**

(Accepted August 10, 1999.)

Acta Derm Venereol 2000; 80: 28–30.

Ingela Ahnlide, Department of Dermatology, University Hospital, SE-205 02, Malmö, Sweden.

Lipodermatosclerosis, found exclusively in connection with venous insufficiency, is characterized by induration of the skin, often associated with hyperpigmentation (1). The cause of this phenomenon is incompletely understood. Disturbances in microcirculation have been found in the lipodermatosclerotic skin area. Incompetence of the venous valves gives rise to venous hypertension in the leg, which is transmitted to the capillaries, causing raised intracapillary pressure. Fagrell (2) used vital capillaroscopy to show that the number of capillaries is reduced, with the remaining capillaries becoming dilated and tortuous. Studies using the laser Doppler probe have shown an increased basal blood flow in the lipodermatosclerotic skin in the supine position, compared with normal skin (3–5). In addition other authors have shown a reduced capability to dilate the vessels following local ischaemia (6) and in response to local heating (7).

Nelzén et al. (8) and Myers et al. (9) have shown that up to 40% of venous ulcers are caused by superficial venous incompetence alone, with or without incompetence of the perforators and without any deep incompetence. Many of these patients can be treated successfully with venous surgery. Darke & Penfold (10) performed saphenous ligation on patients with venous ulcer and saphenous vein incompetence in combination with perforator incompetence, and a 90% healing rate was achieved. In some instances deep vein reconstructions are possible. Patients who are not suitable for

surgical treatment are obliged to undergo lifelong compression therapy. Most venous ulcers heal with local and compression therapy. Some ulcers, however, do not heal in spite of intensive therapy, including superficial venous surgery. In such patients skin grafting is often used as a complement. From our own experience with pinch grafting, venous ulcers have a lower healing rate than leg ulcers of other aetiologies (11). The aim of this study was to elucidate whether excision of the lipodermatosclerotic skin area, and thereby the area with disturbed microcirculation, supplemented with split skin grafting can achieve healing in therapy resistant or chronically recurring venous ulcers in patients with isolated deep venous insufficiency.

## MATERIAL AND METHODS

### Patients

Seven legs from 5 patients with venous ulcers and lipodermatosclerosis (4 females, 1 male) attending the Leg Ulcer Clinic at the Department of Dermatology in Malmö were included in the study. All ulcers were therapy resistant or chronically recurring. The patients had a mean age of 72 (range 52–84) years. In different cases the longest ulcer diameter ranged from 6 to 120 mm. Five of the ulcers were painful. In 6 patients pinch grafting had previously been tried without permanent healing. On all patients superficial venous surgery had previously been performed and all had an isolated deep venous insufficiency (Table I), confirmed with duplex ultrasonography (Acuson 128XP/10, Acuson, Mountain View, CA, USA) when included in the study. All patients had been treated with compression therapy for at least 6 months after superficial vein surgery without healing. All patients had an ankle-brachial index of >1 or a palpable pulse in the dorsal pedal artery. The patients had been under treatment for more than 2 years preoperatively and the presence of ulcers could be registered retrospectively from the patient records.

Table 1. Venous incompetence according to duplex ultrasonography

Patient	Common femoral vein	Superficial femoral vein	Popliteal vein	Lower leg veins
1*	+			
2	+	+		
3	+	+	+	
4	+	+	+	+
5	+	+	+	
6		+	+	
7	+	+	+	

+ = venous incompetence.

No perforator incompetence was found in any of the patients.

\*This patient had incompetence of the popliteal vein according to videoflebography.

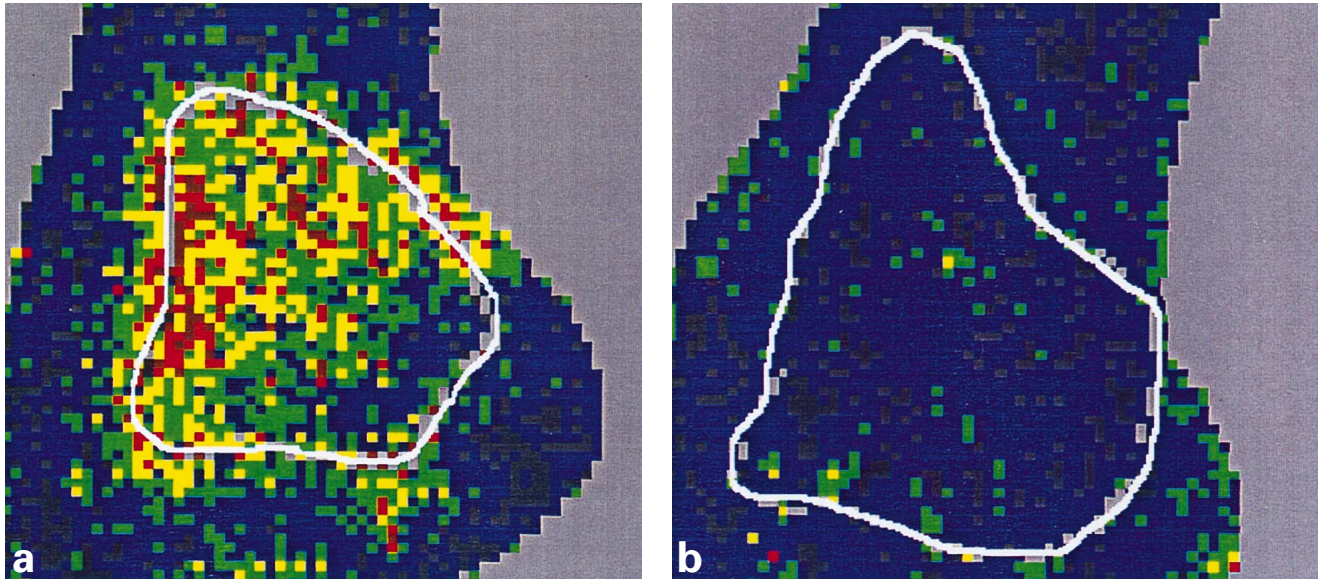


Fig. 1. (a) Preoperative laser Doppler scanning picture. The palpable lipodermatosclerotic area is outlined by grey markings. (b) Postoperative laser Doppler scanning picture. The blood flow in the transplanted area is normalized.

*Laser Doppler scanning*

Laser Doppler scanning of the lipodermatosclerotic skin area was made preoperatively in 6 cases and postoperatively at least 1 year after the operation in all 7 cases. All investigations were made in the supine position and at room temperature. The laser Doppler scanner used in this study (Lisca Development AB, Linköping, Sweden) allows measurements of the skin blood flow over an area 12 × 12 cm with 4096 measurement points (pixels), and the data is collected without touching the tissue (12). The data is presented as a colour-coded image in 6 colours from dark blue to red with increasing flow. Using this technique it is possible to investigate the regional distribution of the skin blood flow in the set area. Before the examination, metal markings were placed at the margins of the lipodermatosclerotic skin area. The margins of the lipodermatosclerotic area could thus be traced in the laser Doppler-scanning picture. The margins of the grafted area were marked postoperatively (Fig. 1). The mean blood flow was assessed preoperatively in the lipodermatosclerotic skin area and postoperatively in the grafted area.

*Surgery*

In all patients the lipodermatosclerotic skin area was excised down to the muscle fascia. The longest diameters of the excised skin area varied between 80 and 150 mm. A split skin graft was obtained from the proximal thigh. The skin graft was meshed with expansion rate 1.5. The recipient area was pre-treated with fibrin glue (Tisseel® Duo Quick Immuno Sweden AB, Solna, Sweden) to achieve graft adherence and the margins were fixated with staples. The skin graft was covered with a silicone net dressing (Mepitel® Mölnlycke AB, Mölnlycke, Sweden). This was protected with loosely applied cotton swabs fixated with a low elastic bandage. Histological examination was made of the excised material in all patients. Postoperatively the patients were restricted to bed rest for 7–10 days. Thrombosis prophylaxis was given routinely. All the patients left hospital with compression bandage.

*Follow-up*

Postoperatively the patients were followed every month until healed and then every sixth month for 2 years postoperatively.

RESULTS

Five of the 7 ulcers healed within 4 months after the operation and remained healed during the follow-up. One ulcer healed after 9 months and stayed healed during follow-up (Fig. 2). The flow in the lipodermatosclerotic area was high before operation (2.66–4.08 V) and markedly reduced postoperatively (0.60–2.64 V) (Fig. 3). An example of the regionally raised blood flow in the lipodermatosclerotic area is easily seen in Figure 1A. Postoperatively the flow is normalized (Fig. 1B). All the histological specimens showed an increased amount of transected capillary loops in the papillary dermis and fibrosis of the reticular dermis and subcutis.

DISCUSSION

In longstanding venous ulcers with pronounced lipodermatosclerosis it is often impossible to achieve healing in spite of intensive local treatment, even including skin transplantation of the ulcer. This view is supported by our own findings of lower healing rates after pinch grafting in venous leg ulcers compared with leg ulcers of other aetiologies (11). A possible explanation for this is the disturbed microcirculation in the lipodermatosclerotic area (2). Thus it is logical to assume that surgical removal of the lipodermatosclerotic area would be

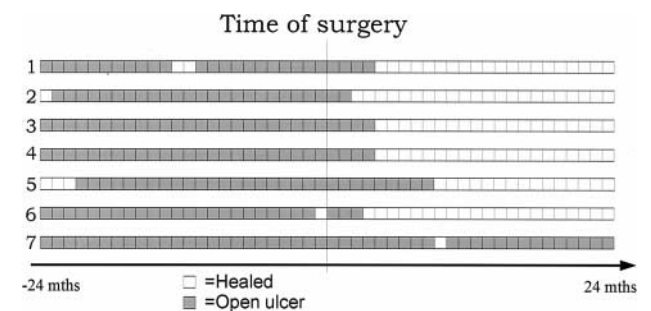


Fig. 2. Presence or absence of ulcer 2 years preoperatively and 2 years postoperatively.

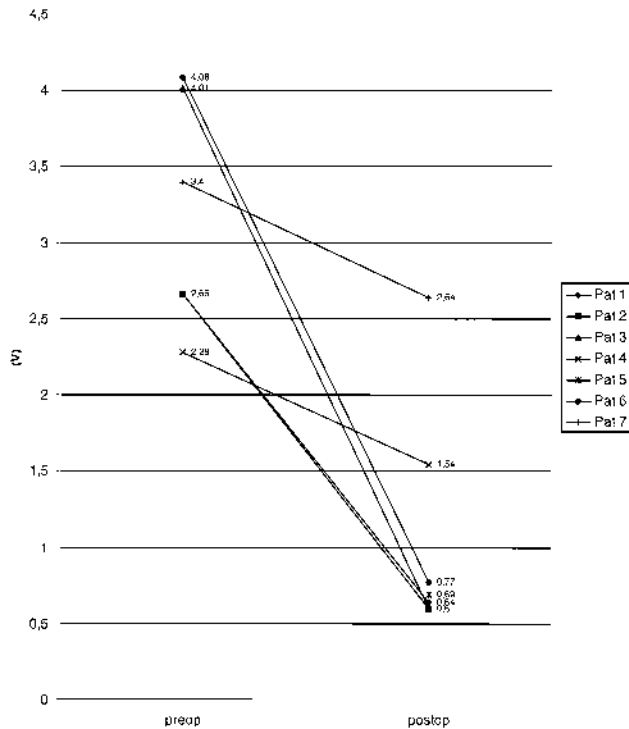


Fig. 3. The mean laser Doppler image values, expressed in volts (V), preoperatively in the lipodermatosclerotic skin area and postoperatively in the transplanted area. In patient 5 laser Doppler scanning was only carried out postoperatively.

beneficial for ulcer healing. Our study showed favourable results with excision of the lipodermatosclerosis in 6 out of 7 therapy resistant venous ulcers that had previously shown no response to adequate venous surgery. The effectiveness of removing lipodermatosclerotic tissue has previously been reported using so-called shave therapy (13). The present study, using a laser Doppler scanner, making it possible to measure the regional distribution of the blood flow, showed a raised basal skin blood flow in the lipodermatosclerotic skin areas. This is in concordance with previous point measurements using the laser Doppler probe (3, 5–7). The postoperative laser Doppler scan shows flow reduction and even normalization in the transplanted area, which may be the explanation for the better skin graft survival. Excision of the sclerotic skin area thus removes the unfavourable ulcer bed,

enhances the chances for graft ingrowth and probably reduces the risk for ulcer recurrences. Despite the low number of patients included in the study, our results indicate that removal of the sclerotic tissue, and thereby the area with pathological microcirculation, is an alternative in the treatment of non-healing venous ulcers. Further studies are in progress. It should be noted that lipodermatosclerosis surgery should be tried only after all other therapeutic measures, including adequate venous surgery, have failed.

## REFERENCES

1. Kirsner RS, Pardes JB, Eaglstein WH, Falanga V. The clinical spectrum of lipodermatosclerosis. *J Am Acad Dermatol* 1993; 28: 623–627.
2. Fagrell B. Local microcirculation in chronic venous incompetence and leg ulcers. *Vascular Surgery* 1979; 13: 217–225.
3. Sindrup JH, Avnstrup C, Steenfos HH, Kristensen JK. Transcutaneous PO<sub>2</sub> and laser Doppler blood flow measurements in 40 patients with venous leg ulcers. *Acta Derm Venereol* 1987; 67: 160–163.
4. Shami SK, Chittenden SJ, Scurr JH, Coleridge Smith PD. Skin blood flow in chronic venous insufficiency. *Phlebology* 1993; 8: 72–76.
5. Mayrovitz HN, Larsen PB. Peri wound skin microcirculation of venous leg ulcers. *Microvasc* 1994; 48: 114–123.
6. Stibe E, Cheate TR, Coleridge Smith PD, Scurr JH. Liposclerotic skin: a diffusion block or a perfusion problem? *Phlebology* 1990; 5: 231–236.
7. Cheate TR, Stibe E, Shami SK, Scurr JH, Coleridge Smith PD. Vasodilatory capacity of the skin in venous disease and its relationship to transcutaneous oxygen tension. *Br J Surg* 1991; 78: 607–610.
8. Nelzén O, Bergqvist D, Lindhagen A. Leg ulcer aetiology - a cross-sectional population study. *J Vasc Surg* 1991; 14: 557–564.
9. Myers KA, Ziegenbein RW, Zeng GH, Matthews PG. Duplex ultrasonography scanning for chronic venous disease: patterns of reflux. *J Vasc Surg* 1995; 21: 605–612.
10. Darke SG, Penfold C. Venous ulceration and saphenous ligation. *Eur J Vasc Surg* 1992; 6: 4–9.
11. Ahnlide I, Bjellerup M. Efficacy of pinch grafting in leg ulcers of different aetiologies. *Acta Derm Venereol* 1997; 77: 144–145.
12. Wårdell K, Jakobsson A, Nilsson GE. Imaging of tissue perfusion by dynamic light scattering. *IEEE Trans Biomed Eng* 1991; 40: 309–316.
13. Schmeller W, Gaber Y, Gehl H-B. Shave therapy is a simple, effective treatment of persistent venous leg ulcers. *J Am Acad Dermatol* 1998; 39: 232–238.