

Topical Photodynamic Therapy for Localized Scleroderma

SIGRID KARRER, CHRISTOPH ABELS, MICHAEL LANDTHALER and ROLF-MARKUS SZEIMIES

Department of Dermatology, University of Regensburg, Regensburg, Germany

Therapy of localized scleroderma is unsatisfactory, with numerous treatments being used that have only limited success or considerable side-effects. The aim of this trial was to determine whether topical photodynamic therapy would be effective in patients with localized scleroderma. Five patients with progressive disease, in whom conventional therapies had failed, were treated by application of a gel containing 3% 5-aminolevulinic acid followed by irradiation with an incoherent lamp (40 mW/cm², 10 J/cm²). The treatment was performed once or twice weekly for 3–6 months. In all patients the therapy was highly effective for sclerotic plaques, as measured by a quantitative durometer score and a clinical skin score. The only side-effect was a transient hyperpigmentation of the treated lesions. These cases document the beneficial effect of topical photodynamic therapy in localized scleroderma. Controlled trials are now necessary to confirm these preliminary results. Key words: morphea; PDT; 5-aminolevulinic acid; durometer.

(Accepted September 6, 1999.)

Acta Derm Venereol 2000; 80: 26–27.

Rolf-Markus Szeimies, Department of Dermatology, University of Regensburg, D-93042, Regensburg, Germany. E-mail: Rolf-Markus.Szeimies@klinik.uni-regensburg.de

Localized scleroderma is characterized by collagen accumulation and excessive sclerosis of the skin. The major complaints are tightness and itching and the disease is often complicated by contractures and cosmetic disfigurement. Numerous treatments have been tried, such as local corticosteroids, D-penicillamine, intravenous penicillin, intralesional interferon gamma, plasmapheresis, oral PUVA therapy or PUVA-bath photochemotherapy, UVA₁ phototherapy and, in patients with severe disease, immunosuppressive and vasoactive drugs (1–5). However, treatments have had only limited success or have caused considerable side-effects.

Topical photodynamic therapy (PDT) using 5-aminolevulinic acid (ALA) is an experimental therapeutic approach, which is based on photosensitization of abnormal tissue by ALA-induced porphyrins and subsequent irradiation with red light, thus inducing cell injury via generation of singlet oxygen and other free radicals (6). Topical ALA-PDT has been used successfully for the treatment of superficial precancerous and cancerous skin lesions (6, 7), but also for chronic inflammatory diseases of the skin, i.e. psoriasis vulgaris or vulvar lichen sclerosus (8, 9) have been shown to respond to this therapy.

In order to assess whether ALA-PDT could be useful in localized scleroderma, a clinical trial was conducted in 5 patients with progressive disease who had failed to respond to other therapies.

MATERIAL AND METHODS

Patients

Five patients aged between 21 and 63 years with biopsy-proven localized scleroderma (morphea) were studied. All patients had evidence of progressive disease, i.e. lesions showed an inflammatory reaction and increase in size. In each patient the condition had previously failed to respond to potent topical corticosteroids, systemic therapy with penicillin and/or PUVA bath photochemotherapy. Patients were required to discontinue all therapy at least 4 weeks before study initiation. The most affected sclerotic plaque of each patient was judged at baseline and then every 2 weeks during treatment. Sclerotic plaques were assessed by a clinical skin score (10) and the durometer score (11). The clinical skin score assesses the degree of thickening and induration by palpation of the skin on an analogue scale graded from 10 (severe sclerosis, no folding, wooden hard) to 0 (normal skin folding) (10). In larger plaques, the most affected part of the plaque determined the score. The hardness of the lesion was examined by means of a hand-held durometer with a calibrated gauge that registers linearly divided units on a scale from 0 to 100 (10). Final hardness is defined as that recorded within 15 s of firm contact of the durometer (a small dull inferior indenter is retractable and is responsible for the measurements registered on the gauge) with the skin (12). In each patient (except for patient 1 who had only 2 plaques which were both treated) 1 plaque was not treated and used as a control lesion which was scored at baseline and after therapy. The patient data are summarized in Table I.

Photodynamic therapy (PDT)

Several plaques were treated in each patient, the most affected site was chosen for evaluation of therapy effect (durometer and clinical skin score). A gel containing 3% ALA was applied to each lesion and kept under occlusion and impervious to light for 6 h. Irradiation of the lesions was then performed using an incoherent light source (PDT 1200, Waldmann, Germany, light dose 40 mW/cm², power density 10 J/cm²). The patients were treated once or twice weekly for 3–6 months, the duration of therapy depending on the clinical response.

RESULTS

ALA-PDT was well tolerated, there was only a slight stinging by the end of irradiation. In all patients sclerosis regressed greatly, skin score markedly decreased and durometer measurements objectively showed a reduction of skin hardness (Fig. 1). Untreated control lesions did not show any improvement when looking at the skin and durometer scores at baseline and at the end of therapy. All patients evaluated therapy subjectively as effective and well tolerable, discomfort and itching associated with the lesions significantly decreased during therapy. In 2 patients with sclerotic plaques on the lower legs, impaired joint mobility was markedly improved. In 1 patient hair regrowth was achieved in a plaque located on the lower leg. The only side-effect was a transient hyperpigmentation in the treated area which resolved within some weeks after cessation of ALA-PDT in all patients. We did not observe recurrence or worsening of the disease within a follow-up of up to 2 years after treatment.

Table I. Characteristics of patients with localized scleroderma treated with photodynamic therapy using 5-aminolevulinic acid

Age/sex	Duration of disease	No. lesions	Duration (months)	Treatments (no.)
21/M	9 months	2	6	35
63/M	5 years	8	6	43
53/F	3 years	4	3	26
41/M	1 year	6	3	25
68/M	1 year	3	3	25

M: male; F: female.

DISCUSSION

This preliminary clinical trial documents for the first time the beneficial effect of ALA-PDT in patients with localized scleroderma in whom other therapies, such as PUVA bath photochemotherapy and intravenous penicillin, had failed.

Photochemotherapy using photosensitizing psoralen derivatives and UVA (PUVA) is one of the most effective and widely applied therapies for localized scleroderma (2, 4, 13). However, PUVA is associated with an increased risk of squamous cell carcinoma and other skin tumours (14). Recently, also UVA₁ phototherapy has been shown to markedly improve or clear localized scleroderma (3). In contrast to PUVA or UVA₁ phototherapy (14, 15), carcinogenic effects are not discussed for PDT.

So far, the pathogenesis of localized scleroderma is not well understood. It has been shown that type I collagen synthesis is elevated in scleroderma fibroblasts, whereas collagenase activity and production is remarkably reduced (1, 16). This may result in excessive accumulation of collagen in patients with localized scleroderma or systemic sclerosis. Photosensitization of human dermal fibroblasts with uroporphyrin followed by long-wave ultraviolet irradiation resulted in an increase in collagenases (matrix metalloproteinases: MMP 1 and MMP 3) with singlet oxygen being the major intermediate in the upregulation of MMPs (17).

Topical PDT with ALA, which induces the synthesis of porphyrins, has demonstrated a very good efficacy and

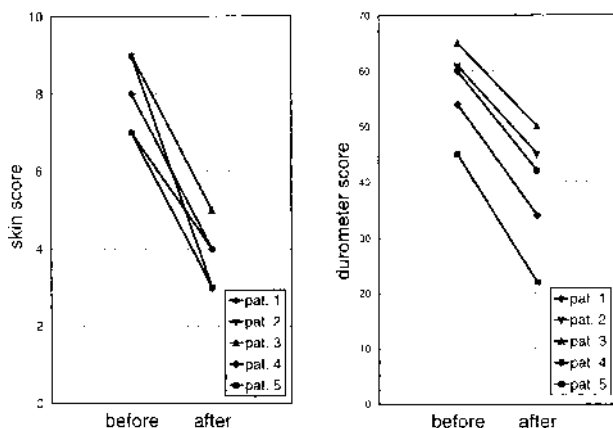


Fig. 1. Improvement of both clinical skin score and durometer score in patients with localized scleroderma after photodynamic therapy with topically applied 5-aminolevulinic acid (duration of treatment between 3 and 6 months).

tolerability in our series of patients with localized scleroderma. To rule out the possibility that clinical improvement is based on spontaneous remission, in 4 of the treated patients 1 untreated control plaque was observed which did not show any improvement at the end of PDT. The mechanisms of action of ALA-PDT in scleroderma, e.g. induction of collagenase, remain to be investigated. Additionally, prospective, double-blind placebo-controlled trials with larger numbers of patients are essential in order to confirm the value of ALA-PDT for the treatment of localized scleroderma.

REFERENCES

- Hunzelmann N, Scharffetter-Kochanek K, Hager C, Krieg T. Management of localised scleroderma. *Sem Cutan Med Surg* 1998; 17: 34–40.
- Kerscher M, Meurer M, Sander C, Volkenandt M, Lehmann P, Plewig G, Röcken M. PUVA bath photochemotherapy for localized scleroderma. *Arch Dermatol* 1996; 132: 1280–1282.
- Stegé H, Berneburg M, Humke S, Klammer M, Grewe M, Grether-Beck S, et al. High-dose UVA₁ radiation therapy for localised scleroderma. *J Am Acad Dermatol* 1997; 36: 938–944.
- Morison WL. Psoralen UVA therapy for linear and generalized morphea. *J Am Acad Dermatol* 1997; 37: 657–659.
- Wach F, Ullrich H, Schmitz G, Landthaler M, Hein R. Treatment of severe localized scleroderma by plasmapheresis – report of three cases. *Br J Dermatol* 1995; 133: 605–609.
- Peng Q, Warloe T, Berg K, Moan J, Kongshaug M, Giercksky KE, Nesland JM. 5-Aminolevulinic acid-based photodynamic therapy. Clinical research and future challenges. *Cancer* 1997; 79: 2282–2308.
- Szeimies RM, Calzavara-Pinton P, Karrer S, Ortel B, Landthaler M. Topical photodynamic therapy in dermatology. *J Photochem Photobiol* 1996; 36: 213–219.
- Boehncke WH, Sterry W, Kaufmann R. Treatment of psoriasis by topical photodynamic therapy with polychromatic light. *Lancet* 1994; 343: 801.
- Hillemanns P, Untch M, Prove F, Baumgartner R, Hillemanns M, Korell M. Photodynamic therapy of vulvar lichen sclerosis with 5-aminolevulinic acid. *Obstet Gynecol* 1999; 93: 71–74.
- Rook AH, Freundlich B, Jegasothy BV, Perez MI, Barr WG, Jimenez SA, et al. Treatment of systemic sclerosis with extracorporeal photochemotherapy. *Arch Dermatol* 1992; 128: 337–346.
- Seyger MMB, van den Hoogen FHJ, De Boo T, De Jong EMGJ. Reliability of two methods to assess morphea: skin scoring and the use of a durometer. *J Am Acad Dermatol* 1997; 37: 793–796.
- Falanga V, Bucalo B. Use of a durometer to assess skin hardness. *J Am Acad Dermatol* 1993; 29: 47–51.
- Kanekura T, Fukumaru S, Matsushita S, Terasaki K, Mizoguchi S, Kanzaki T. Successful treatment of scleroderma with PUVA therapy. *J Dermatol* 1996; 23: 155–159.
- Stern RS, Lunder EJ. Risk of squamous cell carcinoma and methoxsalen (psoralen) and UV-A radiation (PUVA). A meta-analysis. *Arch Dermatol* 1998; 134: 1582–1585.
- Rünger TM. Genotoxizität, Mutagenität und Karzinogenität von UVA und UVB. *Z Hautkr* 1995; 70: 877–881.
- Takeda K, Hatamochi A, Ueki H, Nakata M, Oishi Y. Decreased collagenase expression in cultured systemic sclerosis fibroblasts. *J Invest Dermatol* 1994; 103: 359–363.
- Herrmann G, Wlaschek M, Bolsen K, Prenzel K, Goerz G, Scharffetter-Kochanek K. Photosensitization of uroporphyrin augments the ultraviolet A-induced synthesis of matrix metalloproteinases in human dermal fibroblasts. *J Invest Dermatol* 1996; 107: 398–403.