

Blood Perfusion Studies on Basal Cell Carcinomas in Conjunction with Photodynamic Therapy and Cryotherapy Employing Laser-Doppler Perfusion Imaging

ANNIKA M. K. ENEJDER^{1,2}, CLAES af KLINTEBERG^{1,2}, INGRID WANG^{1,3}, STEFAN ANDERSSON-ENGELS^{1,2}, NIELS BENDSOE^{1,4}, SUNE SVANBERG^{1,2} and KATARINA SVANBERG^{1,3}

¹Lund University Medical Laser Centre, ²Department of Physics, Lund Institute of Technology, Departments of ³Oncology and ⁴Dermatology and Venereology, Lund University Hospital, Lund, Sweden

Superficial blood perfusion was monitored using laser-Doppler perfusion imaging in connection with a phase III clinical trial comparing photodynamic therapy, utilizing topically applied δ -aminolevulinic acid, with cryotherapy of basal cell carcinomas. A total of 526 images were recorded before and immediately after the treatment and during the follow-up period. Before treatment, the lesions exhibited a blood perfusion 3 ± 2 times that in normal tissue. Both treatment modalities induced an increased blood perfusion inside the lesions, which slowly approached normal values in conjunction with successful treatments. The blood perfusion in successfully treated lesions approached normal values 2 months after photodynamic therapy, and about 1 year after cryotherapy. The tissue perfusion in recurrent lesions did not decrease to normal values after the treatment, suggesting that the laser-Doppler perfusion imaging technique can be used to follow the healing process and discover possible persistent tumour growth. Key words: perfusion, regional; laser-Doppler flowmetry; aminolevulinic acid; photochemotherapy; carcinoma, basal cell.

(Accepted August 27 1999.)

Acta Derm Venereol 2000; 80: 19–23.

Katarina Svanberg, Department of Oncology, Lund University Hospital, SE-221 85, Lund, Sweden.

A local, abnormal increase in blood perfusion in the skin often indicates an elevated activity caused by, for example, an inflammatory response. Studying microvascular blood perfusion *in vivo* can thus provide information on the local tissue activity. This can be of interest for basic studies of normal skin (1) as well as in connection with various treatment procedures where healing processes (2, 3) and immediate treatment responses (3) are investigated. In a study of basal cell carcinomas (BCCs) treated with photodynamic therapy (PDT) using topically applied δ -aminolevulinic acid (ALA), Wang et al. reported increased superficial blood flow as an immediate response to the treatment (3). In this case a hypoxic treatment effect due to immediate vascular damages is less probable.

When studying tissue perfusion in skin tumours in conjunction with a treatment modality, it is important to separate the influence of the treatment effect from other affecting parameters. Superficial blood flow in the skin is also influenced by, for example, external stimuli, such as surrounding temperature, applied pressure, mechanical contact, etc. In order to avoid the influence of the latter parameters, it is essential that the peripheral blood flow in the

skin is monitored non-invasively without a measuring device touching the tissue. Laser-Doppler perfusion imaging (LDPI) with a probing laser beam sequentially scanned over the tissue fulfils this requirement. This technique is based on extracting the spectral distribution of weak Doppler shifted components in the diffusely backscattered light, originating from light scattering by the blood cells in motion (4).

The purpose of this study was to evaluate whether LDPI can be used clinically to monitor the healing process post-treatment of BCCs by following the tissue perfusion in successfully treated lesions and by comparing it with that recorded in lesions showing residual or recurrent tumour growth. This approach also enabled us to compare the time constant of the healing process following a conventional treatment modality – cryotherapy (5, 6) – with that generated by a new and less invasive treatment modality – ALA-PDT (7, 8).

MATERIAL AND METHODS

Patients

LDPI measurements from 35 superficial and 48 nodular BCCs in 83 patients were included in this study. The average age of the patients was 68 years (range 42–88 years). The lesions, with a diameter of 0.4–3.5 cm, had a distribution corresponding to 53% (44/83) on the trunk, 30% (25/83) in the head/neck region and 17% (14/83) on the extremities. The patients were randomized to be treated with either cryotherapy or PDT, forming 4 groups with 15 superficial (Cryo-S) and 24 nodular (Cryo-N) lesions treated with cryotherapy, and 20 superficial (PDT-S) and 24 nodular (PDT-N) lesions treated with ALA-PDT.

Treatment modalities

One of the 2 treatment modalities included in this study was conventional cryotherapy with 2 freeze-thaw cycles. Liquid nitrogen was sprayed upon the lesion for 25–30 s each time separated by a thawing time of 2–4 min, depending on the size of the lesion. The other treatment modality employed was PDT with protoporphyrin IX as a photosensitizer (7), originating from ALA in a cream base, administered topically 6 h prior to the treatment. Prior to the application of ALA, the lesions were prepared to facilitate the penetration of ALA into the tissue. Thus, the area was cleansed with 96% ethanol or isotonic saline, crust formations were removed, and the stratum corneum was stripped off when present. A light dose of 60 J/cm² was given at a wavelength of 635 nm. The fluence rate was kept below 100 mW/cm², in order to avoid hyperthermic effects. The full treatment protocol is described in detail elsewhere (8).

Laser-Doppler perfusion imaging

A commercially available LDPI system (Lisca Development AB, Linköping, Sweden), thoroughly described elsewhere (4), was used for the measurements. Briefly, the imaging system is composed of a laser diode (wavelength 633 nm) and 2 scanning mirrors yielding a probe beam with an estimated probe depth in the range 150–350 µm, well-suited for probing the blood flow in the cutaneous capillaries (9). The reflected light from the moving blood cells is collected by a photo diode situated next to the mirrors. The resulting Doppler shift distribution, yielding signals proportional to the amount of scattering particles and their velocities, is deduced and stored as a colour-coded image with 40×40 pixels selected for this study. A distance of 16±0.5 cm between the light source and the tissue resulted in a scanned area of approximately 6×6 cm² and a recording time of 1.5 min. The imaged area included the lesion and surrounding normal skin not affected by the treatment.

The images were analysed by taking an average of the resulting blood perfusion signal in the BCC area and the surrounding normal untreated skin, respectively. The values from the different areas were computed using a combination of mask and threshold features, available in a commercial evaluation program (LDISOFT 1.0, Lisca Development AB, Linköping, Sweden). All mean values were based on more than 20 pixel values, ensuring satisfactory statistics. A time delay of 10 min between the cryotherapy and the blood perfusion measurements allowed most frozen areas to regain more or less normal skin temperature. For a small number of lesions, the central parts did not return to normal temperature when the laser-Doppler perfusion image was recorded, resulting in a lower blood flow. The average blood perfusion in the BCC area was then based on the peripheral lesion region only, with normal tissue temperature and high blood perfusion. This evaluation approach was also applied when the central lesion was covered with a necrotic crust, preventing the laser light from probing the blood perfusion underneath, due to its low penetration depth. The average blood perfusion in the lesion was statistically compared with that monitored in the normal skin within each of the 4 lesion groups by employing a 2-tailed, paired Student's *t*-test. Furthermore, a tissue perfusion ratio was formed by dividing the average blood perfusion in the lesion with that in the normal untreated tissue. This was performed in order to compensate for patient-to-patient variations in skin pigmentation and for possible changes in the tissue perfusion not correlated with the treatment procedures.

Study design

At the treatment session, laser-Doppler perfusion images were collected prior to and immediately after treatment. The treatment result was evaluated by visual assessment at scheduled follow-up visits from 1 week to 2 years after the treatment. New LDPI measurements

were performed at these visits. The numbers of laser-Doppler perfusion images are presented in Table I. As all patients were not able to come to all follow-up visits, and it was not always possible to record the images when they did, the numbers from the different visits vary slightly. At the 3- and 13-month visits, biopsies were collected at the site that, by clinical inspection, seemed to be most suspicious for the presence of tumour cells. Punch biopsies with a diameter of 2, 3 or 4 mm were used, depending on the size of the lesion. For simplicity, we use the notation "recurrent tumour" if the histopathological examination revealed malignant cells due to either residual or recurrent tumour growth. A PDT retreatment was performed immediately on all recurrent lesions initially treated with PDT. Recurrent lesions initially treated with cryotherapy were retreated only when the residual tumour was both clinically and histopathologically obvious. If, on the other hand, the biopsy with tumour cells was histopathologically radical, the result of the 13-month follow-up visit was used to determine whether an additional treatment was needed. Instead, the result of the 1-year follow-up visit was used to determine whether an additional treatment was needed. This procedure was according to local clinical practice, as cryotherapy causes more unwanted damage to the normal tissue than PDT.

RESULTS

Fig. 1 shows examples of perfusion images recorded from 2 lesions treated with ALA-PDT and cryotherapy, respectively. The tissue perfusion is clearly higher in the BCC region before the treatment and at the first follow-up visits. The perfusion in the lesion approaches normal values approximately 1 month after PDT, while this occurs later than 3 months after cryotherapy. This process can also be seen in the diagrams in Fig. 2, presenting average absolute values of the perfusion for these 2 lesions as a function of time. Corresponding standard deviations within the evaluated regions are in the order of 20% of the average values shown.

The histopathological examination 3 months after treatment revealed malignant cells in 16 lesions (Table II). At the 13-month follow-up visit, the biopsies showed tumour growth in 11 of the patients without tumour growth in the first follow-up biopsy. Persistent tumour growth was also found in 4 of the patients with recurrent tumour growth in the biopsy taken at the 3-month follow-up visit.

Fig. 3 shows average values and standard errors of the tissue perfusion ratio for the 4 lesion groups, including only lesions that did not show any tumour growth at either of the 2 follow-up biopsies. Average perfusion ratios obtained for

Table I. Number of laser-Doppler perfusion images. Time is related to the first treatment session

	Pre-treatment	Immediately post-treatment	1 week post-treatment	1 month post-treatment	2 months post-treatment	3 months post-treatment	13 months post-treatment	24 months post-treatment	Total
Tumours successfully treated in 1 session									
PDT-superficial	12	12	9	11	10	10	12	6	82
PDT-nodular	13	13	9	10	11	11	13	5	85
Cryo-superficial	14	14	10	11	13	12	13	7	94
Cryo-nodular	16	17	13	13	11	17	16	7	110
Recurrent tumours									
PDT-superficial	7	8	4	7	7	6	6	2	47
PDT-nodular	11	11	9	8	6	8	8	–	61
Cryo-superficial	1	1	1	1	1	1	1	–	7
Cryo-nodular	7	7	4	5	2	7	6	2	40

PDT = photodynamic therapy.

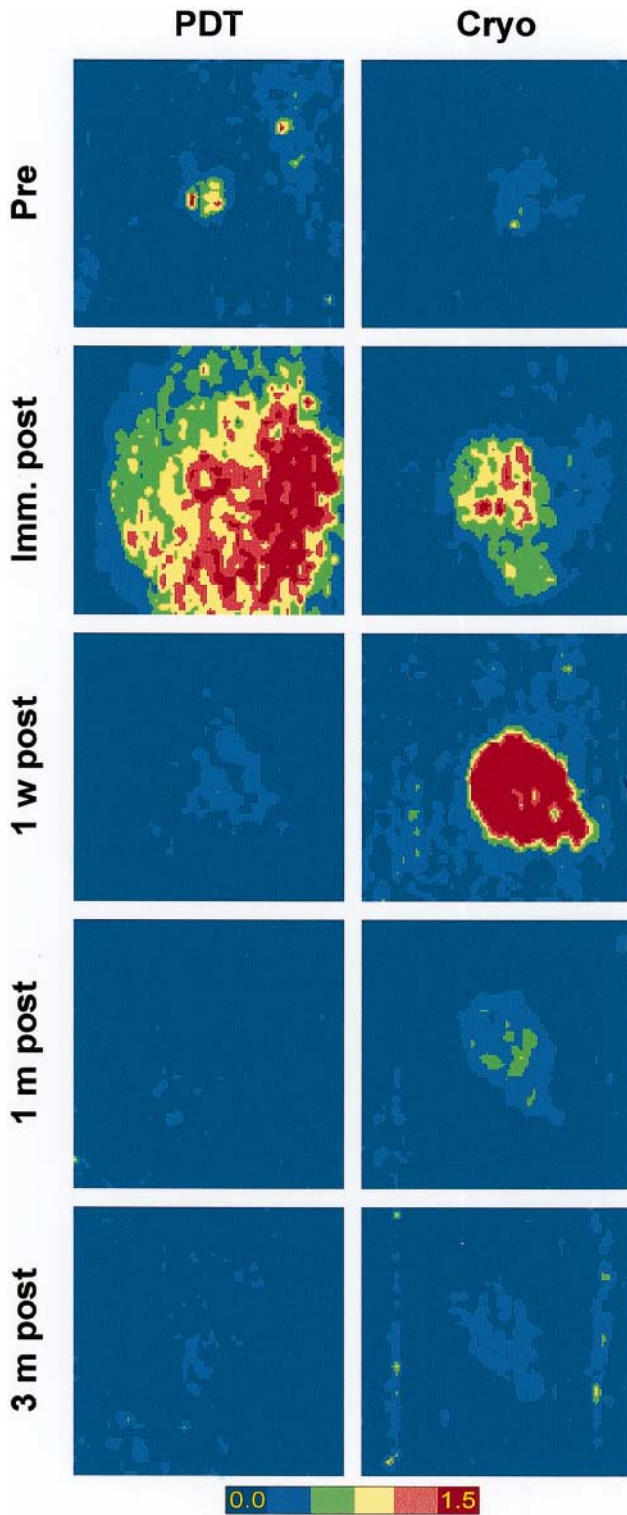


Fig. 1. LDPI images recorded from 2 superficial basal cell carcinomas (BCCs) treated with photodynamic therapy (PDT) and cryotherapy, respectively.

cryo-treated lesions 3 months post-treatment are similar to ratios obtained for PDT-treated lesions already after 1 month. This is true both for superficial and nodular BCCs. One can also notice that higher perfusion ratios are obtained after both treatments employed for the superficial lesions compared with the nodular.

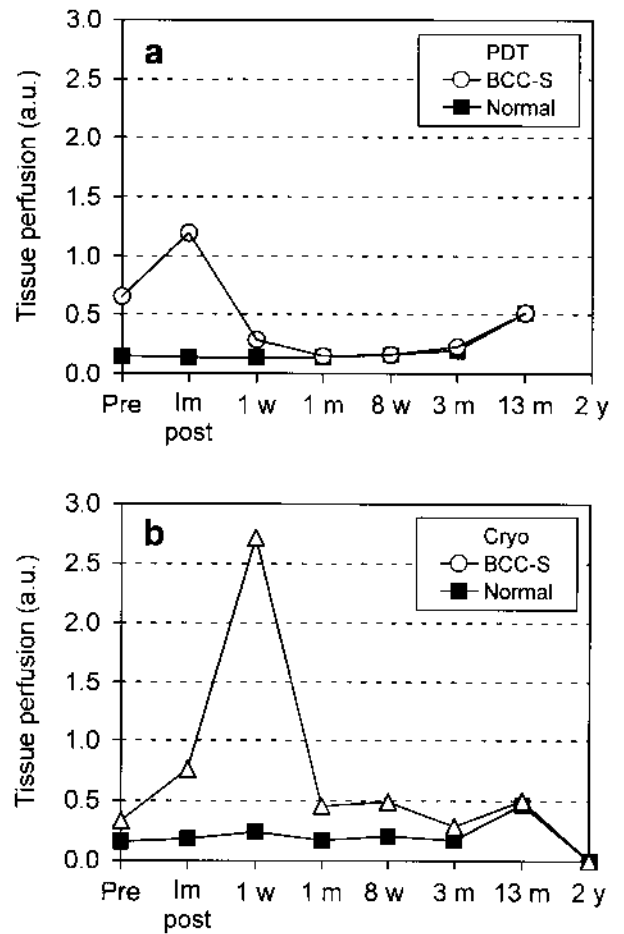


Fig. 2. Average values of the blood perfusion in the basal cell carcinomas (BCC) region and normal skin following (a) photodynamic therapy (PDT) and (b) cryotherapy. The graphs correspond to the data recorded from the same lesions as in Fig. 1, and are presented in the same scale.

A Student's *t*-test was used to compare the perfusion of the successfully treated lesions with that of the surrounding normal skin. With a significance level of 5%, the blood perfusion in the PDT-treated BCCs approaches normal values after 2 months. For cryo-treated lesions this occurs between 3 and 13 months post-treatment.

The perfusion ratios of lesions with recurrent tumour growth 3 months post-treatment are plotted in Fig. 4 together with the ratios obtained from the successfully treated lesions. For superficial lesions treated with ALA-PDT, elevated perfusion levels can be found in all lesions immediately and 1 week post-PDT. One month after the treatment, the perfusion ratios decrease towards unity. During the next 2 months, the perfusion in the recurrent lesions increases again towards the values obtained before the treatment. A retreatment of PDT recurrence patients was performed shortly after the 3-month visit when the result of the histopathological analysis was known. One and 2 years after the first treatment, the perfusion values within the lesions decreased to normal.

The recurrent nodular lesions treated with cryotherapy (Fig. 4) have higher perfusion ratios at all times. Only one recurrent lesion was monitored 2 months after the treatment. This point is left out in the graph.

Table II. Recurrent tumour growth as evaluated from punch biopsies collected 3 and 13 months post-treatment

	Number of lesions	3-month visit		13-month visit
		Recurrent lesions	Remaining at 13 months	New recurrences
PDT-superficial	20	4	2	4
PDT-nodular	24	8	0	3
Cryo-superficial	15	0	0	1
Cryo-nodular	24	4	2	3

PDT=photodynamic therapy.

DISCUSSION

LDPI is an elegant technique to monitor superficial blood perfusion in skin *in vivo* without inducing artefacts by touching the area during the recording. The imaging approach yields reliable clinical information based on good statistics, as spatial variations in the blood perfusion can be averaged over the sample area. A tissue perfusion ratio, formed by dividing the average blood perfusion in the lesion with that in the normal skin, permitted us to follow the superficial blood flow in the BCC regions during the healing time. The use of ratios eliminates patient-to-patient variations in skin pigmentation, surrounding room temperature, stress and activity level of the patient and other external factors of importance in conjunction with the LDPI recording. The importance of this approach is exemplified in the diagram in Fig. 2, showing the blood perfusion in arbitrary units in the lesion and in the normal skin. The superficial blood flow in the PDT-treated lesion is elevated 1 year post-treatment, but this increase originates from external causes as it was accompanied by an equal increase in the normal skin.

The increase in microvascular blood flow in malignant skin tumours during ALA-PDT, measured in this study and by Wang et al. (3), might be a dynamic parameter affecting the treatment result. Elevated blood perfusion is partly caused by an increased concentration of red blood cells, which contain the highly light absorbing haemoglobin. Due to the higher absorption, the light penetration depth decreases. As a result, the depth at which the lesions can be effectively treated is reduced. On the other hand, increased perfusion leads to an increase in the tissue oxygenation. Oxygen is vital for the PDT

process. Thus, it might be important to monitor the tissue perfusion in conjunction with PDT in order to optimize the treatment results.

The final decrease in the perfusion ratio to a value close to unity did not occur for lesions with recurrent tumours in this study. The perfusion ratios 3 months after treatment had rather returned to values similar to those prior to the treatments, as shown in Fig. 4. Following successful PDT retreatment, an accompanying decrease in tissue perfusion ratio was found at the follow-up visits 13 and 24 months post-first session. These observations demonstrate that the superficial blood perfusion in a BCC can be used as a fair measure of the activity in the lesion following treatment. Thus, LDPI can be employed to monitor the healing process in a BCC post-treatment. By repeated monitoring during the first 3 months post-PDT, it might also be possible to use this technique as an aid to find recurrent tumours at an early stage without the need for repeated biopsy sampling. Lesions treated with cryotherapy have a larger variation, and the

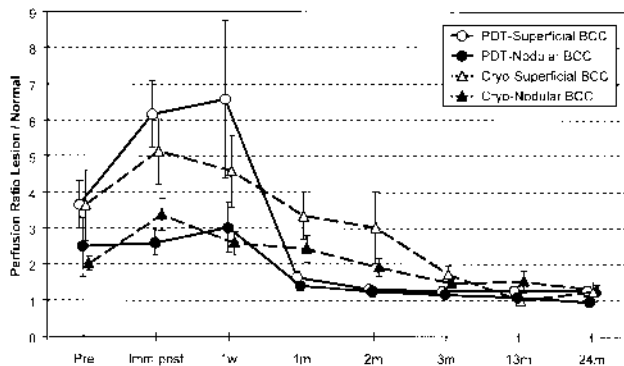


Fig. 3. Average tissue perfusion ratios versus healing time for the non-recurrent lesions. Error bars indicate ± 1 standard error. Note the swift decrease in the perfusion following photodynamic therapy (PDT) compared with after cryotherapy. BCC=basal cell carcinomas.

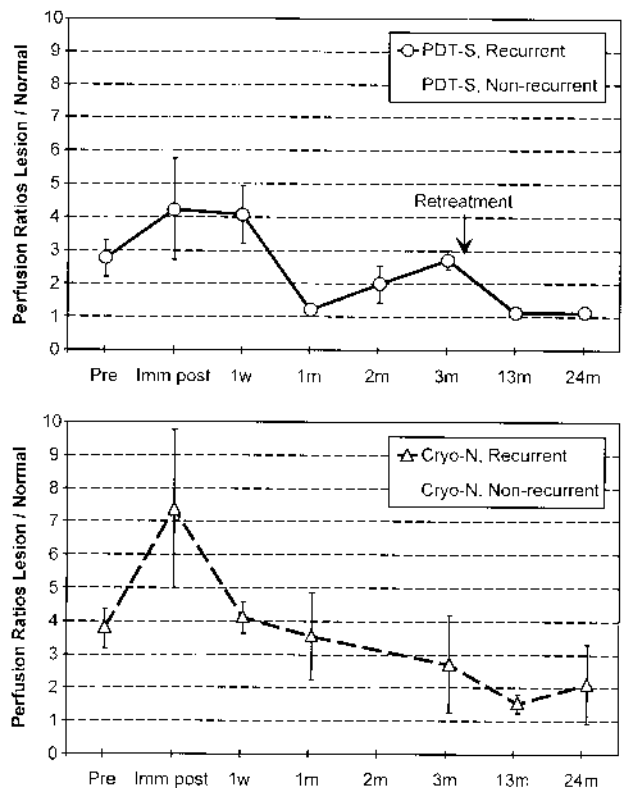


Fig. 4. Blood perfusion ratios of recurrent lesions. PDT-S=photodynamic therapy, superficial; Cryo-N=Cryo nodular.

perfusion is constantly decreasing during the first year. These results imply that it is not possible to use LDPI to find possible recurrent tumour growth in connection with cryotherapy.

The individual examples of recorded laser-Doppler perfusion images of superficial BCCs following cryotherapy and ALA-PDT shown in Fig. 1 indicate that a longer time is needed for the recovering to normal blood perfusion levels in the treated area following cryotherapy compared with ALA-PDT. We can still distinguish the lesion from the normal skin in the blood perfusion image recorded 3 months post-cryotherapy, while this is already difficult 1 month after PDT. The faster decrease in superficial blood flow in the PDT-treated lesions is also reflected by the average values of the perfusion ratios shown in Fig. 3. This observation is valid both for superficial and nodular BCCs. The only difference found was that nodular lesions exhibited lower perfusion ratios than superficial lesion. This is probably due to the epidermal cell layer, which usually covers nodular lesions and prevents much of the dynamically scattered light from the moving blood cells to reach the detector.

In clinical practice, LDPI can be used to aid the examining physician. Especially in the case of BCCs, not being a life threatening disease, a simple diagnostic tool, such as LDPI, would be of great value. For patients with multifocal tumour growth, the images can be used as an aid to evaluate suspicious lesions from the associated increased perfusion, and thus reduce the number of biopsies needed. Furthermore, it can be used to find recurrent or residual tumour growth after PDT. Normally, the perfusion of a treated lesion approaches that of the surrounding tissue. If the perfusion ratio increases, a retreatment can be performed, again reducing the number of biopsies. This is of interest, since an advantage of PDT is the good cosmetic result. Normally, the only sign after successful treatment is the mark of the punch biopsy.

ACKNOWLEDGEMENTS

The support of Dr Cornelia Gröhl, Dr Nicola Wunsch, (Johnson & Johnson Medical GmbH, Norderstedt, Germany) and Dr Jonas CT Wang (Johnson & Johnson Applied Research Topical Formulations, Skillman, NJ, USA) is gratefully acknowledged. The authors are also grateful for the support of Dr Barat Behjati. This work was financially supported by Johnson & Johnson Medical GmbH, Norderstedt, Germany; the Swedish Research Council for Engineering Sciences and the Swedish and the Norwegian Cancer Societies.

REFERENCES

1. Anderson C, Andersson T, Wårdell K. Changes in skin circulation after insertion of a microdialysis probe visualized by laser Doppler perfusion imaging. *J Invest Dermatol* 1994; 102: 807–811.
2. Troilius A, Ljunggren B, Bornemyr S, Nilsson B, Wårdell K. Evaluation of port wine stain perfusion by laser Doppler imaging and thermography before and after argon laser treatment. *Acta Derm Venereol* 1992; 72: 6–10.
3. Wang I, Andersson-Engels S, Nilsson GE, Wårdell K, Svanberg K. Superficial blood flow following photodynamic therapy of malignant skin tumours measured by laser Doppler perfusion imaging. *Br J Dermatol* 1997; 136: 184–189.
4. Wårdell K, Jakobsson A, Nilsson GE. Laser Doppler perfusion imaging by dynamic light scattering. *IEEE Trans Biomed Eng* 1993; 40: 309–316.
5. Holt PJA. Cryotherapy for skin cancer: results over a 5-year period using liquid nitrogen spray cryosurgery. *Br J Dermatol* 1988; 119: 231–240.
6. Rowe DE, Carroll RJ, Day CL. Long-term recurrence rates in previously untreated (primary) basal cell carcinoma: implications for patients follow-up. *J Dermatol Surg Oncol* 1989; 15: 315–328.
7. Kennedy JC, Pottier RH, Pross DC. Photodynamic therapy with endogenous protoporphyrin IX: Basic principles and present clinical experience. *J Photochem Photobiol B* 1990; 6: 143–148.
8. Svanberg K, Andersson T, Killander D, Wang I, Stenram U, Andersson-Engels S, Berg R, Johansson J, Svanberg S. Photodynamic therapy of non-melanoma malignant tumours of the skin using topical δ -amino levulinic acid sensitization and laser irradiation. *Br J Dermatol* 1994; 130: 743–751.
9. Jakobsson A, Nilsson GE. Prediction of sampling depth and photon pathlength in laser Doppler flowmetry. *Med Biol Eng Comput* 1993; 31: 301–307.