

CLINICAL REPORT

Histological Diagnosis of Cutaneous “Warty” Carcinoma on a Pre-existing HPV Lesion

KIRIAKI ARONI, ANDREAS CH. LAZARIS, ANNA IOAKIM-LIOSSI, HELEN PARASKEVAKOU and PANAYIOTIS S. DAVARIS

Department of Pathology, The Athens National University Medical School, Athens, Greece.

A middle-aged man with an 8-year history of a fungating tumour mass on his thigh was histologically diagnosed as having an invasive “warty” carcinoma at the location of a pre-existing human papillomavirus (HPV) lesion. The tumour surface had a verruciform appearance with papillae containing fibrovascular cores. Many of the malignant cells displayed changes consistent with koilocytotic atypia. We noticed a greater degree of nuclear atypia in comparison with a verrucous carcinoma. Focally, some neoplastic cells demonstrated features of basaloid differentiation. Under *in situ* hybridization conditions, only HPV16 DNA, which is commonly associated with genital neoplasia, was detected selectively in rather superficial areas, corresponding to morphological evidence of HPV infection (i.e. koilocytotic atypia). It is worth noting that cutaneous location of such a warty carcinoma is very rare. Key words: warty carcinoma; condylomatous carcinoma; skin; human papillomavirus; *in situ* hybridization.

(Accepted March 20, 2000.)

Acta Derm Venereol 2000; 80: 294–296.

Kiriaki Aroni, Department of Anatomic Pathology, The Athens University Medical School, 75 Mikras Assias Str., Goudi, GR-115 27, Athens, Greece.
E-mail: alazaris@cc.uoa.gr

Human papillomaviruses (HPVs) are small DNA viruses with the ability to produce a variety of proliferative epithelial lesions at specific sites throughout the body. Among >100 types of HPV identified so far, HPV16, 18 and, less frequently, 31, 33 and 35 are associated with high-grade dysplasia and invasive carcinoma.

Approximately 95% of all invasive cancers of the uterine cervix are associated with HPV-DNA. Furthermore, *in vitro* transfection of human keratinocytes with HPV16 and 18 results in malignant transformation of these cells (1). In contrast to cervical cancer, the role of HPV in squamous cell carcinoma of the vulva is unclear (2–4). Warty carcinoma of the vulva is microscopically distinct from verrucous carcinoma; warty carcinomas represent squamous cell carcinomas in which the tumour cells display pleomorphism, enlargement, atypia and multinucleation. Warty carcinomas of the vulva appear to be HPV-related, whereas keratinizing squamous carcinomas are not. Regarding anal carcinomas, it has been postulated that two distinct populations may exist, on the basis of HPV status, with different clinical and pathological features (4). Concerning the penis, in addition to condylomata acuminata, the association of penile carcinoma with HPV has also been demonstrated; verrucous carcinomas (with an extremely well-differentiated cytological appearance through-

out) are also encountered in the glans penis and are probably identical to the lesion known as giant condyloma acuminatum of Buschke and Lowenstein.

In general, dermatologists are scarcely familiar with the term warty carcinoma of the skin. In this report, we present a case of neoplasm with morphology compatible with warty carcinoma which developed in the epidermis of the thigh of an adult patient. To our knowledge, such a primary location for a warty carcinoma is extremely rare, although cutaneous warty lesions that show the histological features of verrucous epidermal nevi rarely develop malignant transformation (5). Furthermore, HPV16-associated squamous cell carcinomas (SCC) of the warty type, with the presence of koilocytosis, have been described periungually (6). Koilocytic atypia has previously also been demonstrated in a HPV2-associated verrucous carcinoma of the foot (7).

CASE REPORT

Clinical findings

A 64-year-old man with no evidence of genital or anal warts presented with an 8-year history of an exophytic, cutaneous mass, measuring 13 cm at its maximum diameter (Fig. 1). The tumour was located on the inner surface of the thigh. Five years after total surgical excision of the neoplasm the patient is still disease-free.

Methods

The tumour was fixed in buffered formalin. Haematoxylin and eosin (HE)-stained slides and unstained sections for *in situ* hybridization (ISH) were prepared from the blocks. The first section from each block was stained with HE; successive sections were mounted on sialinated slides and ISH was performed using biotin-labelled HPV-DNA probes for HPV types 6/11, 16/18, 31/33, 35, 42, 43, 44, 51, 52 and 56 (Enzo, Diagnostics Inc., New York). Biotinylated plasmid pBR 322 DNA was used as the control probe. Before hybridization, sections were optimally digested with 200 µg/ml proteinase K (Sigma) for 45–80 min at room temperature. The hybridization mixture consisted of deionized formamide (50%), dextran sulphate (5%), sodium chloride citrate (0.15 M), sheared herring sperm DNA (100 µg/ml), sodium dodecylsulphate (SDS, 0.1%) and the biotin-labelled probe (1 µg/ml). Probe and target DNA were denatured simultaneously for 8 min at 90°C and hybridization was carried out at 42°C overnight. Following washes with sodium chloride citrate (×2) for 30 min at room temperature and ×2 for 20 min at 40°C, the hybridized probes were detected with mouse anti-biotin monoclonal antibody, followed by biotinylated rabbit anti-mouse Ig and avidin–biotin–peroxidase complex, and developed with 3,3'-diaminobenzidine tetrahydrochloride. Sections from cervical and skin biopsies with known HPV infection were used as positive controls.

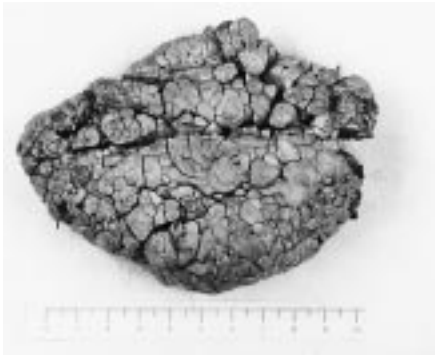

Fig. 1. Macroscopic appearance of the tumour.

Histological findings

On microscopic examination the surface of the tumour was papillary and covered by hyperkeratotic and acanthotic squamous epithelium containing fibrovascular cores. In deeper parts of the tumour, basaloid cells sometimes predominated, where we define basaloid cells as small, uniform, dark-stained tumour cells with peripheral palisading. Focal deposition of melanin was evident in such areas of basaloid differentiation. In addition to basaloid features, the tumour showed evidence of keratinizing squamous differentiation and, quite abruptly, at the deep interface between the tumour and the stroma the tumour's squamous component comprised jagged, irregularly shaped epithelial nests, which only occasionally formed squamous pearls, and were compatible with invasion.

At one edge of the specimen condylomatous morphology was observed. Minimal cytological atypia was focally detectable, with intensive HPV-related koilocytosis. In some areas the number of dendritic melanocytes was increased and a number of mitoses, some with atypical features, as well as some dyskeratotic cells were noticeable. An increase in cytological atypia was noticed, accompanied by an increasing number of atypical mitoses, squamous eddies and keratinous cysts. In most parts of the upper layers cellular orientation was partially retained. In the dermis fibroblastic reaction was evident with a predominant presence of a vascular net and evidence of plasmacytic inflammation infiltrates. In the relatively few areas of neoplastic invasion of the fibrovascular cores, inflammatory reaction was reinforced. At the other end of the lesion, condylomatous areas alternated with malignant ones. In the invasive (squamous) compartment, the individual (squamous) cells displayed nuclear pleomorphism and moderate cytological atypia barely consistent with the koilocytotic type (i.e. nuclear enlargement and hyperchromasia, wrinkling of the nuclear membrane and, rarely, multinucleation). The above histopathological findings permit the diagnosis of a cutaneous carcinoma of the warty type.

The presence of characteristic orange–brown deposits in the nuclei of the squamous epithelium was recorded as a positive ISH reaction; the type of HPV, the distribution of positive cells and the possible relationship to squamous or basaloid forms and to koilocytosis were also registered. A distinct punctate intranuclear signal for HPV16 DNA representing integrated virus (8) was present in squamous regions and correlated with koilocytosis in the superficial portion of the squamous compartment (Figs 2 and 3); ISH failed to detect HPV either in deeper regions or in areas of basaloid differentiation.

DISCUSSION

In gynaecological literature, SCC are graded as well-, moderately- and poorly differentiated and may be further categorized thus: (i) typical SCC, being concordant with the term “well differentiated and keratinizing type of SCC” and which can be associated with lichen sclerosus et atrophicus;

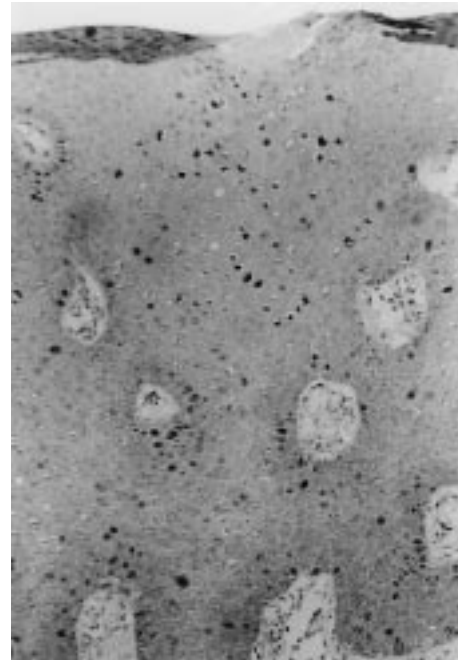


Fig. 2. HPV16 detected in squamous cells (ISH; original magnification $\times 250$).

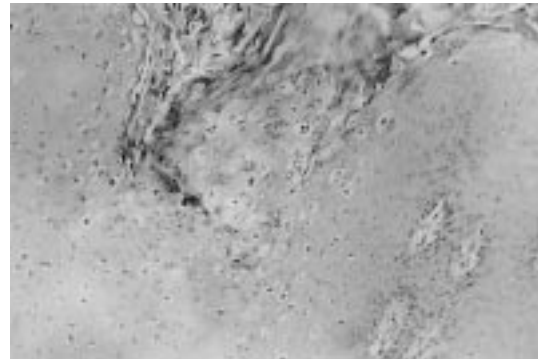


Fig. 3. Negative HPV6 reactivity in koilocytes and other squamous cells (ISH; original magnification $\times 250$).

(ii) warty SCC, characterized by an exophytic appearance and cells exhibiting koilocytosis; and (iii) basaloid SCC (9).

It is a fact that SCC with striking condylomatous features microscopically are designated as warty carcinomas. Dermatologists should realize that, like verrucous carcinomas, warty carcinomas appear to have a less aggressive behaviour than typical, HPV-negative, well-differentiated SCC (3). Microscopically, warty carcinomas have the appearance of SCC at the deep margin but show striking condylomatous features at the upper part, as in the present case. This morphology is in agreement with our ISH findings. The signal of HPV16, arguably a highly oncogenic HPV type (3, 10–12), was shown to be most prominent in superficial areas, corresponding to histological evidence of HPV infection, and absent within deep and invasive elements as well as within areas of basaloid appearance. Concerning the latter areas, basaloid changes are considered to represent further pathways of differentiation superimposed on an essentially squamous background (4).

HPV16 DNA, which was detected in the present tumour,

has been commonly linked with both genital neoplasia and cutaneous bowenoid lesions (13). Hybridization signals among the positive cells often vary in intensity and distribution and can be classified into three distinct patterns: weak diffuse nuclear staining, suggested as indicative of episomal, non-productive infection; strong nuclear staining with cytoplasmic positivity; and a distinct punctate nuclear signal suggested, in cervical carcinoma (10), to represent viral integration. In the present tumour we observed only the last type of signal.

Relative to differential diagnosis, warty (condylomatous) carcinoma is a type of squamous carcinoma associated with HPV, particularly type 16, and often contains a basaloid component (1). The gross appearance of warty carcinomas may resemble verrucous carcinomas (11), being large and exophytic with a papillary configuration. In fact, based on these striking verruciform features, the tumour has been designated warty or condylomatous carcinoma. There is, however, a special type of HPV6-related verrucous carcinoma known as the "giant condyloma of Buschke and Loewenstein"; its dimensions and general macroscopic appearance are compatible with the present case. It should be borne in mind that the most frequent location of a Buschke–Loewenstein tumour is the glans penis and foreskin; such a tumour may also occur on the vulva and in the anal region, but never on the skin of the thigh. Although verrucous carcinoma, on gross examination, does have a warty, fungating appearance, in a cut section its deep margin is characteristically sharply circumscribed. Microscopically, verrucous carcinoma is exophytic, with an undulating hyperkeratinized surface composed of rounded or pointed papillary projections which, however, lack fibrovascular cores. This lack of fibrovascular cores is particularly useful in distinguishing a verrucous carcinoma from a condyloma acuminatum or a warty (condylomatous) carcinoma, both of which display prominent fibrovascular cores. In addition, within the tumour mass, many of the malignant cells of warty carcinoma display koilocytotic atypia and greater nuclear atypia than verrucous carcinoma or Buschke–Loewenstein tumours. The deep margin of a warty carcinoma displays typical features of the usual form of invasive SCC whereas the deep margin of a verrucous carcinoma is composed of large bulbous masses that invade along a wide front in a pushing fashion. Concerning the differential diagnosis of warty carcinoma and ordinary, (keratinizing) SCC, the papillary appearance of the former and the marked keratinization in

the centre of the rounded epithelial nests of the latter are important (2).

REFERENCES

1. Petry KU, Kochel H, Bode U, Schedel I, Niesert S, Glaubitz M, et al. Human papillomavirus is associated with the frequent detection of warty and basaloid high-grade neoplasia of the vulva and cervical neoplasia among immunocompromised women. *Gynecol Oncol* 1996; 60: 30–34.
2. Trimble CL, Hildesheim A, Brinton LA, Shah KV, Kurman RJ. Heterogeneous etiology of squamous carcinoma of the vulva. *Obstet Gynecol* 1996; 87: 59–64.
3. Monk BJ, Burger RA, Lin F, Parham G, Vasilev SA, Wilczynski SP. Prognostic significance of human papillomavirus DNA in vulvar carcinoma. *Obstet Gynecol* 1995; 85: 709–715.
4. Williams GR, Lu QL, Love SB, Talbot IC, Northover JMA. Properties of HPV-positive and HPV-negative anal carcinomas. *J Pathol* 1996; 180: 378–382.
5. Ichikawa T, Saiki M, Kaneko M, Saida T. Squamous cell carcinoma arising in a verrucous epidermal nevus. *Dermatology* 1996; 193: 135–138.
6. Ashinoff R, Li JJ, Jacobson M, Friedman-Kien AE, Geronemus RG. Detection of human papillomavirus DNA in squamous cell carcinoma of the nail and finger determined by polymerase chain reaction. *Arch Dermatol* 1991; 127: 1813–1818.
7. Noel JC, Peny MO, Detremmerie O, Verhest A, Heenen M, Thiry L, et al. Demonstration of human papillomavirus type 2 in a verrucous carcinoma of the foot. *Dermatology* 1993; 187: 58–61.
8. Cooper K, Grayson W. Interpretation of the signal patterns produced by NISH in cervical neoplasia harbouring HPV [comment]. *J Pathol* 1997; 183: 126.
9. Vilmer C, Cavalier-Balloy B, Nogues C, Trassard M, Le Doussal V. Analysis of alterations adjacent to invasive vulvar carcinoma and their relationship with the associated carcinoma: a study of 67 cases. *Eur J Gynaecol Oncol* 1998; 19: 25–31.
10. Kurman RJ, Norris H, Wilkinson E. Human papillomaviruses and cancer of the lower female genital tract. In: Rosai J, Sobin N, eds. *Atlas of tumor pathology: tumors of the cervix, vagina, and vulva*, 3rd series. AFIP, Washington, D.C., 1992: 19–28.
11. Gregoire L, Cubilla AL, Reuter VE, Haas GP, Lancaster WD. Preferential association of human papillomavirus with high-grade histologic variants of penile-invasive squamous cell carcinoma. *J Natl Cancer Inst* 1995; 87: 1705–1709.
12. Junge J, Poulsen H, Horn T, Hørding U, Lundvall F. Prognosis of vulvar dysplasia and carcinoma in situ with special reference to histology and types of human papillomavirus (HPV). *APMIS* 1997; 105: 963–971.
13. Ostrow RS, Shaver MK, Turnquist S, Viksnins A, Bender M, Vance C, et al. Human papillomavirus-16 DNA in a cutaneous invasive cancer. *Arch Dermatol* 1989; 125: 666–669.