

CLINICAL REPORT

Papular Palmoplantar Hyperkeratosis Following Chronic Medical Exposure to Arsenic: Human Papillomavirus as a Co-factor in the Pathogenesis of Arsenical Keratosis?

R. GERDSEN¹, E. STOCKFLETH², M. UERLICH¹, M. FARTASCH³, K. H. STEEN¹ and T. BIEBER¹

Department of Dermatology, ¹University of Bonn, ²University of Kiel and ³University of Erlangen, Germany

This study presents the case of a 38-year-old patient from Pakistan with vitiligo, who developed multiple verrucous papules on the palms and soles several years after receiving “herbal treatment” from a travelling Indian doctor for a period of 12 months. Histopathological examination showed changes consistent with the diagnosis of arsenical keratosis. Molecular-biological examination of a skin biopsy detected an atypical human papillomavirus. This observation supports the concept of human papillomavirus as a co-factor in the pathogenesis of premalignant arsenic-induced skin tumours. *Key words: arsenical keratosis; Indian ethnic remedy; human papillomavirus.*

(Accepted February 28, 2000.)

Acta Derm Venereol 2000; 80: 292–293.

Rainer GerdSEN, Klinik und Poliklinik für Dermatologie, Sigmund Freud Strasse 25, D-53105, Bonn, Germany

Chronic arsenic intoxication has been described in patients with a history of environmental, occupational and medical exposure to arsenic (1–3).

In the past, arsenic was used to treat a variety of clinical conditions. Within the field of dermatology Fowler’s solution (1% potassium arsenite) used to be an accepted treatment for patients with psoriasis (1, 2). At present, arsenic remains a part of preparations used in Chinese propriety medicines (3) and traditional Indian ethnic remedies (4).

Vitiligo is a disorder of pigmentation presenting with hypomelanotic macules, particularly in areas that are normally hyperpigmented. The incidence in the racially pigmented population appears to be higher than in other populations (5). The family history is positive in up to 40% of patients (5) and association with autoimmune conditions such as Hashimoto’s disease has been described (6). The response to treatment is unsatisfactory (5).

CASE REPORT

A 38-year-old female patient from Pakistan presented with verrucous papules on her palms and soles. These had developed 3 years after she had been treated orally with a herbal solution by a travelling Indian doctor for a period of 12 months for “white spot disease”.

Clinical examination revealed widespread depigmented macules on the trunk and limbs, suggestive of vitiligo. In addition, she showed multiple hyperkeratotic papules on her palms (Fig. 1) and soles, some of which were coalescing into large leathery plaques. A histological examination showed compact hyperkeratosis, intermittent columns of parakeratosis and an acanthotic epidermis with minor nuclear atypicity (Fig. 2).

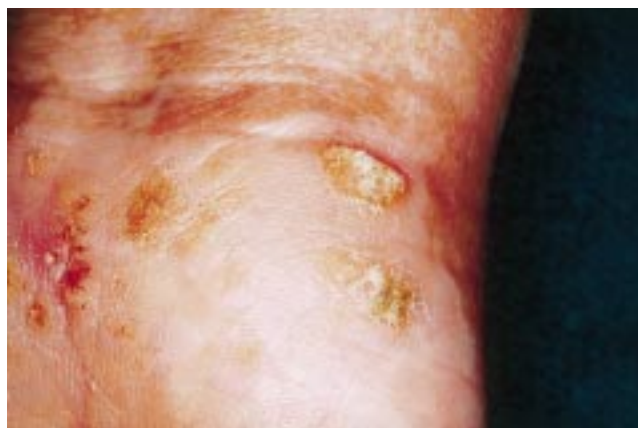


Fig. 1. Arsenical keratosis: close up of lesions on the thenar border of the right palm.

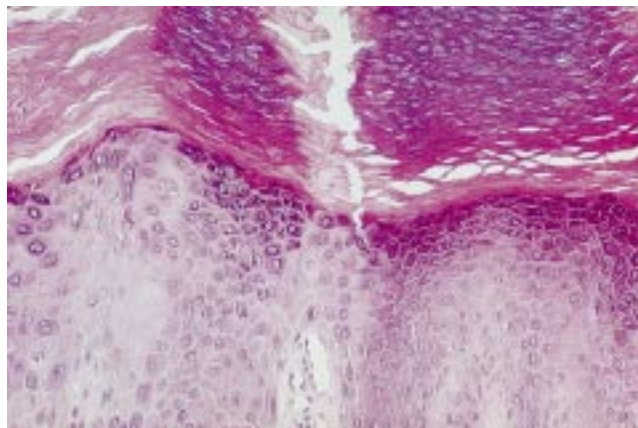


Fig. 2. Histology of a palmar lesion: compact orthohyperkeratosis and parakeratosis overlying an acanthotic epidermis, with only minor keratinocytic dysplasia. (Haematoxylin and eosin; original magnification $\times 400$.)

Polymerase chain reaction (PCR) analysis with degenerate primers identified an atypical human papillomavirus (HPV). Sequencing revealed an RX-variant of HPV, type 23.

There were no additional signs of chronic arsenic intoxication, and clinical, radiographic and laboratory investigation showed no evidence of an internal malignancy.

A topical treatment with 10% salicylic acid in white soft paraffin and cryotherapy was initiated.

At the follow-up examination 2 weeks later, a marked improvement was noticeable with only minor skin lesions left on the palms and less prominent lesions on both plantar areas.

The patient was advised to use topical tazarotene (0.1% gel) and regular follow-up examinations at 3-month intervals were arranged.

DISCUSSION

Nowadays intoxication with arsenic is mainly caused either by environmental exposure to arsenic or by taking Chinese propriety medicines and traditional Indian ethnic remedies (1–4). Physicians in the western world may be confronted by this problem owing to the increased geographical mobility of patients, who develop symptoms many years after arsenic exposure in their home countries.

Cutaneous hypermelanosis is a known side-effect of arsenic ingestion (2). This appears to be the reason for the use of an arsenic-containing ethnic remedy in this patient with extensive disfiguring vitiligo. Arsenical keratosis, Bowen's disease, basal cell carcinoma, Aldrich Mees lines and hypopigmentation are other clinical signs of arsenic intoxication (2, 3). Late sequelae also include peripheral neuropathy and liver cirrhosis (2).

Arsenic exposure is also associated with the development of skin cancer (squamous cell carcinoma) and visceral malignancies (lung cancer, urinary tract cancer, hepatic neoplasms, leukaemia and lymphomas) (1–3).

With a latency phase of between 2 and more than 30 years after exposure to arsenic multiple hyperkeratotic papules develop on the palms and soles, sometimes coalescing into verrucous leathery plaques (3, 6). Histopathological examination reveals compact orthohyperkeratosis and parahyperkeratosis overlying an acanthotic epidermis with varying degrees of keratinocytic dysplasia (2).

Excisional surgery, cryosurgery, curettage, topical chemotherapy, topical photodynamic therapy and systemic retinoids have been used in the treatment of arsenical keratosis (2, 8, 9).

The role of HPV in the development of arsenic-induced skin lesions has been discussed but remains controversial. HPV type 41 was detected in 1 of 3 arsenical keratoses examined in a 1987 study (10). In another study from 1992, only 1 of 21 arsenical keratoses was positive for HPV (11).

In the present patient, HPV DNA was detected and analysed in a biopsy from lesional skin, using highly sensitive techniques according to recently published data (12–14). Two different sets of L1-consensus primers were used in a nested PCR assay. The PCR products were then sequenced using fluorescence-labelled dideoxynucleotides.

Sequencing revealed an RX-variant of HPV, type 23. This virus belongs to the group of HPV-types associated with epidermodysplasia verruciformis (15). The detection of HPV-type 23 may suggest a pathogenic role for HPV as a cofactor in the development and carcinogenic transformation of arsenical keratoses and arsenic-induced skin tumours in general. Examination of higher numbers of biopsies from

arsenical keratoses and other arsenic-related skin lesions such as Bowen's disease and basal cell carcinoma is required to investigate this further.

REFERENCES

1. Maloney ME. Arsenic in dermatology. *Dermatol Surg* 1996; 22: 301–304.
2. Schwarz RA. Arsenic and the skin. *Int J Dermatol* 1997; 36: 241–250.
3. Wong SS, Tan KC, Goh CL. Cutaneous manifestations of chronic arsenicism: review of seventeen cases. *J Am Acad Dermatol* 1998; 38: 179–185.
4. Kew J, Morris C, Aihie A, Fysh R, Jones S, Brooks D. Arsenic and mercury intoxication due to Indian ethnic remedies. *Br Med J* 1993; 306: 506–507.
5. Bleehen SS. Disorders of skin colour. In: Champion RH, Burton J, Burns DA, Breathnach SM, eds. *Textbook of dermatology*. 6th edn, Vol. 2. Oxford: Blackwell Scientific: 1802–1805.
6. Schallreuter KU, Lemke R, Brandt O, Schwartz R, Westhoven M, Montz R, Berger J. Vitiligo and other diseases: coexistence or true association? Hamburg study on 321 patients. *Dermatology* 1994; 188: 269–275.
7. Rueff F, Przybilla B. Präaligne und maligne Hautveränderungen nach Therapie mit Arsen. Begutachtung einer Behandlung in der 70er Jahren aus derzeitiger Sicht. *Dermatosen* 1992; 40: 115–419.
8. Bickley LK, Papa CM. Chronic arsenicism with vitiligo, hyperthyroidism and cancer. *New Jersey Med* 1989; 86: 377–380.
9. Szeimes RM, Karrer S, Heine A, Hohenleutner U, Landthaler M. Arsenic-induced skin tumours treated with topical photodynamic therapy after application of 5-aminolevulinic acid. *Eur J Dermatol* 1995; 5: 208–211.
10. Neumann C, De Villiers EM, Grimm M, zur Hausen H. Human papilloma virus in arsenical skin lesions. *J Invest Dermatol* 1987; 89: 448.
11. Ratman KV, Espy MJ, Muller SA, Smith TF, Su WPD. Clinicopathologic study of arsenic-induced skin lesions: no definite association with human papillomavirus. *J Am Acad Dermatol* 1992; 27: 120–122.
12. Stockfleth E, Meinke B, Christophers E, Meyer T. Identification of DNA sequences of both genital and cutaneous HPV types in a small number of keratoacanthomas of non-immunosuppressed patients. *Dermatology* 1999; 198: 122–125.
13. Meyer T, Arndt R, Stockfleth E, Flamman HT, Wolf H, Reischl U. Strategy for typing human papillomavirus by RFLP analysis of PCR products and subsequent hybridization with a generic probe. *BioTechniques* 1999; 19: 632–639.
14. Nindl I, Jacobs M, Walboomers J, Pfister H, Meyer T, Stockfleth E, et al. Interlaboratory agreement of different human papillomavirus DNA detection and typing assays in cervical smears. *Int J Cancer* 1999; 81: 666–668.
15. De Villiers EM, Lavergne D, McLaren K, Benton EC. Prevailing papilloma virus types in non-melanoma carcinomas of the skin in renal allograft recipients. *Int J Cancer* 1997; 73: 356–161.