

CLINICAL REPORT

Increased Coexpression of Eotaxin and Interleukin 5 in Bullous Pemphigoid

M. SHRIKHANDE^{1,2}, T. HUNZIKER², L. R. BRAATHEN², W. J. PICHLER¹, C. A. DAHINDEN³ and N. YAWALKAR^{1,2}

¹Clinic for Rheumatology and Clinical Immunology/Allergology, ²Department of Dermatology and ³Institute of Immunology and Allergology, University of Bern, Bern, Switzerland

While the presence of eosinophils in the skin lesions of bullous pemphigoid is well documented, the chemotactic factors responsible for eosinophil recruitment into the tissue still remain to be defined. In this study, eotaxin and interleukin-5 (IL-5) concentrations were determined in the blister fluid and sera of patients with bullous pemphigoid (acute and remission phase, $n=6$) in comparison with normal healthy controls ($n=6$) using the enzyme-linked immunosorbent assay (ELISA) technique. Eotaxin and IL-5 levels were increased in the blister fluid compared with the acute and remission phase sera, as well as compared with the sera of normal controls. In addition, immunoreactivity for eotaxin was predominantly found in the inflammatory cell infiltrate of lesional bullous pemphigoid biopsy specimens. In conclusion, the data provide evidence that co-operation of eotaxin and IL-5 may play an essential role in activating and recruiting eosinophils, which ultimately contribute to the tissue damage in bullous pemphigoid. **Key words:** chemokine; cytokine; immunohistochemistry; ELISA.

(Accepted 17 April 2000.)

Acta Derm Venereol 2000; 80: 277–280.

N. Yawalkar, Clinic for Rheumatology and Clinical Immunology/Allergology, Inselspital, CH-3010, Bern, Switzerland. E-mail: nikhil.yawalkar@insel.ch

Bullous pemphigoid (BP) is an autoimmune blistering skin disease characterized by large tense bullae and the presence of autoantibodies against antigens in the dermoepidermal junction. These autoantibodies exert an important pathogenic role in blister formation (1). Histologically, BP skin lesions demonstrate an inflammatory superficial dermal infiltrate comprising mainly eosinophils, lymphocytes and histiocytes. This inflammation in BP is believed to be, at least in part, a result of eosinophil-dependent tissue injury (2). Upon activation the eosinophils release various toxic granule proteins, such as eosinophilic cationic protein (ECP), major basic protein and eosinophil peroxidase. However, the chemotactic factors responsible for the recruitment of eosinophils into the skin lesions have largely remained unknown so far.

Eotaxin, a cysteine–cysteine (C-C) chemokine, is a potent chemoattractant and activator of eosinophils (3) and basophils (4). Recent reports suggest that it also is a main attractant for Th2 lymphocytes (5, 6). The activities of eotaxin are mediated by binding to the chemokine receptor CCR3, which is expressed on eosinophils (3, 7), basophils (4), dendritic cells (8) and Th2 lymphocytes (5, 6).

Increasing evidence indicates co-operation between eotaxin and interleukin-5 (IL-5) in inducing optimal activation and recruitment of eosinophils (9, 10). The present study was therefore designed to study the expression of both factors in the blister fluid and sera of patients suffering from BP.

MATERIALS AND METHODS

Subjects

Six Caucasian patients with recent-onset BP (3 males and 3 females, mean age 74, range 65–84 years) and 6 age- and sex-matched healthy controls were included in the study after their informed consent was obtained. The diagnosis was based on typical clinical presentation, histology, and direct and indirect immunofluorescence findings.

Collection of blister fluid and sera

Blister fluid was obtained from tense blisters, approximately 24 h old. Acute-phase sera were obtained on the same day as blister puncture. At this time, bullous eruptions covered approximately 30–40% of the body surface. Remission-phase sera were collected approximately 3–4 months later, when the patients exhibited no blisters and were receiving treatment with varying doses of prednisone (10–15 mg) with or without azathioprine (50–100 mg). Blister fluids and sera were stored in aliquots at -20°C until analysis.

Skin specimens

Punch biopsy specimens of 5 mm diameter were taken from the edge of a fresh (<24 h old) blister during the acute phase of the disease. Normal skin from 6 non-atopic controls was obtained from patients undergoing reconstructive surgery. Tissue samples were snap-frozen in tissue-embedding medium using isopentane precooled in liquid nitrogen and stored at -70°C until used.

Analysis of cytokines and eosinophilic cationic protein

Human eotaxin was measured in blister fluid and sera using a commercially available enzyme-linked immunosorbent assay (ELISA) kit (R&D Systems, Minneapolis, MN, USA) according to the manufacturer's instructions. Human IL-5 was detected with a cytokine-specific sandwich ELISA using monoclonal antibody pairs (native capture mAb and biotinylated detecting mAb, all obtained from PharMingen Beckon Dickinson, Mountain View, CA, USA) as described previously (11). ECP was measured using a fluoroenzyme immunoassay (UniCAP[®] ECP; Pharmacia, Uppsala, Sweden). All analyses were performed in duplicate. The detection limits of the assays were 3 pg/ml for eotaxin, 5 pg/ml for IL-5 and 0.5 $\mu\text{g/l}$ for ECP.

Immunohistochemistry

Immunostaining of skin sections was performed using (mouse monoclonal) anti-eotaxin antibodies (clone 3C7, concentration 50 µg/ml; PharMingen/Beckon Dickinson) according to the avidin–biotin complex/alkaline phosphatase (ABC/AP) method. Sections of 5 µm were fixed in 2% formaldehyde for 8 min. Slides were then incubated overnight with the primary antibody, followed by a biotinylated rabbit-anti-mouse immunoglobulin G (IgG) (dilution 1:200, E0413; DAKO) and thereafter with ABC/AP (dilution 1:50; K0376; DAKO). Finally, all sections were developed in new fuchsin–naphthol (DAKO® Fuchsin Substrate) and counterstained with haematoxylin. Substitution of the primary antibody with isotype-matched IgG and omission of the primary antibody served as negative controls.

Evaluation of skin sections

The numbers of eosinophils on skin sections stained with haematoxylin & eosin (H&E) and eotaxin-positive cells were assessed on 10–15 fields of each section at 400× magnification with a Leitz Dialux 20EB and counted using a 0.09 mm² grid. The number of positive cells (mean ± SEM) per mm² was calculated.

Statistical analysis

Statistical analysis was performed using the Mann–Whitney *U*-test for the unpaired and Wilcoxon rank test for the paired samples.

RESULTS*Increased levels of eosinophils, eosinophilic proteins and interleukin-5 protein in bullous pemphigoid*

Eosinophil numbers in blood and tissue as well as ECP values are summarized in Table I. In comparison to normal controls, a significantly increased number of eosinophils in the blood ($p < 0.004$) and raised serum levels of ECP ($p < 0.004$) were observed in the patients with BP, which corresponds to previous reports (12). In addition, a significantly increased number of eosinophils per mm² was documented in the H&E-stained BP skin sections ($p < 0.002$) compared with normal skin.

As also demonstrated in Table I, markedly increased levels of eotaxin were detected in the blister fluid of patients with BP compared with their sera in the acute phase and remission phase, as well as with sera from healthy controls. Eotaxin levels in the sera of the acute phase were also higher than those of the remission phase or those from healthy controls,

although the differences were just not statistically significant ($p = 0.055$ and $p = 0.058$, respectively).

Levels of IL-5 were high in the blister fluid (1492 ± 782.1 pg/ml) and in the sera of the acute-phase patients with BP (55.5 ± 49 pg/ml) (not shown in Table I). The serum levels of IL-5 were below the detection limits (< 5 pg/ml) during remission and in the normal controls.

Enhanced immunoreactivity for eotaxin in bullous pemphigoid skin lesions

Localization of eotaxin is shown as a representative example in Fig. 1. Positive immunostaining for eotaxin was predominantly detected in the inflammatory cell infiltrate in the dermis of the BP lesions. Some endothelial cells and fibroblasts as well as a few eosinophils and basal keratinocytes also focally demonstrated immunoreactivity for eotaxin. A significantly ($p < 0.002$) higher mean number of positive cells per mm² was found in the BP lesions (93.8 ± 11.4) compared with normal skin (10.2 ± 0.8). No positive staining was seen on substitution of the primary antibody with an isotype-matched IgG (not shown).

DISCUSSION

The results demonstrate that both eotaxin and IL-5 levels are markedly increased in skin blisters of patients with BP compared with the sera of the same patients and healthy controls. In addition, immunohistochemical staining of lesional skin biopsies revealed enhanced expression of eotaxin in BP, predominantly within the inflammatory cell infiltrate.

Eotaxin is considered to be an important chemokine for the recruitment and degranulation of eosinophils (9). Recent studies have demonstrated an increased expression of eotaxin in diseases with eosinophilic infiltration such as bronchial asthma (13–15), chronic sinusitis (16), inflammatory bowel disease (17) and atopic dermatitis (18). The enhanced expression of eotaxin, particularly in the blister fluid of BP, indicates that this chemokine may also play an important role in the pathomechanism of this autoimmune bullous skin disease by recruiting and activating eosinophils.

Immunoreactivity for eotaxin was mainly observed in the mononuclear cell infiltrate, indicating that macrophages and T-cells could be a source of eotaxin. In the present study, double immunostaining experiments to identify precisely these mononuclear cells were not feasible. However, recent data on allergen-induced late-phase cutaneous responses indeed indi-

Table I. *Eosinophilic cationic protein, eosinophils and eotaxin in blood, skin biopsy specimens and blister fluid*

	Bullous pemphigoid (n=6)	Controls (n=6)	<i>p</i> -Values
ECP (µg/l) in serum	29 ± 7.9	5.6 ± 1.2	<0.004
Eosinophils (10 ⁹ /l) in blood	1.1 ± 0.38	0.1 ± 0.04	<0.004
Eosinophils/mm ² skin section	82.8 ± 14.5	0.5 ± 0.3	<0.002
Eotaxin (pg/ml) in serum	Acute phase: 215 ± 46.2		
	Remission phase: 131.8 ± 39.5	149.3 ± 12	NS
Eotaxin (pg/ml) in blister fluid	457.6 ± 56.5		

Data are shown as means ± SEM.

NS: not significant.

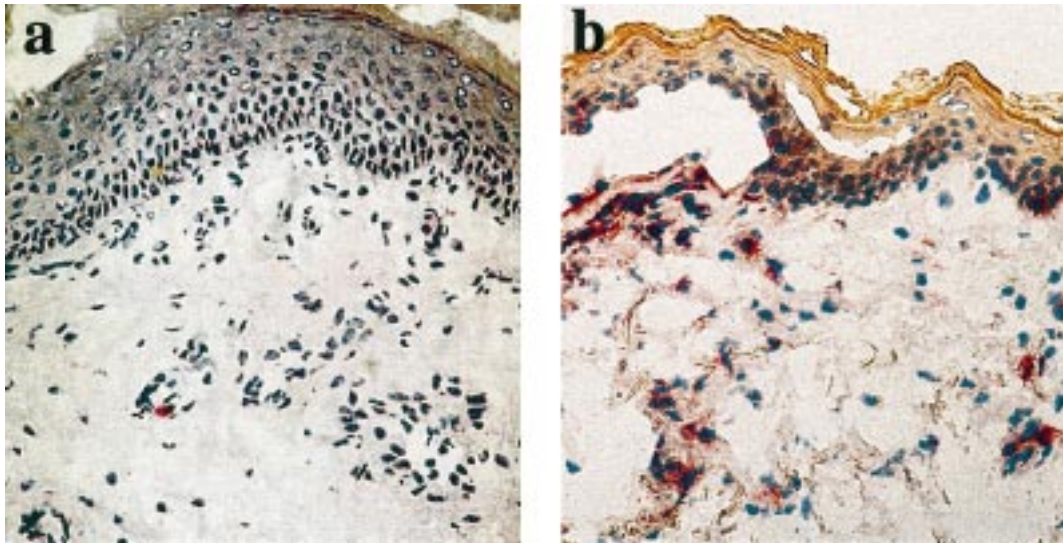


Fig. 1. Eotaxin immunoreactivity in bullous pemphigoid (BP) and normal skin. Skin sections from 1 patient with BP and 1 healthy control are shown as representative examples. Few eotaxin positive cells are detected in the dermis of normal skin (a). In contrast, an increased number of cells positive for eotaxin is present predominantly in the dermis of BP skin lesions (b). ABC/AP method, original magnification $\times 250$.

cate that both CD68⁺ macrophages and CD3⁺ T-cells are capable of producing eotaxin (19).

IL-5 is known to be a key factor in the differentiation and activation of eosinophils. In accordance with previous reports (20–22), levels of IL-5 were also markedly raised in the blister fluid and acute phase sera of these BP patients. These data point to a synergistic effect of eotaxin and IL-5 on the maturation, activation and recruitment of eosinophils in BP. Therefore, it is most likely that eotaxin in co-operation with IL-5 promotes the maturation and activation of eosinophils in the bone marrow as well as their rapid release into the circulation (9). Subsequently, increased numbers of eosinophils are attracted into the skin via up-regulation of eotaxin at the site of inflammation, where elevated levels of IL-5 further enhance the activation and survival of these cells.

Besides IL-5, other type 2 cytokines such as IL-4, IL-10 and IL-13 have also been reported to be up-regulated in BP (23). These data suggest a dominant recruitment of T-helper (Th2) lymphocytes within the inflammatory cell infiltrate, although other proinflammatory cytokines such as tumour necrosis factor- α (TNF α) and interferon- γ have also been reported (24). The eotaxin receptor CCR3 has been shown to be selectively expressed on some Th2 lymphocytes (5, 6). Besides its action on eosinophils, eotaxin might therefore also substantially contribute to the recruitment of Th2 lymphocytes into BP lesions. In turn, this mechanism could be of particular relevance to the *in situ* up-regulation of eotaxin, since IL-4 and IL-13, together with other proinflammatory cytokines such as TNF α , have been reported to stimulate the production of eotaxin (25, 26). Furthermore, IL-5 has also been shown to up-regulate CCR3 on eosinophils (27), which again could amplify the recruitment of this cell type to the site of eotaxin expression. Thus, a complex cascade of positive feedback mechanisms involving eotaxin and IL-5 may help to sustain inflammation in BP.

In conclusion, the results provide further evidence for co-operation between eotaxin and IL-5 in the recruitment and

activation of eosinophils and thus suggest an important role for these factors in the pathogenesis of BP.

ACKNOWLEDGEMENTS

We thank J. Mirkovitch and A. Urwyler for excellent technical help. Supported by Swiss National Science Foundation grant 32-48885.96, SCORE B (to N.Y.) and SNF no. 3100-053000 (to C.A.D.).

REFERENCES

- Liu Z, Diaz LA, Troy JL, Taylor AF, Emery DJ, Fairley JA, Giudice GJ. A passive transfer model of the organ-specific autoimmune disease, bullous pemphigoid, using antibodies generated against the hemidesmosomal antigen, BP180. *J Clin Invest* 1993; 92: 2480–2488.
- Borrego L, Maynard B, Peterson EA, George T, Iglesias L, Peters MS, et al. Deposition of eosinophil granule proteins precedes blister formation in bullous pemphigoid. Comparison with neutrophil and mast cell granule proteins. *Am J Pathol* 1996; 148: 897–909.
- Ponath PD, Qin S, Post TW, Wang J, Wu L, Gerard NP, et al. Molecular cloning and characterization of a human eotaxin receptor expressed selectively on eosinophils. *J Exp Med* 1996; 183: 2437–2448.
- Ugucioni M, Mackay CR, Ochsenberger B, Loetscher P, Rhis S, LaRosa GJ, et al. High expression of the chemokine receptor CCR3 in human blood basophils. Role in activation by eotaxin, MCP-4, and other chemokines. *J Clin Invest* 1997; 100: 1137–1143.
- Gerber BO, Zanni MP, Ugucioni M, Loetscher M, Mackay CR, Pichler WJ, et al. Functional expression of the eotaxin receptor CCR3 in T lymphocytes co-localizing with eosinophils. *Curr Biol* 1997; 7: 836–843.
- Sallusto F, Mackay CR, Lanzavecchia A. Selective expression of the eotaxin receptor CCR3 by human T helper 2 cells. *Science* 1997; 277: 2005–2007.
- Daugherty BL, Siciliano SJ, DeMartino JA, Malkovitz L, Sirotna A, Springer MS. Cloning, expression and characterization of the human eosinophil eotaxin receptor. *J Exp Med* 1996; 183: 2349–2354.

8. Rubbert A, Combadiere C, Ostrowski M, Arhtos J, Dybul M, Machado E, et al. Dendritic cells express multiple chemokine receptors used as coreceptors for HIV entry. *J Immunol* 1996; 160: 3933–3941.
9. Gutierrez-Ramos JC, Lloyd C, Gonzalo JA. Eotaxin from an eosinophilic chemokine to a major regulator of allergic reactions. *Immunol Today* 1999; 20: 500–504.
10. Collins PD, Marleau S, Griffiths-Johnson DA, Jose PJ, Williams TJ. Cooperation between interleukin-5 and the chemokine eotaxin to induce eosinophil accumulation in vivo. *J Exp Med* 1995; 182: 1169–1174.
11. Hari Y, Urwyler A, Hurni M, Yawalkar N, Dahinden C, Wendland T, et al. Distinct serum cytokine levels in drug- and measles-induced exanthema. *Int Arch Allergy Immunol* 1999; 120: 225–229.
12. Caproni M, Palleschi GM, Falcos D, D'Agata A, Cappelli G, Fabbri P. Serum eosinophil cationic protein (ECP) in bullous pemphigoid. *Int J Dermatol* 1995; 34: 177–180.
13. Mattoli S, Stacey MA, Sun G, Bellini A, Marini M. Eotaxin expression and eosinophilic inflammation in asthma. *Biochem Biophys Res Commun* 1997; 236: 299–301.
14. Ying S, Robinson DS, Meng Q, Rottman J, Kennedy R, Ringler DJ, et al. Enhanced expression of eotaxin and CCR3 mRNA and protein in atopic asthma. Association with airway hyperresponsiveness and predominant co-localization of eotaxin mRNA to bronchial epithelial and endothelial cells. *Eur J Immunol* 1997; 27: 3507–3516.
15. Lamkhioued B, Renzi PM, Abi-Younes S, Garcia-Zepeda EA, Allakhverdi Z, Ghaffar O, et al. Increased expression of eotaxin in bronchoalveolar lavage and airways of asthmatics contributes to the chemotaxis of eosinophils to the site of inflammation. *J Immunol* 1997; 159: 4593–4601.
16. Minshall EM, Cameron L, Lavigne F, Leung DY, Hamilos D, Garcia-Zepeda EA, et al. Eotaxin mRNA and protein expression in chronic sinusitis and allergen-induced nasal responses in seasonal allergic rhinitis. *Am J Respir Cell Mol Biol* 1997; 17: 683–690.
17. Garcia-Zepeda EA, Rothenberg ME, Ownbey RT, Celestin J, Leder P, Luster AD. Human eotaxin is a specific chemoattractant for eosinophil cells and provides a new mechanism to explain tissue eosinophilia. *Nat Med* 1996; 2: 449–456.
18. Yawalkar N, Ugucioni M, Scharer J, Braunwalder J, Karlen S, Dewald B, et al. Enhanced expression of eotaxin and CCR3 in atopic dermatitis. *J Invest Dermatol* 1999; 113: 43–48.
19. Ying S, Robinson DS, Meng Q, Barata LT, McEuen AR, Buckley MG, et al. C-C chemokines in allergen-induced late-phase cutaneous responses in atopic subjects: association of eotaxin with early 6-hour eosinophils, and of eotaxin-2 and monocyte chemoattractant protein-4 with the later 24-hour tissue eosinophilia, and relationship to basophils and other C-C chemokines (monocyte chemoattractant protein-3 and RANTES). *J Immunol* 1999; 163: 3976–3984.
20. D'Auria L, Pietravallo M, Mastroianni A, Ferraro C, Mussi A, Bonifati C, et al. IL-5 levels in the serum and blister fluid of patients with bullous pemphigoid: correlations with eosinophil cationic protein, RANTES, IgE and disease severity. *Arch Dermatol Res* 1998; 290: 25–27.
21. Ameglio F, D'Auria L, Bonifati C, Ferraro C, Mastroianni A, Giacalone B. Cytokine pattern in blister fluid and serum of patients with bullous pemphigoid: relationships with disease intensity. *Br J Dermatol* 1998; 138: 611–614.
22. Inaoki M, Takehara K. Increased serum levels of interleukin (IL)-5, IL-6 and IL-8 in bullous pemphigoid. *J Dermatol Sci* 1998; 16: 152–157.
23. Rico MJ, Benning C, Weingart ES, Streilein RD, Hall RP III. Characterization of skin cytokines in bullous pemphigoid and pemphigus vulgaris. *Br J Dermatol* 1999; 140: 1079–1086.
24. D'Auria L, Fei PC, Ameglio F. Cytokines and bullous pemphigoid. *Eur Cytokine Netw* 1999; 10: 123–134.
25. Teran LM, Mochizuki M, Bartels J, Valencia EL, Nakajima T, Hirai K, Schroder JM. Th1- and Th2-type cytokines regulate the expression and production of eotaxin and RANTES by human lung fibroblasts. *Am J Respir Cell Mol Biol* 1999; 20: 777–786.
26. Zhu Z, Homer RJ, Wang Z, Chen Q, Geba GP, Wang J, et al. Pulmonary expression of interleukin-13 causes inflammation, mucus hypersecretion, subepithelial fibrosis, physiologic abnormalities, and eotaxin production. *J Clin Invest* 1999; 103: 779–788.
27. Tiffany HL, Alkhatib G, Combadiere C, Berger EA, Murphy PM. CC Chemokine receptors 1 and 3 differentially regulated by IL-5 during maturation of eosinophilic HL-60 cells. *J Immunol* 1998; 160: 1385–1392.