

## INVESTIGATIVE REPORT

# Expression of p21<sup>WAF1/CIP1</sup>, p53, bcl-2 and Ki-67 in Venous Leg Ulcers with and without Squamous Cell Carcinoma

BALDUR BALDURSSON<sup>1</sup>, STINA SYRJÄNEN<sup>2</sup> and HARRY BEITNER<sup>3</sup>

<sup>1</sup>Department of Dermatology, Gävle Hospital, Gävle, Sweden, <sup>2</sup>Department of Oral Pathology, Institute of Dentistry, University of Turku, Finland and <sup>3</sup>Department of Dermatology, Karolinska Hospital, Stockholm, Sweden

**In order to gain understanding of the cellular mechanisms of malignant transformation in chronic venous leg ulcers, we analysed by immunohistochemistry the presence of p21, p53, bcl-2 and Ki-67 in ulcers with and without squamous cell carcinoma. The material consisted of 41 archived histopathological samples from 33 patients with chronic venous leg ulcers and 28 samples from 21 patients suffering from squamous cell carcinoma in chronic venous leg ulcers. All samples derived from the chronic ulcers were negative for p53, p21 and bcl-2. Cells positive for Ki-67 were seen in certain ulcer areas. In the cancers, 14 samples showed immunopositivity for p53 and 22 samples were positive for p21, with expression mainly in the suprabasal layer. Expression of p21 seemed independent of p53. None of the samples was bcl-2-positive. Ki-67 was positive with basal expression in 16/28 of the tumour samples, 15 of which also expressed p21. There was no perilesional p53 or p21 activity in the cancer samples. The results regarding perilesional expression are different from those reported in UV-induced squamous cell carcinomas and probably reflect a different carcinogen. Key words: immunohistochemistry; oncogenes; carcinogenesis; leg ulcers.**

(Accepted March 13, 2000.)

Acta Derm Venereol 2000; 80: 251–255.

Baldur Baldursson, Department of Dermatology, Gävle Hospital, SE-801 87 Gävle, Sweden. baldur.baldursson@lg.se

Chronic ulcers are among the factors that, along with light in the ultraviolet (UV) wavelength, can predispose to squamous cell carcinoma (SCC) of the skin. In races where the pigment of the skin offers protection against UV light, chronic ulcers are among the main factors (1), while in Caucasians, UV radiation is the most common carcinogen (2).

In chronic venous ulcers, SCC is a known complication, which can be fatal, especially when poorly differentiated (3, 4). The non-healing state of the chronic venous ulcer probably signals that there is a derangement of proliferation regulation (5, 6). Two important steps in this control are inhibition, or the loss of inhibition of proliferation and apoptosis. We wanted to investigate these 2 processes in venous ulcers and in squamous cell carcinoma arising in venous ulcers. Well-studied cell cycle regulators in epidermal tumours are p53, a proliferation suppressor gene, and bcl-2, an apoptotic gene. We therefore studied the expression of these gene products as well as p21<sup>CIP1/WAF1</sup> (p21), a downstream product of p53, and the proliferation indicator Ki-67.

The p53 gene is a tumour suppressor gene that regulates the expression of a number of cell cycle proteins that in various ways halt cellular proliferation. It reacts to DNA damage by

stopping the cell cycle in order to repair the DNA or launch apoptosis (7). The stop is effected by transcriptional control of p21, of which p53 is the main regulator (8). The regulation of the bcl-2/bax family of proteins is also downstream from p53 (9, 10). Wild-type p53 has a short half-life and is, in the absence of a genomic strain such as UV radiation, not detectable by immunohistochemistry (IHC). A mutation can produce a stable non-functional p53 that can be stained and studied by IHC (11). However, positive staining for p53 might show a non-mutated stabilized p53, and absence of p53 staining doesn't always signal physiological downregulation; the gene might be mutated beyond recognition, neutralized or downregulated by oncogenic proteins such as MDM2 (8, 12–14). Expression of the p53 protein is found in UV-radiated skin (where it is considered to be non-mutated and stabilized), in UV-induced SCC and in precancerous *in situ* lesions, where mutations are frequently present (8, 15, 16). There are some reports of p53 expression in non-UV-induced SCC, mainly in scars, where the expression of the protein and the frequency of mutations seem to be similar to that in UV-induced SCC (12, 17). Wounding is a well-known cancer promoter and wound fluid has been shown to be tumour-promoting (18), in part through epidermal growth factor and platelet-derived growth factor (19). p53 has been shown to be downregulated in wound repair, probably to allow necessary proliferation (20–22).

A single p21 protein in conjunction with a cyclin-dependent kinase, a cyclin and a proliferative cell nuclear antigen allows progression of the cell cycle from G1 to S-phase (23). An excess of p21 brings the cell cycle to a halt at the G1 checkpoint (24, 25). This can lead to terminal differentiation, repair of a damaged DNA with subsequent progress into the S-phase, or apoptosis (26). The topographical localization of p21 expression at the basal layer, as opposed to the suprabasal layers, has been interpreted as anti-proliferative and differentiating, respectively (27, 28). Numerous studies on the expression of p21 in SCC have been done (28–30), 2 of which give deviating reports on the basal or suprabasal expression of p21 in SCC (28, 30). Mutations of the p21 gene are unusual (31). The existence of upstream inducers of p21 other than p53 is reported in a number of papers (26, 32, 33). Expression of p21 in SCC is usually independent of p53 (28, 29), even in non-skin SCCs (34, 35).

Bcl-2 is an anti-apoptotic protein (9). The deregulation of bcl-2 in oncogenesis leads to synthesis of a large amount of the bcl-2 protein, which can lead to uncontrolled cell proliferation (9). In normal skin, single cells of the basal layer can be found to express bcl-2 (36, 37). In neoplastic skin, bcl-2 has been found in basal cell carcinomas, malignant melanomas, and more seldom in SCCs (36, 38).

Ki-67 is a protein that is expressed in S, G2 and M phases of the cell cycle and is considered a reliable indicator of proliferation (39). Co-expression of Ki-67 and p21 signals proliferation despite the inhibition of proliferation that p21 represents.

Taking the above-mentioned factors into consideration, we investigated the expression of p53, p21, bcl-2 and Ki-67 in SCC in venous ulcers and in non-malignant ulcers, in order to evaluate their role in the aetiology of these cancers.

## MATERIAL AND METHODS

### Tissue samples

In an earlier study, 25 cases of SCC arising from venous leg ulcers were found through an epidemiological search (4). Tissue samples from 21 of these patients were collected from the archives of pathology laboratories in Sweden.

Additionally, archival samples taken from 33 patients with chronic venous leg ulcers were collected from the files of Dermatology and Plastic Surgery departments in hospitals in Gävle and Stockholm.

Paraffin blocks were re-sectioned and the 5 µm-thick sections were stained with hematoxylin-eosin. Only samples representing the edge of the ulcer or tumour were selected for further staining. In the group of ulcers with SCC, 28 samples were suitable for analysis. For several patients, more than 1 sample was included, either from different operations (marked i, ii, etc.) or from different parts of the same SCC, marked a, b, etc. (see Table I). In the ulcer group, 41 samples taken from 33 patients were suitable for analysis.

All biopsy samples were histologically reclassified according to whether they were poorly, moderately or well differentiated, using standard criteria (4).

### Immunohistochemistry

IHC was performed to detect expression of p53, p21, Ki-67 and bcl-2. For p53, Ki-67 and bcl-2, IHC was done using an automated staining machine (Dako TechMate 500, Dako, Copenhagen, Denmark) according to the procedure outlined by the manufacturer. The primary antibodies for p53 (DO-7, Dako, Copenhagen, Denmark), Ki-67 and bcl-2 (Dako), were ready to be used for the automated procedure. The p21 staining was done manually using the primary antibody NCL-WAF 1 (Novocastra Laboratories Ltd., Newcastle-upon-Tyne, England) in a 1:2 dilution. All sections were pre-treated in microwaves in 10 mM citric acid, pH 6.0 for 5 min. Biopsy samples from breast cancer (for p53), skin wart (for p21) and oral mucosa (for bcl-2) tested earlier to be positive were used as positive controls. As a negative control, normal serum (horse) was used instead of the primary antibody.

Semiquantitative evaluation was done by grading the intensity of the stain into 4 categories: no signal=–, weak signal=+, intermediate signal=++, strong signal=+++.

The extent of staining was graded with regard to the proportion of cells stained in the involved tissue compartment, e.g. basal cells or cancer cells assuming basal position in cell nests. Four categories were designated: no stain=0, up to 25% of the cells in the involved compartment=1, 25–50% of the cells=2, more than 50% of the cells stained positive=3.

Fisher's exact test was used to estimate the significance of the correlation between expression of Ki-67 vs. p53 and vs. p21.

## RESULTS

Analysis was done on 28 biopsy samples from patients with SCC in a chronic venous ulcer and 41 samples from chronic venous ulcers. Results of IHC staining of the group with SCC

are summarized in Table I. In the non-cancer samples, both the growing bud of the ulcer margin and the surrounding epidermis (often with signs of pseudoepitheliomatous hyperplasia) were analysed. None of the samples taken from the ulcers showed expression of p53, p21 or bcl-2. These data are therefore not listed in Table I.

### p53

Fourteen of the 28 cancer samples (50%) were p53-positive. In the positive samples, the p53 staining was detected only in the cancer cells. In 15 samples where non-neoplastic epidermis was present adjacent to the cancer, no positivity was found in the epidermal tissue.

In the SCC samples, the p53-positive cells were at the border of the cell clusters, i.e., in the cells assuming basal position (Fig. 1). In the tumours with poorer degrees of differentiation, where the tumour cells were organized in streaks of cells, again, the cells at the borders of the clusters were most likely to be positive. The staining intensity of the samples is given in Table I. Intense staining was found in 6 samples, of which 5 were moderately and 1 poorly differentiated. Only 1 of 10 well-differentiated samples stained for p53.

### p21

Positive staining for p21 was seen in 22 of the SCCs (79%). Similarly to the p53 expression, there was a tendency for the positive cells to be situated at the periphery of the cell nests. However, in only 4 lesions with no conspicuous basal layer at the periphery of the nests was p21 expressed at the basal and suprabasal layer; in the remaining 16 samples with identifiable cell nests (Fig. 2), the staining was suprabasal (see Table I).

### p53 and p21

In 6 samples, there was p53 and p21 staining at similar intensity (see Table I). When these single-stained samples were studied for positivity in the same cell groups, only 2 samples were positive in the same groups of cells for p53 and p21, both moderately differentiated.

### bcl-2

In 1 of the cancer samples, a few bcl-2-positive basal cells were found adjacent to cancerous epidermis; otherwise all samples, both the SCCs and the ulcers, were negative for bcl-2 (data not shown).

### Ki-67

In the epidermis of the chronic ulcer samples, single basal cells were positive for Ki-67 and in some samples, a proliferative area at the ulcer margin stained more intensely. In the cancer samples, 16 of the cancers showed Ki-67 expression in most of the basal cells. Of these, 15 were positive for p21 and 8 for p53. The correlation between positive p21 and Ki-67 was not quite significant ( $p=0.057$ ). There was no correlation between positive p53 and positive Ki-67.

Table I. Results of immunohistochemical staining for p53, p21 and Ki-67 in samples from squamous cell carcinoma in chronic venous leg ulcers. Proportion of positive cells at the basal or suprabasal layer in samples with well or moderately differentiated SCCs, and of the malignant cells in poorly differentiated SCCs

| Samples <sup>s</sup> | Differentiation of SCC | p53 stain | Proportion of p53-positive cells <sup>#</sup> | p21 stain       | Proportion of p21-positive cells <sup>#</sup> | Ki-67, when positive always basal |
|----------------------|------------------------|-----------|---|-----------------|---|-----------------------------------|
| 1                    | Well                   | –         | 0   | +               | 2   | +                                 |
| 2 a                  | Poorly                 | +++       | 3   | +               | 1   | +                                 |
| 2 b                  | Poorly                 | ++        | 2   | ++              | 2   | +                                 |
| 3                    | Moderately             | ++        | 3   | +               | 1   | +                                 |
| 4                    | Poorly                 | –         | 0   | ++              | 2   | +                                 |
| 5 i                  | Well                   | –         | 0   | +               | 1   | –                                 |
| 5 ii                 | Well                   | –         | 0   | +               | 1   | +                                 |
| 5 iii a              | Well                   | ++        | 2   | –               | 0   | –                                 |
| 5 iii b              | Well                   | –         | 0   | –               | 0   | –                                 |
| 6                    | Moderately             | +++       | 3   | ++ <sup>‡</sup> | 1   | +                                 |
| 7a                   | Moderately             | –         | 0   | +or++           | 2   | –                                 |
| 7b                   | Moderately             | +or+++    | 1   | –               | 0   | –                                 |
| 8                    | Well                   | –         | 0   | +               | 2   | –                                 |
| 9                    | Moderately             | +++       | 2   | +               | 1   | +                                 |
| 10                   | Moderately             | ++        | 2   | +               | 1   | –                                 |
| 11                   | Well                   | –         | 0   | +               | 2   | +                                 |
| 12                   | Moderately             | –         | 0   | ++              | 3   | +                                 |
| 13                   | Moderately             | –         | 0   | +               | 2   | +                                 |
| 14 i                 | Moderately             | +++       | 3   | ++ <sup>‡</sup> | 2   | –                                 |
| 14 ii                | Moderately             | +++       | 2   | ++ <sup>‡</sup> | 3   | –                                 |
| 15                   | Moderately             | +         | 1   | +               | 1   | +                                 |
| 16                   | Well                   | –         | 0   | ++              | 1   | +                                 |
| 17                   | Well                   | –         | 0   | –               | 0   | –                                 |
| 18                   | Well                   | –         | 0   | +++             | 3   | +                                 |
| 19                   | Well                   | –         | 0   | + <sup>‡</sup>  | 1   | –                                 |
| 20                   | Moderately             | +++       | 3   | +               | 1   | +                                 |
| 21 a                 | Poorly                 | +         | Single cells                                  | –               | 0   | +                                 |
| 21 b                 | Poorly                 | +         | 2   | –               | 0   | –                                 |

<sup>s</sup> The designations a and b indicate same operation, different samples. The designations i, ii, etc., indicate different operations.

<sup>#</sup> Basal expression. #: 0=no stain, 1=1–25%, 2=26–50%, 3=>50% of the cells are stained positively.

## DISCUSSION

The present study is the first systematic approach examining the expression of p53, p21, Ki-67 and bcl-2 proteins in chronic leg ulcers with and without SCC.

The overall positivity of p21 and p53 as detected by immunohistochemistry in SCCs in chronic venous ulcers seems to be similar to that previously reported in samples of skin SCC. The results differ, however, with regard to perilesional expression. Perilesional p53 positivity seems to be the rule in SCCs where UV light is implicated as the cause (12, 15, 40, 41) and we found no perilesional p53 in the epidermis adjacent to the SCCs nor in the chronic non-cancerous venous ulcers. This might reflect a mechanism of carcinogenesis in venous ulcers different from that in UV-induced SCC.

In acute wounds, p53 is reported to be downregulated during the proliferative phase and upregulated when the remodelling phase starts (20–22). The absence of p53 expression in the non-cancer ulcers raises the question of whether this reflects downregulation that, along with upregulation of epidermal growth factor and platelet-derived growth factor (19), might increase the vulnerability of epidermal tissue in chronic ulcers to malignant transformation.

Of the cancer samples in our material, p21 was expressed in

79%, mostly at the suprabasal layer whenever a distinct basal layer could be discerned in the cell nests, and in basal and suprabasal positions in 4 samples where the cells of the basal layer were morphologically similar to the suprabasal cells. In studies on normal epidermis (42), UV-radiated skin (43), psoriatic epithelium (44) and in 1 study of UV-induced SCC (30), p21 expression, when present, was mainly suprabasal and taken to reflect the entrance into the G0 phase and differentiation instead of S-phase and continuation of the cell cycle. However, in another study of SCC (mainly UV-induced), p21 was expressed in both the suprabasal and basal layers, which was interpreted as indicative of the anti-proliferative role of p21 in these tumours (28). In SCC of the oral cavity and of the cervix uteri, suprabasal staining indicating a differentiation pattern is reported (34, 35). The interpretation of basal or suprabasal expression of p21 in SCC merits further study, since according to our results, this is not an “all or none” reaction, but is dependent upon the morphology of the tumour and differentiation of the tumour nests. Interestingly, in the 4 samples with basal p21 expression, only 1 was Ki-67-positive, which means that of 15 samples with positive p21 and Ki-67, in only 1 were these 2 proteins co-expressed in the same cell groups.

In our study, strongly expressed p53 was found mainly in moderately- and poorly-differentiated lesions, which is in

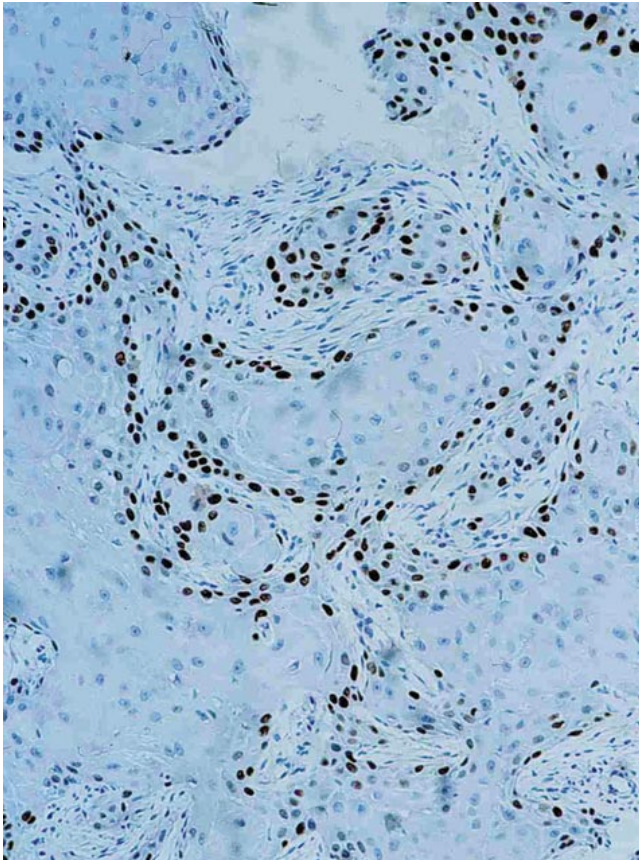


Fig. 1. p53-positive cells at the border of tumour nests in moderately differentiated squamous cell carcinoma. (Original magnification  $\times 100$ , photo M-A Hedblad).

accordance with other reports on p53 in SCC (14). Co-expression of p53 and p21 was seen in only 2 cases in our material. This confirms reports from other studies (28, 29) and probably indicates the defective action of a mutated p53 and p21 induction by a p53-independent pathway. Co-localization is the rule when the physiological p53/p21 response to UV radiation is studied (26, 43).

SCCs in leg ulcers are often misdiagnosed for long periods of time. In such cases the main differential diagnostic problem is the distinction between well-differentiated SCC and pseudoepitheliomatous hyperplasia (2). The striking difference between non-malignant and malignant tissues with respect to p53 and p21 positivity might be useful as a marker for early detection of SCC, but more studies are required to test the usefulness of p21 expression in this differential diagnosis.

The absence of expression of the bcl-2 protein in our material is in agreement with other studies of bcl-2 in cutaneous SCC (37, 38).

The results of the study probably underline the different mechanisms of carcinogenesis in venous ulcers and UV-induced SCC, but do not give an indication of which factors in venous leg ulcers are active in the malignant transformation.

#### ACKNOWLEDGEMENTS

The skilful technical assistance of Ms. Sari Mäki and Ms. Sarita Järvinen is greatly appreciated, as is Mrs. Carol Scinto's review of the

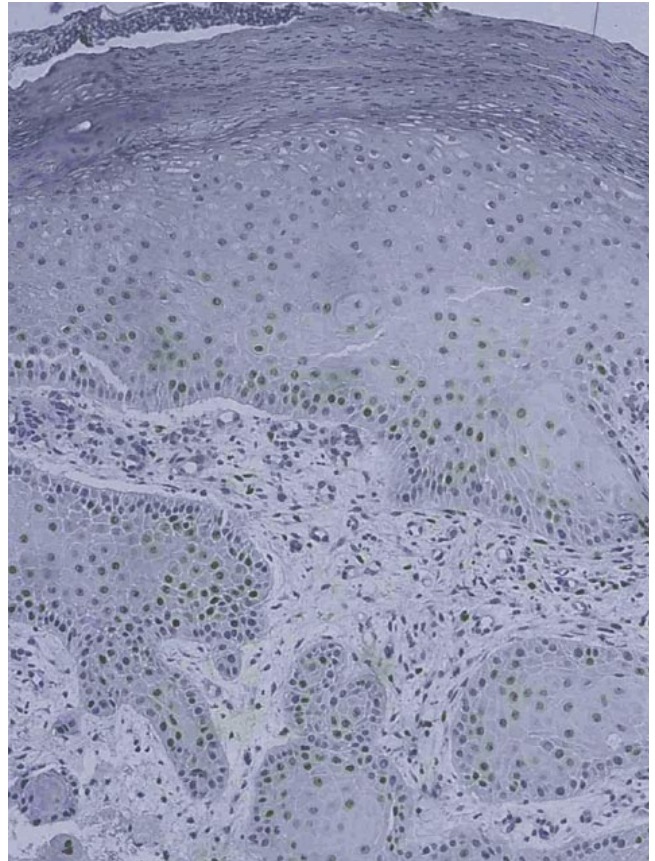


Fig. 2. Expression of the p21 protein in well differentiated squamous cell carcinoma in a venous ulcer. The well defined basal layer is negative. (Original magnification  $\times 100$ , photo M-A Hedblad).

English language. The Forum for Research and Development, Gävle Hospital, and the Welander-Finsen Foundation, Stockholm, financially supported this study.

#### REFERENCES

1. Yakubu A, Mabogunje OA. Skin cancer in Zaria, Nigeria. *Trop Doct* 1995; 25 Suppl: 63–67.
2. Marks R. Squamous cell carcinoma. *Lancet* 1996; 347: 735–738.
3. Baldursson B, Sigurgeirsson B, Lindelöf B. Venous leg ulcers and squamous cell carcinoma: a large-scale epidemiological study. *Br J Dermatol* 1995; 133: 571–574.
4. Baldursson B, Hedblad M-A, Beitner H, Lindelöf B. Squamous cell carcinoma complicating chronic venous leg ulceration: a study of the histopathology, course and survival in 25 patients. *Br J Dermatol* 1999; 140: 1148–1152.
5. Adair HM. Epidermal repair in chronic venous ulcers. *Br J Surg* 1977; 64: 800–804.
6. Nwomeh BC, Yager DR, Cohen IK. Physiology of the chronic wound. *Clin Plast Surg* 1998; 25: 341–356.
7. Kastan MB, Onyekwere O, Sidransky D, Vogelstein B, Craig RW. Participation of p53 in the cellular response to DNA damage. *Cancer Res* 1991; 51: 6304–6311.
8. Levine AJ. p53, the cellular gatekeeper for growth and division. *Cell* 1997; 188: 323–331.
9. Hockenbery DM. bcl-2, a novel regulator of cell death. *Bioessays* 1995; 17: 631–638.
10. Miyashita T, Krajewski S, Krajewska M, Wang HG, Lin HK, Lieberman DA, et al. Tumor suppressor p53 is a regulator of bcl-

- 2 and bax gene expression in vitro and in vivo. *Oncogene* 1994; 9: 1799–1805.
11. Eliyahu D, Oren M, Levine AJ. Activating mutations for transformation by p53 produce a gene product that forms an hsc70-p53 complex with an altered half-life. *Mol Cell Biol* 1988; 8: 531–539.
  12. Kubo Y, Urano Y, Yoshimoto K, Iwahana H, Fukuhara K, Arase S, et al. p53 gene mutation in human skin cancers and precancerous lesions: comparison with immunohistochemical analysis. *J Invest Dermatol* 1994; 102: 440–444.
  13. Campbell C, Quinn AG, Angus B, Rees JL. The relation between p53 mutations and p53 immunostaining in non-melanoma skin cancer. *Br J Dermatol* 1993; 129: 235–241.
  14. Lane DP. On the expression of p53 protein in human cancer. *Mol Biol Rep* 1994; 19: 23–29.
  15. Gibson GE, O'Grady A, Kay EW, Leader M, Murphy GM. p53 tumor suppressor gene protein expression in premalignant and malignant skin lesions of kidney transplant recipients. *J Am Acad Dermatol* 1997; 36: 924–31.
  16. Brash DE, Rudolph JA, Simon JA, Lin A, McKenna GJ, Baden HP, et al. A role for sunlight in skin cancer: UV-induced p53 mutations in squamous cell carcinoma. *Proc Natl Acad Sci USA* 1991; 88: 10124–10128.
  17. Sakatani S, Kusakabe H, Kiyokane K, Suzuki K. p53 gene mutations in squamous cell carcinoma occurring in scars. *Am J Dermatopathol* 1998; 20: 463–467.
  18. Alexander JW, Shucart WA, Altemeier WA. Enhancement of tumour growth by growth-promoting factor from injured tissues. *Surg Forum* 1965; 16: 111–113.
  19. Abramovitch R, Marikovsky M, Meir G, Neeman M. Stimulation of tumour growth by wound-derived growth factors. *Br J Cancer* 1999; 79: 1392–1398.
  20. Nagata M, Takenaka H, Shibagaki T, Kishimoto S. Apoptosis and p53 protein expression increase in the process of burn wound healing in guinea-pig skin. *Br J Dermatol* 1999; 140: 829–838.
  21. Antoniadou HN, Galanopoulos T, Neville-Golden J, Kiritsy CP, Lynch SE. p53 expression during normal tissue regeneration in response to acute cutaneous injury in swine. *J Clin Invest* 1994; 93: 2206–2214.
  22. Hausmann R, Nerlich A, Betz P. The time-related expression of p53 protein in human skin wounds – a quantitative immunohistochemical analysis. *Int J Legal Med* 1998; 111: 169–172.
  23. Slebos RJC, Lee MH, Plunkett BS, Kessis TD, Williams BO, Jacks T, et al. p53 dependent G1 arrest involves pRB-related proteins and is disrupted by the human papillomavirus 16 E7 oncoprotein. *Proc Natl Acad Sci USA* 1994; 91: 5320–5324.
  24. Xiong Y, Hannon GJ, Zhang H, Casso D, Kobayashi R, Beach D. p21 is a universal inhibitor of cyclin kinases. *Nature* 1993; 366: 701.
  25. El-Deiry WS. p21/p53, cellular growth control and genomic integrity. *Curr Top Microbiol Immunol* 1998; 227: 121–137.
  26. El-Deiry WS, Harper JW, O'Connor PM, Velculescu VE, Canman CE, Jackman J, et al. WAF1/CIP1 is induced in p53-mediated G<sub>1</sub> arrest and apoptosis. *Cancer Res* 1994; 54: 1169–1174.
  27. El-Deiry W, Tokino T, Waldman T, Oliner JD, Velculescu VE, Burrell M, et al. Topological control of p21<sup>WAF1/CIP1</sup> expression in normal and neoplastic tissue. *Cancer Res* 1995; 55: 2910–2919.
  28. Ahmed NU, Ueda M, Ichihashi M. p21<sup>waf/cip1</sup> expression in non-melanoma skin tumors. *J Cutan Pathol* 1997; 24: 223–227.
  29. Inohara S, Kitigawa K, Kitano Y. Co-expression of p21<sup>WAF1/CIP1</sup> and p53 in sun-exposed normal epidermis, but not in neoplastic epidermis. *Br J Dermatol* 1996; 135: 717–720.
  30. Lu S, Tiekso J, Hietainen S, Syrjänen K, Havu VK, Syrjänen S. Expression of cell-cycle proteins p53, p21 (WAF-1), PCNA and Ki-67 in benign, premalignant and malignant skin lesions with implicated HPV involvement. *Acta Derm Venereol* 1999; 79: 268–273.
  31. Shiohara M, El-Deiry WS, Wada M, Nakamaki T, Takeuchi S, Yang R, et al. Absence of WAF1 mutations in a variety of human malignancies. *Blood* 1994; 84: 3781–3784.
  32. Alpan TS, Pardee AB. p21<sup>WAF1/CIP1/SDI1</sup> is elevated through a p53-independent pathway by mimosine. *Cell Growth Differ* 1996; 7: 893–901.
  33. Datto MB, Li Y, Panus JF, Howe DJ, Xiong Y, Wang XF. Transforming growth factor beta induces the cyclin-dependent kinase inhibitor p21 through a p53-independent mechanism. *Proc Natl Acad Sci USA* 1995; 92: 5545–5549.
  34. Werness BA, Wang H-Q, Chance J, Goldstein DJ. p53-independent expression of p21<sup>WAF1/CIP1</sup> in preinvasive and invasive squamous neoplasms of the uterine cervix. *Mod Pathol* 1997; 10: 578–584.
  35. Ng IOL, Lam KY, Ng M, Regezi JA. Expression of p21/waf1 in oral squamous cell carcinomas – correlation with p53 and mdm2 and cellular proliferation index. *Oral Oncol* 1999; 35: 63–69.
  36. Nakagawa K, Yamamura K, Maeda S, Ichihashi M. bcl-2 expression in epidermal keratinocytic diseases. *Cancer* 1994; 74: 1720–1724.
  37. Morales-Ducret CRJ, van de Rijn M, LeBrun DP, Smoller BR. bcl-2 expression in primary malignancies of the skin. *Arch Dermatol* 1995; 131: 909–912.
  38. Wikonkal NM, Berg RJ, van Haselen CW, Horkay I, Remenyik E, Begany A, et al. bcl-2 vs p53 protein expression and apoptotic rate in human non-melanoma skin cancers. *Arch Dermatol* 1997; 133: 599–602.
  39. Brown DC, Gatter KC. Monoclonal antibody Ki67: its use in histopathology. *Histopathology* 1990; 17: 489.
  40. McGregor JM, Yu CC-W, Dublin EA, Levison DA, MacDonald DM. Aberrant expression of p53 tumour-suppressor protein in non-melanoma skin cancer. *Br J Dermatol* 1992; 127: 463–469.
  41. Kerschmann RL, McCalmont TH, LeBoit PE. p53 oncoprotein expression and proliferation index in keratoacanthoma and squamous cell carcinoma. *Arch Dermatol* 1994; 130: 181–186.
  42. Mateo MS, Saez AI, Sanches-Beato M, Garcia P, Sanchez-Verde L, Martinez JC. Expression of p21<sup>WAF1/CIP1</sup> in fetal and adult tissues: simultaneous analysis with Ki67 and p53. *J Clin Pathol* 1997; 50: 645–653.
  43. O'Grady A, Kay E, McKenna DB, Bennett MA, Murphy GM, Leader MB. Altered expression of the p53-regulated proteins, p21<sup>WAF1/CIP1</sup>, mdm2, and bax in ultraviolet-irradiated human skin. *Hum Pathol* 1998; 29: 559–564.
  44. Healy E, Reynolds N, Smith MD, Harrison D, Doherty E, Campbell C, Rees JL. Upregulation of p21<sup>WAF1/CIP1</sup> in psoriasis and after the application of irritants and tape stripping. *J Invest Dermatol* 1995; 105: 274–279.