

## CLINICAL REPORT

# Lupus Erythematosus Panniculitis in a Patient with Autoimmune Hepatitis

KEI FUJIWARA<sup>1</sup>, TAKESHI KONO<sup>1</sup>, MASAMITSU ISHII<sup>1</sup>, SHOJI TANIGUCHI<sup>2</sup> and SHINOBU SAITO<sup>3</sup>

<sup>1</sup>Department of Dermatology, Osaka City University Medical School, <sup>2</sup>Department of Dermatology, Osaka General Hospital of the West Japan Railway Company and <sup>3</sup>Department of Internal Medicine, Sumiyoshi Municipal Hospital, Osaka, Japan

**Lupus erythematosus panniculitis (profundus), a rare variant of chronic panniculitis, sometimes develops during the course of discoid lupus erythematosus or systemic lupus erythematosus. A 61-year-old woman had suffered from autoimmune hepatitis type I for 5 years. Prednisolone had been administered as maintenance therapy and her hepatitis had been well controlled. However, asymptomatic erythematous indurated nodules developed symmetrically in both pre-auricular regions, and skin biopsy revealed lupus erythematosus panniculitis (profundus). Increase in dosage of prednisolone resolved the skin lesion, leaving depressed atrophic scars. This is the first report of lupus erythematosus panniculitis complicating autoimmune hepatitis. Key words: autoimmunity; discoid lupus erythematosus; lupoid hepatitis; lupus erythematosus profundus; systemic lupus erythematosus.**

(Accepted August 23, 2000.)

Acta Derm Venereol 2000; 80: 373–375.

Kei Fujiwara, MD, Department of Dermatology, Osaka City University Medical School, 1-4-3, Asahimachi, Abenoku, Osaka, 545-8585, Japan.

Lupus erythematosus panniculitis (profundus) (LEP) may develop in association with discoid lupus erythematosus (DLE) or systemic lupus erythematosus (SLE) (1). Izumi & Takiguchi reported that 12 patients with LEP had SLE and 22 had DLE (2). LEP is characteristically a chronic condition associated with remissions and relapses. Spontaneous resolution may occur and leave depressed atrophic disfiguring scars (lipoatrophy) (3).

Autoimmune hepatitis (AIH) is an idiopathic disorder affecting the hepatic parenchyma, in which immune reactions against host antigens are found to be the major pathological mechanism. If left untreated, it has an unfavourable prognosis, and it should therefore be diagnosed as soon as possible (4, 5). The distinctive pathognomonic findings of AIH include: hypergammaglobulinaemia, various circulating autoantibodies, multisystem disease expression, histological chronic active hepatitis with large areas of periportal necrosis and plasmacytosis, and responsiveness to immunosuppressive therapy (4, 5). Although AIH is often associated with clinical and laboratory features that resemble those of SLE (6), AIH is distinctly different from liver dysfunction found in a patient with SLE (7, 8).

In the present paper, the development of LEP in a patient with well-controlled AIH is reported.

## CASE REPORT

A 61-year-old woman had had intermittent slight fever and general fatigue since 1985. Her regular physician had diagnosed liver

dysfunction. In December 1991, her liver function deteriorated acutely. At that time, levels of aspartate aminotransferase, alanine aminotransferase,  $\psi$ -glutamyl transferase, alkaline phosphatase and lactate dehydrogenase were 754 U/l (normal range 0–35), 818 U/l (0–35), 82 U/l (0–60), 228 U/l (80–230) and 480 U/l (250–500), respectively. No serological changes for hepatitis B virus surface antigen and hepatitis C virus antibody were found. On laboratory testing, many lupus erythematosus cells and elevation of immunoglobulin G (IgG, 2.28 g/dl; normal range 0.70–1.70) were found. The lupus erythematosus cell factor and antinuclear antibody were positive (homogeneous and speckled pattern,  $\times 80$ ). Rheumatoid factors, antimitochondrial antibodies, anti-smooth-muscle antibody, antibodies to liver–kidney microsomes and anti-U1 ribonucleoprotein antibodies were not detected. Liver biopsy revealed extensive lobular infiltration with lymphocytes and plasma cells and shortening of the distance between portal veins (P–P bridging) as a result of

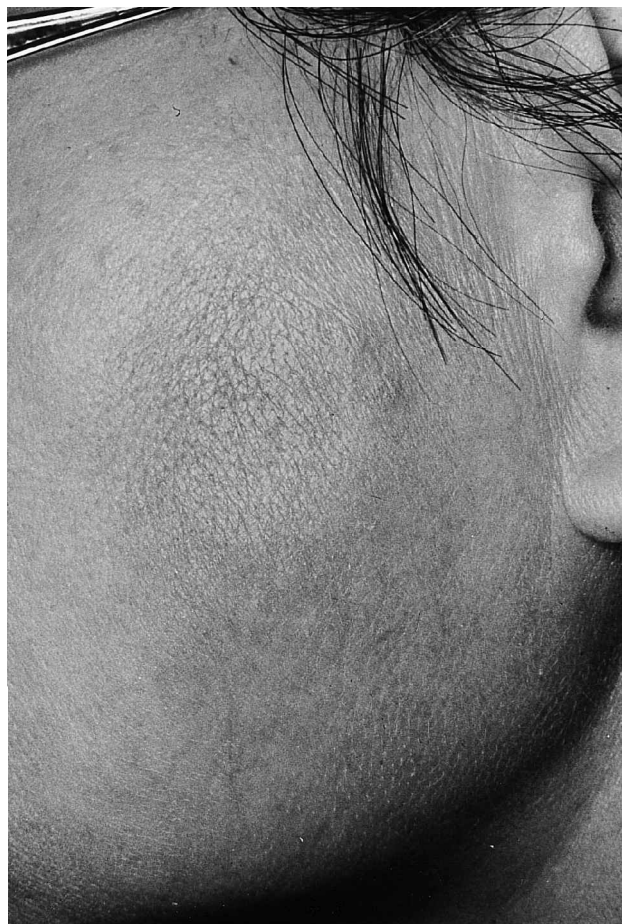

Fig. 1. Clinical picture at initial examination, showing a slightly erythematous nodule in the left pre-auricular region.

multilobular necrosis and perifollicular fibrosis. The patient did not have arthritis. Drug-induced lupus or liver dysfunction could be ruled out because she had not taken any drugs before. The diagnosis of SLE or rheumatoid arthritis could not be made using the criteria of the American College of Rheumatology (ACR). On the basis of the clinicopathological findings, her liver dysfunction was diagnosed as AIH type I. Administration of prednisolone (initial dose 40 mg daily) and bucillamine (200 mg daily) achieved resolution. Her general condition had been good for 4 years and prednisolone could be tapered to 5 mg daily. Although liver dysfunction had sometimes recurred, her general condition and liver function had been well controlled and no remarkable elevation of erythrocyte sedimentation rate and C-reactive protein had been found until September 1996.

In October 1996, she noticed asymptomatic nodules on the cheeks without a history of trauma, and was referred to the authors' clinic. On initial examination, slightly erythematous indurated nodules were found in both pre-auricular regions (left 2 × 4 cm, right 1 × 4 cm) (Fig. 1). Laboratory examination revealed moderate pancytopenia (red blood cells  $3.7 \times 10^{12}/l$ , normal range 3.9–4.7; white blood cells  $2.8 \times 10^9/l$ , normal range 4.3–8.0; platelets  $172 \times 10^9/l$ , normal range 180–340), slight decrease in serum C3 (0.8 g/l, normal range 0.9–1.6) and C4 (0.14 g/l, normal range 0.17–0.45) and slight elevation of IgG (1.77 g/l) and IgA (4.38 g/l, normal range 1.10–4.10). Antinuclear antibody was positive (homogeneous and speckled pattern, ×80). Anti-double-stranded DNA-IgG antibody was elevated (24.0 IU/ml, normal range 0–12.0). Values of aspartate aminotransferase (40 U/l), alanine aminotransferase (32 U/l) and circulating immune complex (C1q binding assay 10.7 µg/ml, normal range 0–10) were each near the upper limit of the normal range. Skin biopsy revealed epidermal atrophy, mucin deposition and perivascular inflammatory cell infiltration in the dermis, and deep lymphocytic infiltration in the fatty tissue. Dense lymphocytic infiltration with plasma cells was found in the fat lobules and septa (Fig. 2A, B). The fat lobules lost

nuclear staining of the fat cells and an accumulation of proteins in a homogeneous eosinophilic matrix between residual adipocytes was found (Fig. 2A). No vasculitis, epithelioid cells or giant cells were found. LEP was diagnosed.

The dosage of prednisolone was increased to 40 mg daily again. Two weeks later, progression of the erythema discontinued. For 2 months, prednisolone was gradually tapered to 10 mg daily. Although remission of LEP had continued for 3 years, atrophic lesions with central depression persisted. In September 1999, new erythematous nodules reappeared in both pre-auricular regions, close to the previous lesions, without any deterioration in liver function. Increase in dosage of prednisolone to 30 mg daily achieved resolution within 2 weeks. Although liver biopsy has not been performed again, her liver function, C-reactive protein and erythrocyte sedimentation rate have been within normal ranges.

## DISCUSSION

AIH is a chronic necroinflammatory disease of the liver, and its early recognition is important in preventing the development of liver cirrhosis. The current treatment for AIH has been reported to have a failure rate of about 13% and to be unable to induce permanent remission in most patients (7). Most patients with AIH enter remission, but relapse occurs in 50–86% of cases after drug withdrawal, and maintenance therapy with prednisolone or azathioprine is required for a long period (5). The present patient had relatively mild AIH, with low-dosage prednisolone effective for disease control. The clinicopathological and biochemical features of progressive necroinflammatory liver disease distinguish AIH from

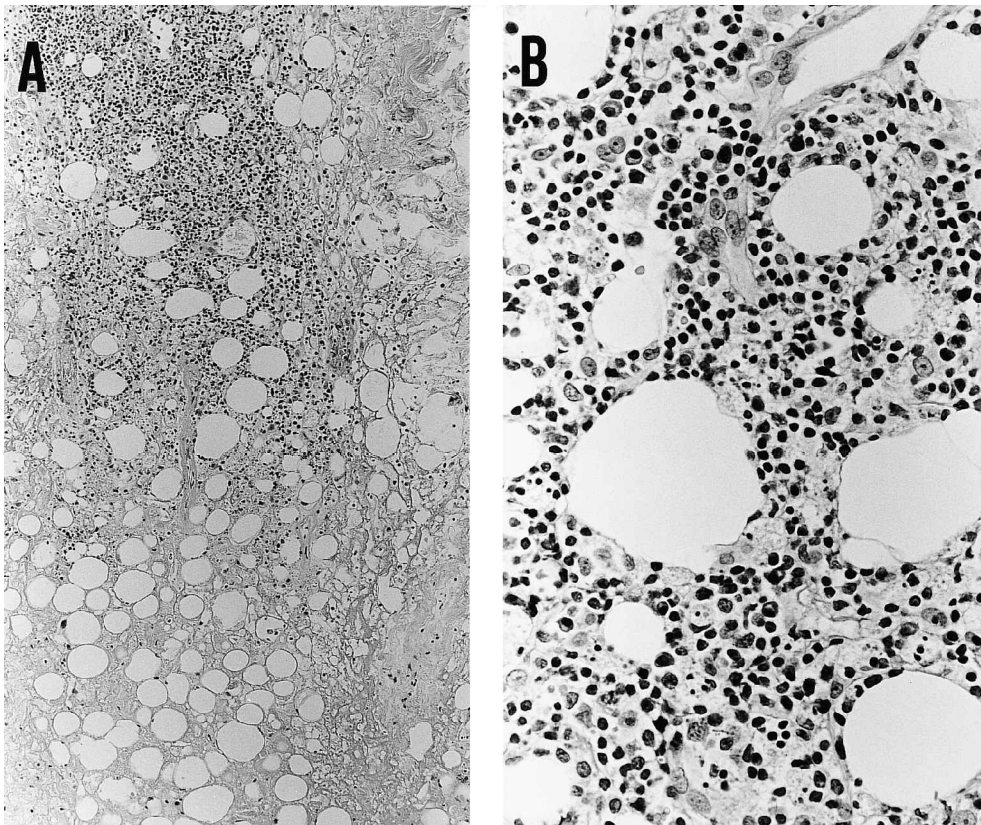


Fig. 2. Histopathological picture of the skin lesion (adipose tissue) in the left pre-auricular region (hematoxylin and eosin; original magnification: A × 100, B × 400).

SLE or rheumatoid arthritis, which are not associated with severe liver disease (8).

Although an association of LEP with trauma has been suggested (3), the LEP lesions in the present case developed symmetrically and spontaneously on the face. Despite early treatment, facial disfigurement occurred. The disease in this case was chronic and relapsed 3 years later, as in those patients reported previously (1–3).

The incidence of LEP in SLE has been reported to range from 2 to 5% (3). However, Watanabe & Tsuchida observed the course of 16 cases of LEP for a decade and reported the prognosis of LEP (9). Only 2 of their patients (12%) initially met the ACR criteria for SLE, and SLE developed in another 2 (12%) patients. The remaining 12 (75%) patients never met the criteria for SLE, and 4 of the 16 (25%) had no extracutaneous manifestations. Martens et al. observed 40 patients with LEP for 17 years (the average duration of LEP lesion was 6 years, range 0–38) (10). Only 4 of their 40 patients (10%) met the criteria for SLE, and except for antinuclear antibody, a paucity of autoantibodies was observed. These studies demonstrated that LEP can develop during the course of SLE, although most patients in the studies did not develop SLE, and revealed that most patients with LEP had a relatively mild disease course. Even in the patients with associated SLE, a relatively low incidence of renal and neurological involvement has been reported (3). In the present study, the course of AIH has been mild and LEP developed in the presence of stable AIH. Certainly, new manifestations can develop even under prednisolone therapy when the dose is low. However, no complications of AIH and LEP have been reported.

There are some similarities and differences between the histopathological findings of LEP and those of AIH. Lymphocytic infiltration is usually found in the lesions of both AIH and LEP. Plasma cellular infiltration is prominent in AIH. In the lesion of LEP, plasma cells are often, but not always, found. A loss of tolerance to autologous liver tissue is considered the principal pathogenetic mechanism in AIH (4–7). Increased vascular permeability and leakage of

circulating antinuclear antibodies into the fat lobules have been assumed to be involved in the pathogenesis of LEP (1). The present findings suggest that some factors are common to the pathogenesis of both AIH and LEP. These problems warrant further investigation.

#### ACKNOWLEDGEMENT

The authors thank Dr Michael Connolly (Translation Co. Ltd, Osaka, Japan) for critical reading of the manuscript.

#### REFERENCES

1. McNutt MS, Moreno A, Contreas F. Inflammatory diseases of the subcutaneous fat – lupus erythematosus panniculitis. In: Elder D, Elenitsas R, Jaworsky C, Johnson B Jr, eds. *Lever's histopathology of the skin*. 8th edn. Philadelphia, PA: Lippincott-Raven, 1997: 440–441.
2. Izumi AK, Takiguchi P. Lupus erythematosus panniculitis. *Arch Dermatol* 1983; 119: 61–64.
3. McKee PH. *Pathology of the skin*. 2nd edn. London: Mosby-Wolfe, 1996: 10.20–10.21.
4. McFarlane IG. Pathogenesis of autoimmune hepatitis. *Biomed Pharmacother* 1999; 53: 255–263.
5. Czaja AJ. Drug therapy in the management of type 1 autoimmune hepatitis. *Drugs* 1999; 57: 49–68.
6. Lin RY, Green LJ, Winny D, Ramaswamy G. Immunological abnormalities in autoimmune chronic active hepatitis. *J Rheumatol* 1989; 16: 1489–1493.
7. van den Berg AP. Autoimmune hepatitis: pathogenesis, diagnosis and treatment. *Scand J Gastroenterol* 1998; Suppl. 225: 66–69.
8. Dienstag JL, Isselbacher KJ. Chronic hepatitis. In: Fauci AS, Braunwald E, Isselbacher KJ, Wilson JD, Martin JB, Kasper DL, et al., eds. *Harrison's principles of internal medicine*. 14th edn. New York: McGraw-Hill, 1998: 1696–1704.
9. Watanabe T, Tsuchida T. Lupus erythematosus profundus: a cutaneous marker for a distinct clinical subset? *Br J Dermatol* 1996; 134: 123–125.
10. Martens PB, Moder KG, Ahmed I. Lupus panniculitis: clinical perspectives from a case series. *J Rheumatol* 1999; 26: 68–72.