

INVESTIGATIVE REPORT

Effect of EMLA Cream on Skin Thickness and Subcutaneous Venous Diameter. A Randomized, Placebo-controlled Study in Children

HENRIK EGEKVIST and PETER BJERRING

Department of Dermatology, Marselisborg Hospital, Aarhus University Hospital, Aarhus, Denmark

EMLA cream, which is used to provide analgesia prior to venepuncture, induces a skin-blanching reaction. This reaction may be caused by both skin hydration and vasoconstriction. Twenty healthy children with veins suitable for venepuncture on the dorsa of the hands or at the antecubital fossae had applied either EMLA cream or placebo cream under occlusion for 60–70 min in a randomized, double-blind, cross-over study. An ultrasound examination of the skin was conducted. The mean percentage change in vein diameter after removal of EMLA cream was not significant whereas, 15 min after EMLA cream removal, the decrease in the initial vein diameter (13.5%) was significant ($p < 0.01$). The mean percent increase in skin thickness after the removal of EMLA cream was also significant (19.3%; $p = 0.01$). The changes in vein diameter and skin thickness due to the application of EMLA cream do not seem to be of clinical importance to vein cannulation. Key words: ultrasound; analgesia; vein; clinical trial.

(Accepted August 28, 2000.)

Acta Derm Venereol 2000; 80: 340–343.

Henrik Egekvist, Department of Dermatology, Marselisborg Hospital, Aarhus University Hospital, P.P. Ørumsgade 11, DK-8000, Aarhus C, Denmark.
E-mail: he@miba.auc.dk

EMLA cream is used to provide analgesia prior to venepuncture (1–9) as well as prior to various dermatological procedures associated with pain (10). Analgesia of the skin is achieved by the release of lidocaine and prilocaine from the cream into the cutaneous and subcutaneous nociceptors and free nerve endings. The duration of application needed to provide optimal analgesia of non-diseased skin on the dorsum of the hand is at least 45–90 min (1, 4, 11, 12). During EMLA analgesia of non-diseased skin a biphasic vascular reaction is observed, depending on the length of application of EMLA cream, with an initial blanching reaction which reaches a peak after 90 min of application followed by an erythematous reaction following longer applications of EMLA cream (13). The normally recommended application time of 45–60 min is thus within the period of the vasoconstriction reaction, which can be assumed to be associated not only with vascular contractions of the superficial capillary vessels but also with subcutaneous vein contraction and with a possible increase in skin thickness (14). Although both moderate and transient, these reactions may render the cannulation procedure more difficult. Accordingly, the aim of the present study was to evaluate subcutaneous venous diameter and skin thickness before and

after application of EMLA cream. As EMLA cream is mainly used before venepuncture in children, this study was conducted in volunteers 3–11 years old. A high-frequency ultrasound B-scan was used to quantify both venous diameter and skin thickness. This non-invasive method has previously proved useful in dermatology for investigations of different structures of the skin, in both healthy subjects (15, 16) and in subjects with various skin disorders (17, 18).

MATERIAL AND METHODS

Subjects

Twenty healthy children (14 boys, 6 girls; mean age 7.7 years; range 3–11 years) participated in the study. None of the volunteers had any history of skin disease. Volunteers with known or suspected hypersensitivity to local anesthetics of the amide type were excluded. None of the volunteers received any medication. All participants were of Caucasian origin. The parents of the subjects gave written informed consent and the study was approved by the National Board of Health and the Regional Scientific Ethical Committee according to the Declaration of Helsinki.

Cream application

Either EMLA cream (Astra, Sweden), which is an oil-in-water emulsion composed of prilocaine 2.5%, lidocaine 2.5%, water and emulsifier, or EMLA placebo cream was applied under occlusion (Tegaderm; 3M, USA) to the skin directly above subcutaneous veins suitable for venepuncture. According to a random assignment, veins on the dorsa of the hands were used in half the volunteers, while veins in both antecubital fossae were used in the other half. EMLA cream and EMLA placebo cream were randomly applied on the right- and left-hand sides, respectively. The study design was double-blinded; however, true blinding was difficult due to skin blanching from EMLA cream. The site of application was selected to cover a subcutaneous vein without any valves at the test site, as ensured by clinical examination of the vein during retrograde stroking of the skin above the vessels. Each test site consisted of a circular skin area of $\approx 16 \text{ cm}^2$ which was covered, as recommended, with 2.5 g of cream. The creams were applied for 60–70 min. Ultrasonographic pictures were taken immediately before the application of cream, immediately after the removal of cream and finally after 15 min of air exposure after the removal of cream.

Monitoring of skin thickness and subcutaneous diameter

The treated areas were marked with a marker pen to ensure exact reapplication of the ultrasound measurement device. EMLA cream and EMLA placebo cream were used as the ultrasound-transmitting media between the skin and the high-frequency 20-MHz ultrasound probe (Dermascan; Cortex Technology, Denmark). A cream-filled space between the plastic membrane in front of the measuring head

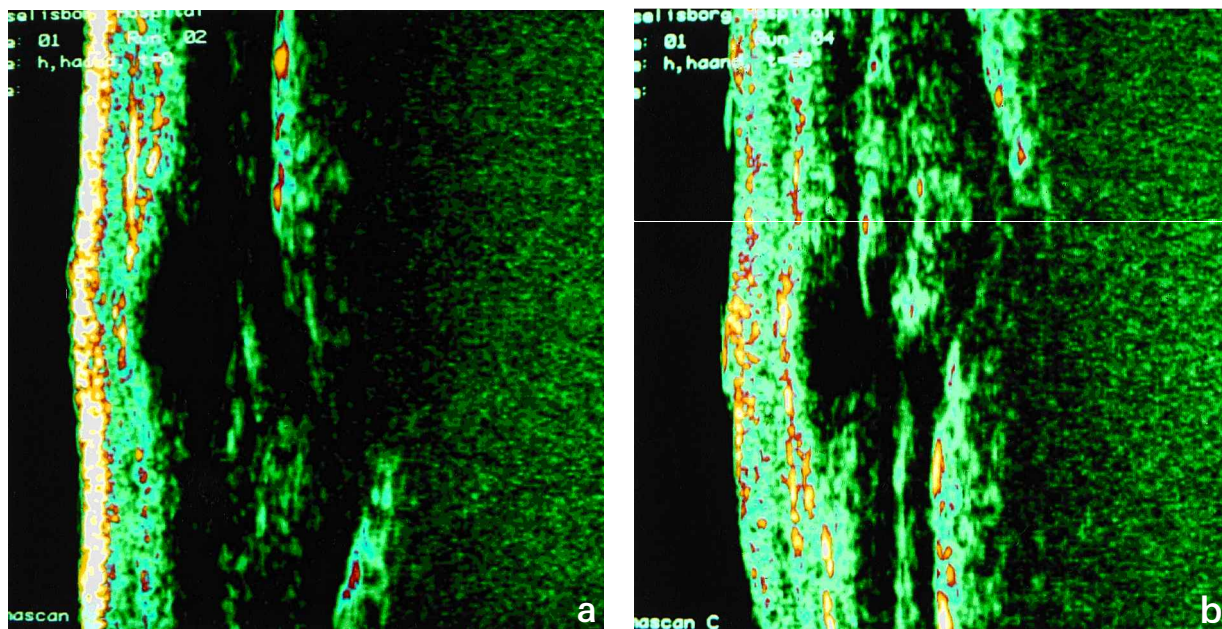


Fig. 1. 20-MHz sonographic picture of the skin and subcutaneous vein (a) prior to EMLA cream application and (b) after 60–70 min of application. The skin is superficially defined by the high-echogenic epidermal entrance echo and the dermal echo is more deeply located. Note the absent epidermal entrance echo after cream application (b).

and the skin was maintained at a constant thickness in order to avoid any compression of the skin and the subcutaneous tissues, including the veins, during measurements. The ultrasound probe was kept at 90° to the vein. The ultrasonographic gain was kept constant throughout the investigation. From the ultrasonographic pictures the skin thickness was defined as the distance from the superficial part of the entrance echo to the upper part of the subcutaneous echo (Fig. 1). Measurement of the subcutaneous vein diameter was performed by measuring the vertical distance between the interval surfaces of the subcutaneous vein (Fig. 1). All measurements were obtained as the mean of three individual A-scans (15).

Statistics

For statistical analysis, analysis of variance (ANOVA) was used to test for equivalence in percentage change between EMLA cream and EMLA placebo cream. A priori equivalence between EMLA cream and EMLA placebo cream was defined as the 90% confidence interval of the mean difference in percentage change being equal to or less to 10%. The differences in skin thickness and vein diameter at baseline, at the time of cream removal and 15 min after cream removal were compared separately for the EMLA- and placebo-treated areas. The level of statistical significance was defined as $p < 0.05$.

RESULTS

Subcutaneous vein diameter

Following the application of EMLA cream, the mean subcutaneous vein diameter decreased from 1.96 (± 0.70) (SD) mm to 1.76 (± 0.63) mm. After the cream had been removed from the skin surface for 15 min the diameter further decreased to 1.71 (± 0.76) mm. The difference between the initial vein diameter and the diameter measured 15 min after EMLA cream removal was significant ($p = 0.01$) (Table I). Significant increases were observed between the initial vein diameter and the diameters 15 min after EMLA placebo cream removal and between the vein diameter immediately after EMLA placebo cream removal and that 15 min later ($p < 0.05$) (Table I). An equivalence between the EMLA cream and the EMLA placebo cream in terms of the change in vein diameter could not be confirmed as the 90% confidence intervals were $> \pm 10\%$ (Table I).

The application site, i.e. the hand or antecubital fossa, had a significant effect on the percentage change in vein diameter from baseline to 15 min after removal of the EMLA cream and EMLA placebo cream ($p = 0.04$).

Table I. Mean percentage change in vein diameter after 60–70 min of application of EMLA cream and placebo cream

Change	Test of difference within treatment group		Test of equality between treatment groups. Mean (90% confidence interval)
	EMLA (n= 20)	Placebo (n= 19)	
From baseline to removal	- 7.6% ($p = 0.23$)	+ 4.5% ($p = 0.49$)	12.0% (- 2.4–26.5)
From baseline to 15 min after removal	- 13.5% ($p = 0.01$)*	+ 15.4% ($p = 0.01$)*	29.0% (18.1–39.8)
From removal to 15 min after removal	- 0.3% ($p = 0.97$)	+ 18.3% ($p = 0.03$)*	18.6% (0.5–36.6)

* Statistically significant change within each treatment group.

Table II. The mean percentage change in total skin thickness after 60–70 min of application of EMLA cream and placebo cream

Change	Test of difference within treatment group		Test of equality between treatment groups. Mean (90% confidence interval)
	EMLA (n= 20)	Placebo (n= 19)	
From baseline to removal	+ 19.3% (p= 0.01)	+ 5.8% (p= 0.42)	- 13.5% (- 29.3–2.2)
From baseline to 15 min after removal	+ 8.8% (p= 0.14)	+ 9.6% (p= 0.13)	0.7% (- 12.7–14.1)
From removal to 15 min after removal	- 6.7% (p= 0.18)	+ 9.9% (p= 0.06)	16.6% (5.3–27.8)

Skin thickness

During application of EMLA cream the full skin thickness increased from 1.37 (± 0.33) mm to 1.60 (± 0.42) mm. Fifteen minutes after the removal of EMLA cream the skin thickness decreased to 1.47 (± 0.37) mm. The mean percentage change between the initial skin thickness and the thickness measured immediately after cream removal was significant ($p= 0.01$) (Table II). Application of EMLA placebo cream was not related to any significant change in skin thickness. An equivalence between the effects of EMLA cream and EMLA placebo cream on the change in skin thickness could not be confirmed (Table II).

Mean baseline values of sonographic entrance echo thickness at the application sites of EMLA cream and EMLA placebo cream were 0.32 (± 0.09) mm and 0.35 (± 0.07) mm, respectively. Immediately after cream removal it was possible to identify ultrasonographic entrance echo in only 5/20 subjects in areas treated with either EMLA cream or EMLA placebo cream. After 15 min of air drying of the skin the entrance echo could be identified in 14/20 subjects treated with EMLA cream (0.30 ± 0.08) mm and in 19/20 subjects treated with EMLA placebo cream (0.31 ± 0.02) mm. Owing to the number of missing values, no statistical analysis of mean percentage was performed on the data from the thickness of the epidermal entrance echo.

DISCUSSION

EMLA cream has previously been reported to induce blanching of normal skin, as evaluated by visual examination (2, 3, 4–9, 19) and quantified by reflectance spectrophotometry (13). It has previously been demonstrated that the blanching reaction is highly related to the active substances in EMLA cream and not to the vehicle alone (20). The main reason for this blanching may be a local effect of the analgesics on the cutaneous vasoconstrictive system (19): either on the efferent nerve fibers or directly affecting the smooth muscles in the vessel walls. Another physiological effect, optical scattering, may however also affect the transparency of the skin. Owing to hydration of the stratum corneum by EMLA cream, which contains 95% water, the optical back-scattering of the outer layers of the skin may increase. This could result in a much higher proportion of the incident light being reflected from the skin, rendering the skin surface white, as previously suggested (14). This superficial cutaneous hydration may presumably also account for the present difficulty in identifying the ultrasonographic epidermal entrance echo immediately after the cream removal. The possible contribution from occlusion per se was not investigated in the present study and it is suggested to include this parameter in future studies.

Other investigators have also reported a slight, localized edema after EMLA cream application (5, 7), possibly due to increased leakage of the dermal capillaries. In the present investigation a significant increase in total skin thickness was observed only after EMLA cream application. This indicates that the cream vehicle per se does not significantly increase skin thickness but that the increase is influenced by the active analgesic substances, i.e. lidocaine and prilocaine.

In contrast to the demonstrated 14% reduction in vein diameter after EMLA cream application a previous study did not show any significant change in subcutaneous vein diameter (19). This difference may be due to the examination of adults and the measurement of vein diameter at 1-h intervals in this previous study (19). However, the demonstrated reduction in vein diameter after EMLA cream application in the present study does not seem to be of clinical significance for the successful cannulation of subcutaneous veins in the clinical situation. Several studies have shown that the application of EMLA cream facilitates the cannulation of subcutaneous veins (2, 3, 5–7), and this effect has been quantified by the use of different rating scales (2, 3, 6, 9). These studies focused not only on the mechanical and technical properties of cannulation, but also addressed a series of subjective factors, e.g. reflex movements and the behavioral status of the patients during the procedure. Besides the analgesics, the facilitating effect of EMLA cream might be due to hydration and hence mechanical softening of the skin, leading to a reduction in mechanical friction between the cannula and the tissues after “lubrication” by the oily phase of EMLA cream.

If difficulties in locating a subcutaneous vein after application of EMLA cream should arise, we suggest postponing the cannulation for 15 min to allow the outer skin layer to dry and the skin transparency to increase. This short period of time will not reduce the analgesic effect of EMLA cream (14) due to the significant reservoir of local analgesics still present in the skin. If there is not time for this 15 min drying of the skin surface to take place, then the optical transparency of the upper layers of the skin can be improved immediately by the application of a thin layer of an optical index-matching substance, e.g. peanut oil.

In conclusion, the modest increase in skin thickness and decrease in venous diameter observed after the application of EMLA cream seem to be of minor clinical importance compared with the overall benefit of pain reduction during venepuncture.

ACKNOWLEDGEMENTS

The authors thank Eva Keltly (Clinical Data Care, Lund, Sweden), for the statistical analysis and Astra Pain Control, Sweden, for supplying

the test substances and for financial support. We also thank Kurt Pfeiffer Petersen of Astra, Denmark, for his assistance.

REFERENCES

1. Ehrenstrom Reiz G, Reiz S, Stockman O. Topical anaesthesia with EMLA, a new lidocaine-prilocaine cream and the Cusum technique for detection of minimal application time. *Acta Anaesthesiol Scand* 1983; 27: 510–512.
2. Hallen B, Uppfeldt A. Does lidocaine-prilocaine cream permit painfree insertion of IV catheters in children. *Anesthesiology* 1982; 57: 340–342.
3. Lander J, Hodgins M, Nazarali S, McTavis J, Ouellette J, Friesen E. Determinants of success and failure of EMLA. *Pain* 1996; 64: 89–97.
4. Hallen B, Olsson GL, Uppfeldt A. Pain-free venepuncture. Effect of timing of application of local anaesthetic cream. *Anaesthesia* 1984; 39: 969–972.
5. Hallen B, Carlsson P, Uppfeldt A. Clinical study of a lignocaine-prilocaine cream to relieve the pain of venepuncture. *Br J Anaesth* 1985; 57: 326–328.
6. Cooper CM, Gerrish SP, Hardwick M, Kay R. EMLA cream reduces the pain of venepuncture in children. *Eur J Anaesthesiol* 1987; 4: 441–448.
7. Manner T, Kanto J, Iisalo E, Lindberg R, Viinamäki O, Scheinin M. Reduction of pain at venous cannulation in children with a eutectic mixture of lidocaine and prilocaine (EMLA cream): comparison with placebo cream and no local premedication. *Acta Anaesthesiol Scand* 1987; 31: 735–739.
8. Maunukela EL, Korpela R. Double-blind evaluation of a lignocaine-prilocaine cream (EMLA) in children. Effect on the pain associated with venous cannulation. *Br J Anaesth* 1986; 58: 1242–1245.
9. Moller C. A lignocaine-prilocaine cream reduces venipuncture pain. *Ups J Med Sci* 1985; 90: 293–298.
10. Juhlin L. EMLA lidocaine/prilocaine. Anaesthesia for superficial skin surgery. Oxford: Oxford Clinical Communications 1993.
11. Arendt-Nielsen L, Bjerring P, Nielsen J. Regional variations in analgesic efficacy of EMLA cream. Quantitatively evaluated by argon laser stimulation. *Acta Derm Venereol* 1990; 70: 314–318.
12. Arendt-Nielsen L, Bjerring P. Laser-induced pain for evaluation of local analgesia: a comparison of topical application (EMLA) and local injection (lidocaine). *Anesth Analg* 1988; 67: 115–123.
13. Bjerring P, Andersen PH, Arendt-Nielsen L. Vascular response of human skin after analgesia with EMLA cream. *Br J Anaesth* 1989; 63: 655–660.
14. Egekvist H, Bjerring P. Comparison of the analgesic effect of EMLA cream and EMLA patch on normal skin evaluated with laser-induced pain stimuli. *Acta Derm Venereol* 1997; 77: 214–216.
15. Olsen LO, Takiwaki H, Serup J. High-frequency ultrasound characterization of normal skin. Skin thickness and echographic density of 22 anatomical sites. *Skin Res Technol* 1995; 1: 74–80.
16. Gniadecka M, Quistorff B. Assessment of dermal water by high-frequency ultrasound: comparative studies with nuclear magnetic resonance. *Br J Dermatol* 1996; 135: 218–224.
17. Hoffmann K, Gerbaulet U, El-Gammal S, Altmeyer P. 20-MHz B-mode ultrasound in monitoring the course of localized scleroderma. *Acta Derm Venereol Suppl* 1991; 164: 3–16.
18. Gniadecka M. Dermal oedema in lipodermatosclerosis. Distribution, effects of posture and compressive therapy evaluated by high-frequency ultrasonography. *Acta Derm Venereol* 1995; 75: 120–124.
19. Ashley EMC, Quick DGC, El-Behesey B, Bromley LM. A comparison of the vasodilatation produced by two topical anaesthetics. *Anaesthesia* 1999; 54: 466–482.
20. Villada G, Zetlaoui J, Revuz J. Local blanching after epicutaneous application of EMLA cream. *Dermatologica* 1990; 181: 38–40.