

LETTERS TO THE EDITOR

Zosteriform and Disseminated Lesions in Cutaneous Leiomyoma

Sir,

A 40-year-old housewife presented with multiple, erythematous, skin-coloured, firm, tender, papules and nodules (5–15 mm diameter) in a zosteriform pattern confined to the left upper portion of the chest of 15 years duration (Fig. 1). A few similar lesions had appeared on her back within the previous 1.5 years. Pain was episodic and aggravated on exposure to cold. There was no family history of similar lesions. General physical and systemic examinations (including gynecological examinations) were normal. Biopsies from chest and back nodules showed a tumour composed of irregularly arranged interlacing bundles of smooth muscle fibres with varying amounts of collagen bundles in the dermis (Fig. 2). Masson's trichrome stain demonstrated the muscle fibres. These findings confirmed the clinical diagnosis of piloleiomyoma. The patient was treated with 10 mg nifedipine three times daily for 2 months with some relief of pain. The patient was then lost to follow-up.

DISCUSSION

Cutaneous leiomyomas are benign smooth muscle tumours derived from arrector pili muscle, media of blood vessels and dartos muscle of the scrotum, vulva or nipples. They are classified into 3 types according to their site of origin, namely piloleiomyoma, dartoic leiomyoma and angioleiomyoma (1, 2). Piloleiomyomas are firm, painful, intradermal nodules, most commonly seen in early adult life with equal incidences in males and females (1). They are usually multiple, and occur over the face, anterior trunk and the extensor surface of extremities (1, 2). They range in size from a few millimeters to >1 cm and the colour varies from pink to yellow or brown

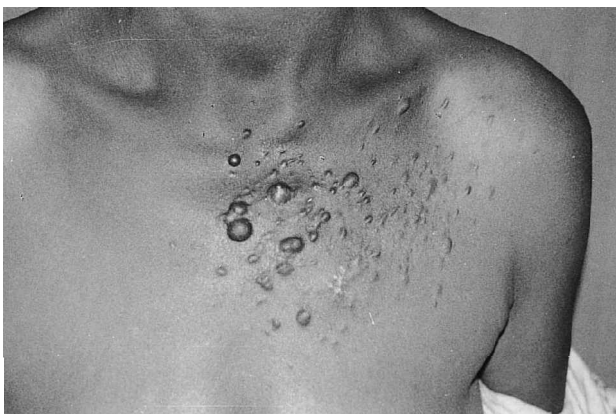

Fig. 1. Multiple, erythematous, skin-coloured papules and nodules confined to the left upper chest.

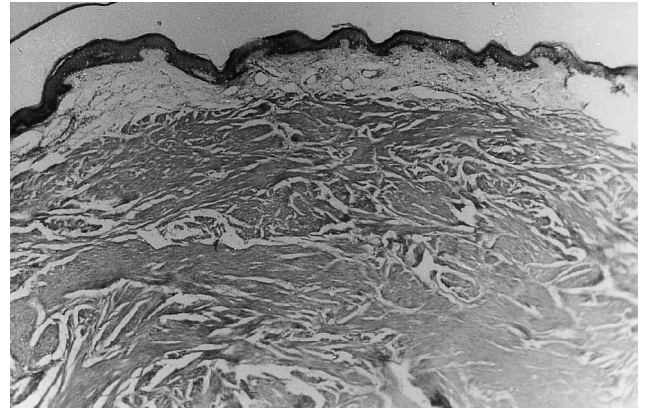


Fig. 2. Microphotograph showing a tumour composed of irregularly arranged interlacing bundles of smooth muscle fibres with varying amounts of collagen bundles in the dermis (haematoxylin and eosin staining, original magnification $\times 10$).

(3). The lesions are often sensitive to touch, cold and emotional stress. Pain usually occurs spontaneously and may be paroxysmal in nature with stabbing, burning or pinching qualities (4). The cause of pain is unknown; however, Montgomery & Winkelmann (3) postulated that it may be due to pressure on the cutaneous nerve. The zosteriform pattern, with a few discrete nodules, has been described in hereditary leiomyoma (5) and in a patient with uterine leiomyoma (6).

REFERENCES

1. Jolliffe DS. Multiple cutaneous leiomyomata. *Clin Exp Dermatol* 1978; 3: 89–92.
2. Spencer JM, Amonette RA. Tumour with smooth muscle differentiation. *Dermatol Surg* 1996; 22: 761–768.
3. Montgomery H, Winkelmann RK. Smooth muscle tumours on the skin. *Arch Dermatol* 1959; 79: 32–40.
4. George S, Pulimod S, Jacob M, Chandi SM. Pain in multiple leiomyomas alleviated by nifedipine. *Pain* 1997; 73: 101–102.
5. Berendes U, Kuhner A, Schnyder UW. Segmentary and disseminated lesions in multiple hereditary cutaneous leiomyoma. *Hum Genet* 1971; 13: 81–82.
6. Smith CG, Glaser DA, Lernardi C. Zosteriform multiple leiomyomas. *J Am Acad Dermatol* 2000; 38: 272–273.

Accepted September 27, 2000.

Arun Agarwalla¹, Amarnath Thakur², Mary Jacob¹, Arun Joshi¹, Vijay Kumar Garg¹ and Sudha Agrawal¹
Departments of ¹Dermatology and ²Pathology, B. P. Koirala Institute of Health Sciences, Dharan, Nepal. E-mail: arunaga@hotmail.com