

## In-frame Exon Skipping in *KRT5* due to Novel Intronic Deletion Causes Epidermolysis Bullosa Simplex, Generalized Severe

Katarzyna B. GOSTYŃSKA<sup>1</sup>, Jeroen BREMER<sup>1</sup>, Krista K. VAN DIJK-BOS<sup>2</sup>, Richard SINKE<sup>2</sup>, Anna Maria Gerdina PASMOOIJ<sup>1</sup> and Marcel F. JONKMAN<sup>1</sup>

Departments of <sup>1</sup>Dermatology, and <sup>2</sup>Genetics, University of Groningen, University Medical Center Groningen, Center for Blistering Diseases, AB 21, PO Box 30.001, NL-9700 RB Groningen, The Netherlands. E-mail: k.gostynska@umcg.nl

Accepted Apr 28, 2016; Epub ahead of print May 3, 2016

Basal epidermolysis bullosa simplex (EBS) is the most common type of epidermolysis bullosa (EB), comprising 31.8% of all EB patients with an identified mutation in the Dutch National EB registry (unpublished). Basal EBS is characterized by intra-basal splitting of the epidermis and mutations in *KRT5* and *KRT14* are responsible in 75% of cases (1). The clinical phenotype of the most severe variant, EBS, generalized severe (EBS-gen sev), previously reported as EBS, Dowling-Meara) consists of congenital generalized mechoanobullous skin and mucous membrane fragility, typically presenting with sero-hemorrhagic vesicles in a circinate distribution, and late-onset palmoplantar keratoderma (2). Characteristic of EBS is that most symptoms tend to diminish in severity after adolescence (3). The exact molecular mechanism for the improvement is not fully understood. More than 86% of reported mutations in *KRT5* and *KRT14* causing EBS are dominantly-acting missense mutations. The majority are located in the helical initiation and termination domains H1, 1A and 2B (4, 5). We report here a 4-generation Dutch kindred affected with EBS-gen sev caused by a novel heterozygous intronic deletion in *KRT5*. The mutation leads to in-frame skipping of exon 6 encoding 42 amino acids of the 2B helical domain.

### CASE REPORT

The female index patient (II-3, EB-092-01), now in her late 50s, was born to Caucasian parents, and had a history of generalized blistering from birth. The patient had cutis aplasia congenita of the legs and persistent oral blistering in infancy. Later in life, occasional blistering without scarring occurred all over her body, with predilection sites on the hands, inguinal folds and feet. Blistering was most severe during puberty; around the same time she developed palmoplantar keratoderma. The severity and extent of affected integument all subsided during early adulthood. The family history was positive for blistering (Fig. 1a). All affected family members had similar symptoms to those of the index patient and observed gradual improvement in both severity and extent with age (Fig. 1b–g). After obtaining informed consent, skin biopsies of fresh blisters from the index patient (II-3) and her eldest daughter (III-3) were obtained for immunofluorescence antigen mapping (IF) and transmission electron microscopy (TEM). IF using BL18 antibody (gift from Dr P. Ogden, Dundee, UK) directed against keratin 5 of lesional skin showed intraepidermal cleavage with similar expression (3+) as in control (3+). Staining was positive in the blister roof and floor. Staining performed with antibodies directed against keratin 14, BP230 (dystonin), laminin 332, and type VII collagen were normal. TEM of lesional skin showed intraepidermal cleavage, lateral aggregation of keratin filaments and

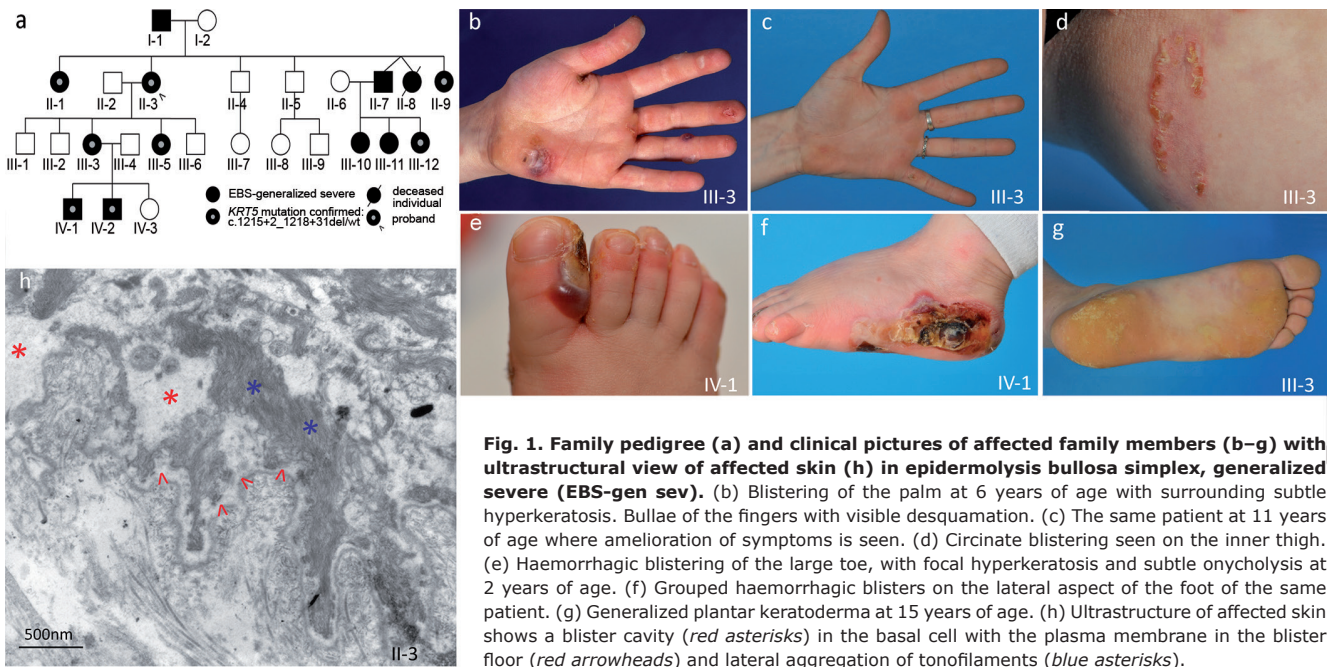
insufficient tonofilament insertion into the hemidesmosomes (Fig. 1h). Tonofilament clumping and acantholysis (as earlier reported in (6)) were also observed. Genomic DNA was extracted from peripheral blood lymphocytes from several affected individuals (Fig. 1). PCR amplification of *KRT5* (GenBank NM\_000424.3) revealed a 30-bp heterozygous intronic deletion in intron 6, (c.1218+2\_1218+31del). Subsequent mRNA analysis from frozen skin biopsies (from patients II-1, II-3, III-3, III-5, IV-1 and IV-2) showed that, besides the wild-type transcript, a shortened transcript lacking the 126-bp exon 6 (Fig. S1<sup>1</sup>). The intronic deletion occurring in intron 6 affects the highly conserved consensus donor splice site at position c.1218+2, leading to aberrant splicing. Consequently, the transcript resulted in an internally truncated keratin 5 polypeptide (p.Tyr365\_Gln406del). The intronic deletion was confirmed by Sanger sequencing for all other affected individuals from whom DNA was available.

### DISCUSSION

The novel intronic deletion in *KRT5* described here led to a classical EBS-gen sev phenotype showing marked improvement with age in this 4-generation Dutch kindred. To our knowledge, there have been only 3 earlier reports of splice-site mutations in *KRT5*. Schuilenga-Hut et al. (7) described a patient with EBS generalized intermediate (formerly called EBS-Koebner) caused by a heterozygous acceptor splice site mutation, c.556-1G>C. The effect on RNA level was in-frame skipping of the first 6 amino acids encoded by exon 2 (18bp). The second splice site mutation also reported by our group was c.1474+4A>G in a patient with EBS localized (previously EBS, Weber-Cockayne) (1). The effect on RNA was not further investigated. Lastly, a heterozygous splice site mutation was identified in a large family exhibiting a similar clinical phenotype to the family reported here (8). In this report, abnormal in-frame splicing of exon 1 occurred by G to A transition in the consensus donor splice site of exon 1 (c.555+1G>A). This led to the use of an upstream cryptic splice site and subsequent deletion of 22 amino acids of the H1 and 1A rod domains. The reported patients displayed, as in our family, classic EBS-gen sev (8).

Skipping of exon 6 leads to the exclusion of 42 amino acids of the highly conserved 2B domain of *KRT5*. This heterozygous deletion is expected to act in a dominant-negative fashion affecting the keratin intermediate fila-

<sup>1</sup><https://doi.org/10.2340/00015555-2451>



**Fig. 1.** Family pedigree (a) and clinical pictures of affected family members (b–g) with ultrastructural view of affected skin (h) in epidermolysis bullosa simplex, generalized severe (EBS-gen sev). (b) Blistering of the palm at 6 years of age with surrounding subtle hyperkeratosis. Bullae of the fingers with visible desquamation. (c) The same patient at 11 years of age where amelioration of symptoms is seen. (d) Circinate blistering seen on the inner thigh. (e) Haemorrhagic blistering of the large toe, with focal hyperkeratosis and subtle onycholysis at 2 years of age. (f) Grouped haemorrhagic blisters on the lateral aspect of the foot of the same patient. (g) Generalized plantar keratoderma at 15 years of age. (h) Ultrastructure of affected skin shows a blister cavity (red asterisks) in the basal cell with the plasma membrane in the blister floor (red arrowheads) and lateral aggregation of tonofilaments (blue asterisks).

ment assembly, similar to keratin polypeptides affected by heterozygous missense mutations (9). Normally, a keratin 5 monomer will polymerize with a keratin 14 monomer by parallel assembly and winding of their rod domains into a coiled-coil structure. The stability of keratins is regulated by interactions between the 2 chains, which are held together by their hydrophobic residues (10–12). These residues are organized as heptad repeats, labelled “a” to “g” with the strongest hydrophobic interactions occurring at heptad positions “a” and “d”. A molecular defect, such as an amino acid substitution, alters the keratin inter-chain interactions to different degrees, depending on the polarity and position of the expressed residue (10, 11). The residues occupying the “a” position of the  $\alpha$ -helix are apolar amino acids, which stabilize the coiled coil of keratins. Residues located in the “g” position additionally contribute to the stability of the heterodimer by charged hydrophobic interactions. In the case of a heterozygous missense mutation, or in this case an internally truncated protein, the interchain assembly is distorted and the higher architecture of dimers and subsequent tetramers and filaments will be defective and prone to collapse (12). To date, 28 of the 121 reported mutations in *KRT5* have been located in exons encoding the 2B domain of *KRT5* (4). Of these, all but 2 published reports have been missense or nonsense mutations with the remaining being a deletion and an insertion deletion (13, 14).

With the presented case, we would like to draw attention to introns of EBS genes, including *KRT5*, as they can harbour mutations that lead to altered splicing, thereby affecting intermediate filament assembly in the basal epidermis.

## ACKNOWLEDGEMENTS

The authors would like to thank the patients for their participation in this study. JB and AMGP are sponsored by the Priority Medicines Rare Disease (E-RARE) grant SpliceEB from ZonMw. JB and AMGP are part of COST Action BM1207 ([www.exonskipping.eu](http://www.exonskipping.eu)).

## REFERENCES

- Bolling MC, Lemmink HH, Jansen GH, Jonkman MF. Mutations in *KRT5* and *KRT14* cause epidermolysis bullosa simplex in 75% of the patients. *Br J Dermatol* 2011; 164: 637–644.
- Fine JD, Bruckner-Tuderman L, Eady RA, Bauer EA, Bauer JW, Has C, et al. Inherited epidermolysis bullosa: updated recommendations on diagnosis and classification. *J Am Acad Dermatol* 2014; 70: 1103–1126.
- Murrell DF, Trisnowati N, Miyakis S, Paller AS. The yin and the yang of keratin amino acid substitutions and epidermolysis bullosa simplex. *J Invest Dermatol* 2011; 131: 1787–1790.
- Szeverenyi I, Cassidy AJ, Chung CW, Lee BT, Common JE, Ogg SC, et al. The Human Intermediate Filament Database: comprehensive information on a gene family involved in many human diseases. *Hum Mutat* 2008; 29: 351–360.
- Coulombe PA, Lee CH. Defining keratin protein function in skin epithelia: epidermolysis bullosa simplex and its aftermath. *J Invest Dermatol* 2012; 132: 763–775.
- Darwich E, Vicente A, Bolling MC, Gonzalez-Ensenat MA, Cusi V, Fortuny C, et al. Extensive acantholysis as the major histological feature of a severe case of Dowling Meara-epidermolysis bullosa simplex: a reappraisal of acantholysis in the newborn. *Eur J Dermatol* 2011; 21: 966–971.
- Schuilenga-Hut PH, Vlies P, Jonkman MF, Waanders E, Buys CH, Scheffer H. Mutation analysis of the entire keratin 5 and 14 genes in patients with epidermolysis bullosa simplex and identification of novel mutations. *Hum Mutat* 2003; 21: 447.
- Rugg EL, Rachet-Prehu MO, Rochat A, Barrandon Y, Goossens M, Lane EB, et al. Donor splice site mutation in keratin 5 causes in-frame removal of 22 amino acids of H1 and 1A rod domains in Dowling-Meara epidermolysis bullosa simplex. *Eur J Hum Genet* 1999; 7: 293–300.
- Shinkuma S, McMillan JR, Shimizu H. Ultrastructure and molecular pathogenesis of epidermolysis bullosa. *Clin Dermatol*

- 2011; 29: 412–419.
10. Wu KC, Bryan JT, Morasso MI, Jang SI, Lee JH, Yang JM, et al. Coiled-coil trigger motifs in the 1B and 2B rod domain segments are required for the stability of keratin intermediate filaments. *Mol Biol Cell* 2000; 11: 3539–3558.
  11. Banerjee S, Wu Q, Yu P, Qi M, Li C. In silico analysis of all point mutations on the 2B domain of K5/K14 causing epidermolysis bullosa simplex: a genotype-phenotype correlation. *Mol Biosyst* 2014; 10: 2567–2577.
  12. Lee CH, Kim MS, Chung BM, Leahy DJ, Coulombe PA. Structural basis for heteromeric assembly and perinuclear organization of keratin filaments. *Nat Struct Mol Biol* 2012; 19: 707–715.
  13. Kemp MW, Klingberg S, Lloyd L, Molloy TJ, Marr P, Wang Y, et al. A novel deletion mutation in keratin 5 causing the removal of 5 amino acids and elevated mutant mRNA levels in Dowling-Meara epidermolysis bullosa simplex. *J Invest Dermatol* 2005; 124: 1083–1085.
  14. Arin MJ, Grimberg G, Schumann H, De Almeida H, Jr, Chang YR, Tadini G, et al. Identification of novel and known KRT5 and KRT14 mutations in 53 patients with epidermolysis bullosa simplex: correlation between genotype and phenotype. *Br J Dermatol* 2010; 162: 1365–1369.